

## Addition of Nitrous Oxide to Fentanyl Anesthesia Does Not Induce Myocardial Ischemia in Patients with Ischemic Heart Disease

Michael K. Cahalan, M.D.,\* Omar Prakash, M.D.,† Evert N. R. Rulf, M.D.,† Marianne T. Cahalan, R.N.,‡ Anselmo P. G. Mayala, M.D.,‡ Frank C. Lurz, M.A.,‡ Peter Rosseel, M.D.,† Edmund Lachitjaran, M.D.,† King Siphanto, M.D.,† Elma J. Gussenhoven, M.D.,‡ Jos R. T. C. Roelandt, M.D.§

Although nitrous oxide is commonly administered to patients with ischemic heart disease, recent reports suggest that it may induce myocardial ischemia in these patients. The authors compared the effects of nitrous oxide on segmental left ventricular (LV) function and the ST segment of the electrocardiogram with the effects of an equal concentration of nitrogen (crossover design) before the start of surgery in 18 patients who required coronary-artery bypass grafting. The patients studied did not have valvular or LV dysfunction. Anesthesia was induced and maintained with intravenous fentanyl. After endotracheal intubation and 20 min of ventilation with 100% oxygen, either 60% nitrous oxide or 60% nitrogen (randomly assigned) was added to the inspired gas mixture of each patient for 10 min. This was followed by 10 min of 100% oxygen, and then 10 min of 60% nitrous oxide or 60% nitrogen, whichever had not been administered previously. Patients were monitored for myocardial ischemia using a standard 12-lead electrocardiogram and transesophageal two-dimensional echocardiography. Surgery did not begin until the study was concluded. No patient experienced an ST segment change > 1 mm during the study, and none developed a new segmental wall motion abnormality during inhalation of either nitrous oxide or nitrogen. The authors conclude that nitrous oxide does not induce myocardial ischemia when used as an adjunct to fentanyl anesthesia in patients who have severe coronary-artery disease accompanied by well-preserved valvular and LV function. (Key words: Anesthetics, gases: nitrous oxide. Anesthetics, intravenous: fentanyl. Heart: ischemia. Monitoring: electrocardiography; transesophageal echocardiography.)

BECAUSE NITROUS OXIDE produces minimal cardiovascular depression, anesthesiologists often administer this agent to patients with cardiac disease who must undergo surgery. However, recent reports suggest that nitrous oxide may induce myocardial ischemia in those who have ischemic heart disease. Using a canine model, Sill *et al.* demonstrated that 60% nitrous oxide con-

stricted the epicardial segment of the left anterior descending coronary artery without altering myocardial oxygen consumption.<sup>1</sup> Philbin *et al.* reported that the administration of nitrous oxide during fentanyl anesthesia in dogs induced marked segmental contraction abnormalities (presumed to indicate ischemia) in left ventricular (LV) segments served by a critically stenosed coronary artery.<sup>2</sup> Administration of halothane under similar conditions (less than 1 MAC of halothane and minimal depression of blood pressure) did not produce these marked changes.<sup>3</sup> Because nitrous oxide is a common adjunct to fentanyl anesthesia before and during coronary-artery surgery, we studied the effect of this agent on segmental left ventricular (LV) function and the ST segment of the electrocardiogram (ECG). We also compared the effects of nitrous oxide to those of an equal concentration of nitrogen.

### Materials and Methods

#### PATIENT SELECTION AND PREPARATION

With approval from our Committee on Human Research and informed consent from each patient, we studied 18 patients scheduled for elective coronary-artery surgery. Patients with valvular or global LV dysfunction (ejection fraction < 40%) or bundle branch block were excluded.

On the morning of surgery, all patients received their customary morning dose of cardiac medications and were premedicated with lorazepam (1.5–2.5 mg). Pulmonary-artery (*via* internal jugular vein) and aortic (*via* radial artery) catheters were inserted percutaneously after local anesthesia. The electrodes for the standard 12-lead ECG (Hewlett Packard, model 4750A) were attached to the limbs and precordium of the patient. Patients then rested for 10–15 min before we recorded hemodynamic traces (transducers calibrated with mercury) and the ECG (standard diagnostic mode calibrated at 1 mv/cm).

During administration of 100% oxygen, anesthesia was induced with 15 µg/kg of intravenous fentanyl, and paralysis was obtained with 0.1 mg/kg of pancuronium. Throughout the rest of the study, we administered a

\* Associate Professor of Anesthesia  
† Staff Anesthesiologist  
‡ Research Associate  
§ Professor of Cardiology

Received from the Department of Anesthesia, University of California, San Francisco, San Francisco, California; and Thoraxcentrum, Erasmus University, Rotterdam, The Netherlands. Accepted for publication July 14, 1987. Supported in part by the Anesthesia Research Foundation, NIH Program Project #2 PO1 AG03104-06 (Aging and Anesthesia), and the Interuniversity Cardiology Institute of the Netherlands.

Address reprint requests to Dr. Cahalan: Department of Anesthesia, C-450, University of California, San Francisco, San Francisco, California 94143.

TABLE 1. Summary of the Preoperative Clinical Data

	Mean	Range
Age (years)	57	37-68
Weight (kg)	78	55-101
Height (cm)	173	154-191
Ejection fraction	0.55	0.42-0.70
Diseased vessels	2.7	1-3
Beta adrenergic block	94%	
Ca <sup>++</sup> channel blocking drugs	72%	

constant infusion of  $0.2 \mu\text{g} \cdot \text{kg}^{-1} \cdot \text{min}^{-1}$  of fentanyl, and controlled ventilation at 10-12 breaths/min to maintain normocarbida. The dose of fentanyl was selected because, in the experience of the authors, it provides adequate anesthesia for an unstimulated, well-premedicated patient, and would not prevent prompt extubation after surgery. After endotracheal intubation, we positioned in the esophagus a two-dimensional echocardiographic transducer mounted on a 9-mm gastroscope to obtain a LV short-axis cross section at the level of the papillary muscles. This cross-sectional view was maintained throughout the study. The transducer was designed and built at the Thoraxcentrum, Erasmus University. It contained 52 piezoelectric elements and operated at 5 MHz attached to a Hewlett Packard ultrasonograph (model 77020AC).

#### STUDY PROCEDURES

Twenty minutes after endotracheal intubation, 60% nitrous oxide or 60% nitrogen (randomly assigned) was added for 10 min to the inspired oxygen of each patient. Then 100% oxygen was administered for 10 min, followed by 10 min of 60% nitrous oxide or 60% nitrogen, whichever had not been given previously. Thus, all patients received both nitrous oxide and nitrogen. Immediately before each change in the inspired gas mixture, arterial and mixed venous blood samples were drawn for gas and pH analysis; and hemodynamics, the 12-lead ECG, and echocardiogram were recorded. Surgery did not begin until the study was concluded.

#### DATA ANALYSIS

The data were analyzed by period: 1) immediately before induction, 2) 15 min after induction (100% oxygen), 3) 10 min after exposure to 60% nitrous oxide or 60% nitrogen, 4) 10 min after 100% oxygen, and 5) 10 min after the subsequent exposure to 60% nitrous oxide or 60% nitrogen. The initial ECG was compared to the patient's routine preoperative ECG. For these and all subsequent ECGs, we diagnosed myocardial ischemia if two observers independently found ST segment change of  $>1$  mm in any lead when compared to the ECG obtained in the immediately preceding period. For echocardiographic analysis, we diagnosed the onset of myo-

cardial ischemia if two observers independently noted that segmental LV systolic function deteriorated by more than one class when compared to segmental systolic LV function in the previous period. Classes were rated as 1 = normal, 2 = mild hypokinesis, 3 = severe hypokinesis, 4 = akinesis, and 5 = dyskinesis. This method of echocardiographic analysis has been previously described in detail.<sup>4</sup> In brief, we modified the method of Van Reet *et al.*<sup>5</sup> to analyze segmental LV systolic function. Guided by the papillary muscles, we divided the cross-sectional image into four segments. We considered segment contraction normal when the segment's imaginary radius to LV center shortened by more than 30% and the segment wall thickened considerably. All other segmental wall motion was classified as one of the following: 1) mild hypokinesis, in which the segment's imaginary radius shortened by 10-30% and wall thickening was slightly reduced; 2) marked hypokinesis, in which the radius shortened by less than 10% and wall thickening was minimal; 3) akinesis, defined as no change in radius or wall thickness; and 4) dyskinesis, in which outward movement and thinning of the segment occurred during systole. Endocardial motion and myocardial thickening were estimated visually, providing a qualitative analysis of segmental LV systolic function. Motion of the endocardium and epicardium due to translation or rotation of the heart was discounted in this analysis (floating reference system). Our observers interpreted the ECG tracings and echocardiograms independently and without knowledge of the patient's identity or clinical course. ECGs and echocardiograms also were read at separate times, so that the results of one technique could not influence the interpretation of the other. Hemodynamics were evaluated by repeated measures analysis of variance and multiple *t* tests. A *P* value  $<0.05$  was considered statistically significant, except when adjusted by the Bonferroni correction.

#### Results

Patient preoperative data are listed in table 1. The order of administration of nitrous oxide or nitrogen had no effect on the change in hemodynamics induced by these agents. The responsible anesthesiologist determined the anesthetic depth appropriate for each patient by the absence of tearing and presence of stable hemodynamics. No patient required additional anesthetics during the study to insure this adequate level, and no patient experienced recall of the events of the study after induction.

#### DATA EXCLUSION

In total, 1296 ST segments (18 patients with 12 leads at the five study intervals and the preoperative tracings) were projected for analysis. We were unable to obtain

the routine preoperative ECGs of two patients; however, neither had ST changes on his/her ECG prior to induction of anesthesia. One or both observers could not interpret a total of 28 other ST segments from the tracings of three patients because of variability in the isoelectric baseline or 60-cycle interference. Thus, 96% of the ST segment data (1244 of 1296) was analyzed.

Echocardiograms of 288 LV segments (18 patients, four left ventricular segments, at four intervals) were projected for analysis. In one patient, we were unable to obtain an adequate echocardiographic cross-section of the LV. In another, the videotape recorder was not activated for the first echocardiogram (period 2); however, all subsequent echocardiograms were recorded in this patient, and segmental LV systolic function was always normal. In five patients, at least one segment of the left ventricle at one interval could not be analyzed by one or both observers. In total, 89% (256 of 288) of the echocardiographic analyses was completed by both observers. No single ECG lead or echocardiographic segment was excluded from analysis with any greater frequency than any other lead or segment.

HEMODYNAMICS

Hemodynamic values before and after induction of anesthesia (fentanyl/pancuronium) are listed in table 2: mean arterial pressure, mean pulmonary arterial pressure, pulmonary capillary wedge pressure, cardiac index, stroke volume index, and right and left ventricular stroke work indexes decreased. The mean values of subsequent changes after administration of 60% nitrogen or nitrous oxide are shown in figure 1A and B. The hemodynamic changes which occurred were modest, and did not require intervention with additional anesthetics, or vasoactive or inotropic drugs. Administration of nitrous oxide, but not nitrogen, decreased heart rate significantly; approximately 8 beats/min. Typically, this change in heart rate occurred within 3-5 min of administering nitrous oxide, and all hemodynamic variables had stabilized by the time (10 min) data were recorded. No significant change in arterial pH or base

TABLE 2. Hemodynamics (1 SD) Before and After Induction of Anesthesia

	Period 1 (Awake)	Period 2 (Fentanyl/pancuronium)
Heart rate (b/min)	65 ± 10	68 ± 11
Mean arterial pressure (mmHg)	98 ± 11	88 ± 13*
Mean pulmonary arterial pressure (mmHg)	16 ± 4	11 ± 3*
Pulmonary artery wedge pressure (mmHg)	10 ± 3	5 ± 3*
Central venous pressure (mmHg)	5 ± 2	4 ± 2
Cardiac index (1 · mm <sup>-1</sup> · m <sup>-2</sup> )	2.8 ± 0.6	2.5 ± 0.8*
Stroke volume index (ml/m <sup>2</sup> )	45 ± 7	36 ± 8*
Systemic vascular resistance (dyn · sec · cm <sup>-5</sup> )	92 ± 52	113 ± 44
Pulmonary vascular resistance (dyn · sec · cm <sup>-5</sup> )	1453 ± 385	1546 ± 505
Left ventricular stroke work index (g · m · m <sup>-2</sup> )	54 ± 10	41 ± 11*
Right ventricular stroke work index (g · m · m <sup>-2</sup> )	6 ± 3	4 ± 2*

\* Indicates P < 0.01.

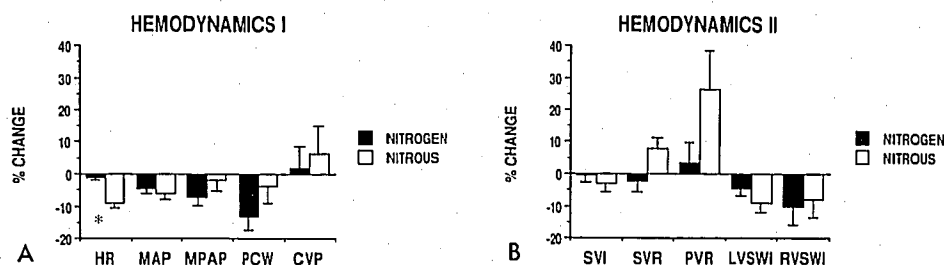
excess occurred during the study, and neither nitrogen nor nitrous oxide administration ever produced a PaO<sub>2</sub> of less than 100 mmHg or PvO<sub>2</sub> of less than 30 mmHg.

MYOCARDIAL ISCHEMIA

No patient complained of angina while in the operating room before induction of anesthesia. In one patient, the routine preoperative and preinduction ECG tracings were different: in V<sub>3</sub>, a 2.5-mm horizontal depression of the ST segment in the preoperative recording became a 3.5-mm up-sloping elevation in the pre-induction recording. All subsequent ECG recordings indicated no change in ST segment > 1 mm in any patient.

The initial echocardiogram of three patients revealed at least one LV segment with marked hypokinesis or worse wall motion. The Q waves on the preoperative ECGs of these patients appeared in a distribution corresponding to the wall motion abnormality, suggesting that ischemia during induction of anesthesia was not the

FIG. 1. A, B. The percent change and standard error (compared to the immediately preceding period of 100% oxygen) in hemodynamic variables during 60% nitrogen or nitrous oxide administration is shown. \*P < 0.01, statistically significant between groups. HR = heart rate; MAP = mean arterial pressure; MPAP = mean pulmonary artery pressure; PCW = pulmonary artery wedge pressure; CVP = central venous pressure; SVI = stroke volume index; SVR = systemic vascular resistance; PVR = pulmonary vascular resistance; LVSWI = left ventricular stroke work index; and RVSWI = right ventricular stroke work index.



etiology. Thereafter, segmental wall motion changed by more than one class in only one patient: a portion of the inferior and septal walls which was mildly hypokinetic during 60% nitrogen administration became dyskinetic during the subsequent period of 100% oxygen, and remained dyskinetic throughout the final period of 60% nitrous oxide administration. Neither observer detected deterioration in segmental wall motion of more than one class in any other patient. One or both observers detected nondiagnostic changes (change by one class) in 14 patients: at least one observer saw at least one LV segment worsen in five patients during nitrous-oxide administration, and in seven patients during nitrogen administration; conversely, at least one observer saw at least one segment improve in five patients during nitrous-oxide administration and six patients during nitrogen administration.

### Discussion

Using 12-lead electrocardiography and transesophageal two-dimensional echocardiography, we did not detect the onset of myocardial ischemia during administration of nitrous oxide in 18 consecutive patients having severe coronary-artery disease. These monitoring techniques are more sensitive detectors of ischemia than those used routinely in clinical practice; specifically, the echocardiogram is one of the most sensitive methods for detection of ischemia in animals and humans. Within seconds of the onset of ischemia, the affected area of myocardium visibly ceases to contract (thicken and move inward) normally.<sup>6-13</sup> In previous echocardiographic studies of patients with ischemic heart disease, we were able to demonstrate a 15-48% incidence of new segmental wall motion abnormalities during cardiovascular surgery.<sup>4,14,15</sup> Sensitivity and specificity of echocardiography are superior to those of electrocardiography.<sup>4,16</sup>

Our findings differ from those of Philbin *et al.*, who reported that nitrous-oxide administration produced segmental wall motion abnormalities in dogs. Several explanations for this difference may apply. First, our patients, unlike their animal subjects, were chronically medicated with beta-adrenergic blocking and/or calcium-channel blocking agents and nitrates. Second, the human and canine coronary response to nitrous oxide may be different. Third, our patients, unlike their animal counterparts, had not experienced acute thoracotomies and manipulations of the coronary arteries. Fourth, we used a qualitative method for evaluation of segmental LV motion, and Philbin *et al.* used a quantitative method. This last difference requires closer examination.

Using microcrystals embedded in the canine myocardium, Philbin *et al.* detected changes in LV dimensions and onset of contraction with greater precision than we

did in humans using transesophageal echocardiography. However, the most striking abnormality induced by nitrous oxide in the canine experiments was a marked increase in postsystolic contraction in the area of myocardium served by the critically stenosed coronary artery. Using our qualitative system, detection of marked contraction delays is not difficult, because the nonaffected, juxtaposed LV segments serve as controls, in contrast to which the affected segment appears to wobble.<sup>4</sup> We saw no such changes in our patients. In a study comparable to ours, Slavik *et al.* administered 70% nitrous oxide during sufentanil anesthesia in seven patients about to undergo coronary-artery bypass grafting and monitored segmental LV function with two-dimensional transesophageal echocardiography.<sup>17</sup> Their methods differed in that they evaluated their echocardiograms with a semiautomated computer system which mapped segmental LV function throughout systole and diastole. However, their results agree with ours; they found no change in segmental LV function.

Nevertheless, the issue of the safe use of nitrous oxide in patients who have ischemic heart disease is not resolved. We have investigated its use in the absence of surgical stress, and only in patients with normal LV function. Neither we nor Slavik and his coworkers have compared the relative safety of alternative anesthetic adjuvants. Nor have Philbin *et al.* provided us any insights regarding the mechanisms governing the reported effect of nitrous oxide on segmental wall motion.

The authors gratefully acknowledge the assistance of nurse anesthetists: P. v.d. Schelde, J. Koopmans, A. J. Koedood, D. Thompson, E. Ramou, and R. Hoogewaard who assisted in the care and preparation of patients during the study. They also gratefully acknowledge the advice and cooperation of Egburt Bos, Professor of Cardiac Surgery, and the Thorax Center staff surgeons including B. P. Mochtar, L. A. van Herwerden, M. M. P. Haalebos, F. Leicher and G. J. Kootstra. T. v.d. Vlies and A. van Dalen provided invaluable service for data documentation, and Ron van Domberg for data processing. The authors are indebted to W. Vletter and J. McGhie for assistance with echocardiographic equipment and image processing, Celeste Mangold for manuscript preparation, and E. I. Eger II, M.D. and Winifred von Ehrenburg for editorial assistance. Finally, the authors acknowledge the contribution of the engineers and technicians at the Thorax Center who developed and provided the transesophageal echocardiographic transducers: N. Bom, C. M. Ligtvoet, N. de Jong, Jan Han-kopf, and C. T. Lancee.

### References

1. Sill JC, Wilkowski DAW, Bove AA, Owen R, Bonta W: Nitrous oxide constricts epicardial coronary arteries in intact dogs (abstract). *ANESTHESIOLOGY* 65:A513, 1986
2. Philbin DM, Föex P, Drummond G, Lowenstein E, Ryder WA, Jones LA: Postsystolic shortening of canine left ventricle supplied by a stenotic coronary artery when nitrous oxide is added in the presence of narcotics. *ANESTHESIOLOGY* 62:166-174, 1985
3. Lowenstein E, Föex P, Francis CM, Davies WL, Yusuf S, Ryder

- WA: Regional ischemic ventricular dysfunction in myocardium supplied by a narrowed coronary artery with increasing halothane concentration in the dog. *ANESTHESIOLOGY* 55:349-359, 1981
- Smith JS, Cahalan MK, Benefiel DJ, Byrd B, Lurz FW, Shapiro W, Roizen MF, Bouchard A, Schiller NB: Intraoperative detection of myocardial ischemia in high risk patients: Electrocardiography versus two-dimensional transesophageal echocardiography. *Circulation* 72:1015-1021, 1985
  - Van Reet RE, Quinones MA, Poliner LR, Nelson JG, Waggoner AD, Kannon D, Lubetkin SJ, Pratt CM, Winters WL Jr: Comparison of two-dimensional echocardiography with gated nucleotide ventriculography in the evaluation of global and regional left ventricular function in acute myocardial infarction. *J Am Coll Cardiol* 3:243-252, 1984
  - Visser CA, David GK, Kan C, Romijn KH, Meltzer RS, Koolen JJ, Dunning AJ: Two-dimensional echocardiography during percutaneous transluminal coronary angioplasty. *Am Heart J* 111:1035-1041, 1986
  - Pandian NG, Kerber RE: Two-dimensional echocardiography in experimental coronary stenosis. I. Sensitivity and specificity in detecting transient myocardial dyskinesia: comparison with sonomicrometers. *Circulation* 66:597-602, 1982
  - Heger JJ, Weyman AE, Wann LS, Dillon JC, Feigenbaum H: Cross-sectional echocardiography in acute myocardial infarction: Detection and localization of regional left ventricular asynergy. *Circulation* 60:531-538, 1979
  - Kisslo JA, Robertson D, Gilbert BW, Von Ramm O, Behar VS: A comparison of real-time, two-dimensional echocardiography and cineangiography in detecting left ventricular asynergy. *Circulation* 55:134-141, 1977
  - Weiss JL, Bulkley BH, Hutchins GM, Mason SJ: Two-dimensional echocardiographic recognition of myocardial injury in man: Comparison with postmortem studies. *Circulation* 63:401-408, 1981
  - Lieberman AN, Weiss JL, Jugdutt BI, Becker LC, Bulkley BH, Garrison JG, Hutchins GM, Kallman CA, Weisfeldt ML: Two-dimensional echocardiography and infarct size: Relationship of regional wall motion and thickening to the extent of myocardial infarction in the dog. *Circulation* 63:739-746, 1981
  - Wann LS, Faris JV, Childress RH, Dillon JC, Weyman AE, Feigenbaum H: Exercise cross-sectional echocardiography in ischemic heart disease. *Circulation* 60:1300-1308, 1979
  - Gibson RS, Bishop HL, Stamm RB, Crampton RS, Beller GA, Martin RP: Value of early two dimensional echocardiography in patients with acute myocardial infarction. *Am J Cardiol* 49:1110-1119, 1982
  - Smith JS, Cahalan MK, Benefiel DJ, Lurz FW, Lampe GH, Byrd BJ, Schiller NB, Yee ES, Turley K, Ulyot DJ, Hamilton WK: Fentanyl versus fentanyl- and isoflurane in patients with impaired left ventricular function (abstract). *ANESTHESIOLOGY* 63:A18, 1985
  - Smith JS, Benefiel DJ, Beaupre PN, Sohn YJ, Lurz FW, Byrd B, Bouchard A, Schiller NB, Cahalan MK, Roizen MF: Effect of phenylephrine on myocardial performance during carotid endarterectomy (abstract). *ANESTHESIOLOGY* 61:A56, 1984
  - Wohlgeleitner D, Cleman M, Highman HA, Fetterman RC, Duncan JS, Zaret BL, Jaffe CC: Regional myocardial dysfunction during coronary angioplasty: Evaluation by two-dimensional echocardiography and 12 lead electrocardiography. *J Am Coll Cardiol* 7:1245-1254, 1986
  - Slavik JR, LaMantia KR, Kopriva CJ, Prokop EK, Ezekowitz MD, Barash PG: Does N<sub>2</sub>O cause regional wall motion abnormalities in patients with CAD? An evaluation by 2D transesophageal echocardiography (abstract). *ANESTHESIOLOGY* 65:A515, 1986