

Anesthesiology
67:979-981, 1987

Malignant Hyperthermia in a Renal Transplant Recipient

DAVID J. BYERS, M.D.,* ROBERT G. MERIN, M.D.†

The living related renal transplant operation represents a special set of circumstances. Only under these conditions does an individual (the donor) undergo major surgery without benefit to him(her)self. Consequently, not only is the anesthetic a "premium" one, but the donor kidney is a very precious commodity. The incidence of malignant hyperthermia and the increasing numbers of living related renal transplants that have been done over the years should suggest that the two may co-occur. This is the first reported case of malignant hyperthermia in a living related renal transplant recipient. The approaches utilized to preserve the kidney are described.

CASE REPORT

A 33-yr-old female was scheduled for living related renal transplant. Her past medical history was significant for insulin-dependent diabetes mellitus since age 15 yr complicated by retinopathy, peripheral neuropathy, hypertension, and progressively deteriorating renal function. Because of her retinopathy and the inevitability of her renal failure, dialysis was not initiated, but, rather, she was evaluated early for renal transplantation. Her most recent insulin dosage was 20 units of NPH and 10 units of regular each morning. She had discontinued her anti-hypertensive medications (hydralazine, methyl dopa, and nadolol) 2 months previously because of the side effects, mainly of lethargy. Her past surgical history included a subtotal thyroidectomy (for goiter) in 1971, two uterine dilatations and curettages in 1978 and 1979, and a cesarean section in 1984, all under general anesthesia without apparent complications. Her family history was negative for anesthetic-related problems.

On admission 5 days prior to surgery, arterial blood pressure was 180/90 mmHg, and nifedipine 10 mg q 6 h orally was initiated. At the same time, she was also started on our usual pretransplant regimen of cyclosporin A 60 mg iv q 6 h. Likewise, 2 days prior to surgery, she was given prednisone 60 mg PO each morning. In response to the corticosteroid, her serum glucose, which had been in the 200 mg · dl⁻¹ range, increased to 500-600 mg · dl⁻¹, necessitating frequent doses of regular insulin and, finally, an insulin infusion on the night prior to surgery. Hemodialysis was instituted for the first time 48 h and, again, 24 h

prior to surgery in an attempt to correct fluid and electrolyte imbalances. Despite this, her serum potassium remained high, and she was given polystyrene sulfonate 150 gm by mouth on the night prior to surgery.

On physical examination the evening before surgery, arterial blood pressure was 150/90 mmHg, heart rate 80 bpm, respirations 20 breaths/min, and temperature 36.6° C orally. She weighed 70 kg. Her chest was clear to percussion and auscultation, and her cardiac examination was normal. At that time, her serum glucose was 516 mg · dl⁻¹, potassium 6.0 mEq · l⁻¹, hemoglobin 8.2 gm · dl⁻¹, pHa 7.31, PaCO₂ 39 mmHg, PaO₂ 96 mmHg, and base excess -5 mEq/l. Thyroid function tests were normal. Her chest radiograph was within normal limits, and the electrocardiogram showed a sinus rhythm with T-wave inversions in the inferior and lateral leads.

On the morning of surgery, at 0400, the serum glucose was 384 mg · dl⁻¹ and potassium 5.7 mEq · l⁻¹. At 0500, 15 units regular insulin was added to her iv infusion of 3 units per hour. At 0600, her serum glucose had decreased to 94 mg · dl⁻¹ and potassium to 5.2 mEq/l, and her insulin infusion was discontinued. At 0600 hours, the patient was premedicated with diazepam 10 mg by mouth. At the same time, her morning dose of nifedipine was given and methylprednisolone was administered in a dose of 500 mg iv. The usual monitoring for renal transplants in our institution included electrocardiogram, automated arterial blood pressure, precordial stethoscope, and mass spectrometer monitoring of respiratory and anesthetic gases. In addition, a nerve stimulator was used on the left ulnar nerve to monitor neuromuscular blockade. Anesthetic induction proceeded with thiopental 250 mg in divided doses and vecuronium 7 mg iv. Positive pressure ventilation with halothane (1-2%) and 100% oxygen preceded laryngoscopy and tracheal intubation. In addition, 80 mg of lidocaine was given iv 1 min prior to tracheal intubation. Subsequently, an esophageal stethoscope with a temperature probe was inserted and a right internal jugular catheter was placed. Anesthesia was maintained with nitrous oxide 60%, oxygen 40%, and halothane as needed (1-1.5%). A heated water blanket, aluminum foil wrap, and a moisture trap in the anesthetic circuit were used to attempt to maintain body temperature. As shown in figure 1, the first 3 h of anesthesia were uneventful. During this time, her serum glucose rose from 94 to 317 mg · dl⁻¹ and potassium from 5.2 to 5.6 mEq · l⁻¹. Her insulin infusion was re-started at 2 units/h, and later increased to 4 units per hour to maintain glucose homeostasis. During the fourth hour, the end-tidal carbon dioxide tension increased to 40 mmHg, and a central venous blood gas revealed slightly increased P_{CO₂}, normal P_{O₂}, and a slight metabolic acidosis (fig. 1). The ventilator setting was increased from 5.6 to 8.4 l/min. In spite of this, a repeat venous blood gas 10 min later showed a P_{CO₂} of 56 mmHg. Heart rate and arterial blood pressure were unchanged, and, clinically, the patient appeared well with no evidence of hypoperfusion or hypoventilation. The carbon dioxide absorber was functioning, as there was no inspired carbon dioxide as measured by the mass spectrometer. The ventilator setting was again further increased to 10 l/min. During the next hour, there was a very slow increase in body temperature, 37 to 38° C, with no change in heart

* Resident.

† Professor.

Received from the Department of Anesthesiology, University of Texas Medical School Houston, 6431 Fannin Street, Room 5.020, Houston, Texas 77030. Accepted for publication May 5, 1987.

Address reprint requests to Dr. Merin.

Key words: Hyperthermia; malignant. Kidney; transplantation.

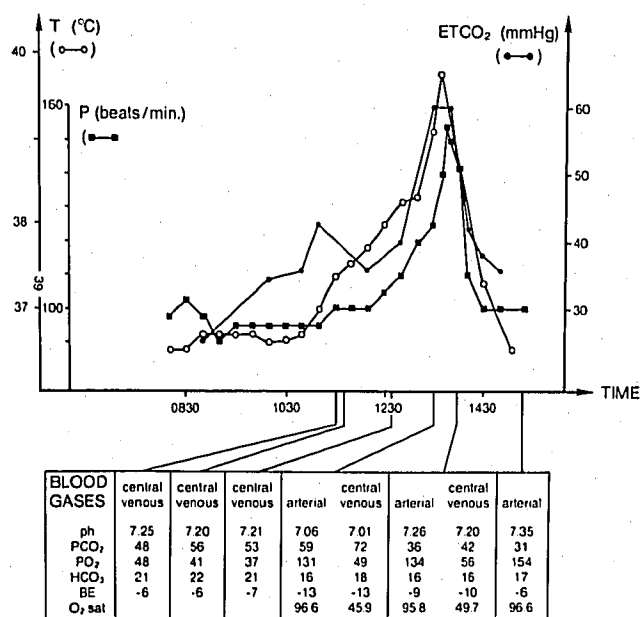


FIG. 1. Chronologic graph of esophageal temperature (T), heart rate (P), and end-tidal CO₂ (ET CO₂) with intermittent analysis of arterial blood gases.

rate or arterial blood pressure. The warming blanket and the aluminum foil wrap were discontinued. A third central venous blood gas obtained 4 h after anesthetic induction showed a decrease in P_{CO₂} to 52 mmHg. Consequently, a diagnosis of sepsis was entertained and preparations were made for blood cultures when, over a 15-min period, body temperature and heart rate increased from 38° C and 100 bpm to 39.1° C and 120 bpm, respectively, along with an increase in end-tidal carbon dioxide to approximately 60 mmHg (fig. 1). At this time, the clinical diagnosis of malignant hyperthermia was made. The halothane was discontinued, and ventilation controlled with 45% oxygen and 55% nitrous oxide. A radial artery catheter was inserted and paired arterial and venous blood gases revealed a severe mixed respiratory and metabolic acidosis with well-maintained oxygenation (fig. 1). Dantrolene and a specially prepared halothane-free anesthetic machine were obtained in approximately 5 min. At the time of machine change and the administration of 2.4 mg/kg⁻¹ of dantrolene iv, temperature and heart rate were 39.8° C and 158 bpm, respectively. An immediate response in vital signs was observed and, within 20 min of the dantrolene administration, the temperature and heart rate had dropped to 38.9° C and 112 bpm, respectively. Repeat arterial and venous blood gases showed a significant improvement in both the respiratory and metabolic components of the acidosis (fig. 1). At this point, the surgeons had begun the venous anastomosis of the donor kidney, but were still 1½–2 h away from completion of the surgery. Inasmuch as the patient was responding well to treatment, and in view of the circumstances outlined in the introduction, the decision was made to complete the surgery. Fentanyl 300 µg and morphine 10 mg were administered iv, and anesthesia was continued with nitrous oxide 70%, oxygen 30%. The remainder of the anesthetic was uneventful. It is of interest that the donor (the patient's brother) had a relatively uneventful anesthetic (isoflurane-vecuronium) and operative course in the adjoining room, except for some difficulty in harvesting his kidney, which accounted for the length of the surgery.

At the completion of the transplantation procedure, the peripheral nerve stimulation indicated a full train-of-four but fade on tetanic stimulation at 50 Hz. Total vecuronium dose had been 17 mg iv. In any event, controlled ventilation in the recovery room initially was

planned considering the physiologic trespass that had occurred. By 2 h postoperatively, neuromuscular function was normal according to the peripheral nerve stimulator, but the patient still complained of weakness and was unable to sustain a head lift. Since a second dose of dantrolene was planned for that evening, controlled ventilation was continued overnight. The initial serum potassium in the recovery room was 9.5 mEq · l⁻¹, but there was no evidence of hyperkalemia on the electrocardiogram. A repeat measurement was reported at 6.5 mEq · l⁻¹. Otherwise, recovery was uneventful, and the trachea was extubated the following morning. Serum creatine phosphokinase peaked 24 h after surgery at 683 units and urine myoglobin was negative. The transplant functioned well and the patient was discharged 1 week postoperatively. After prolonged family discussion and counseling, the patient and the family preferred to be considered malignant hyperthermia susceptible rather than undergo muscle biopsies for definitive diagnosis.

DISCUSSION

In addition to discontinuing the supposed trigger (volatile potent anesthetic), treating the symptoms (e.g., cooling), and the presumed pathology (i.e., dantrolene), optimal management of a case of malignant hyperthermia includes terminating the surgery.¹ In this case, however, more than the patient was involved. Her brother was in the process of undergoing a major surgical procedure and his donor kidney was already harvested and partially implanted. The decision had to be made as to whether to sacrifice his donation and the kidney or to continue with the surgery. In view of the patient's dramatic response to therapy, surgery was continued in spite of the fact that the duration was known to be in the range of 2 h. It has been reasonably well established that malignant hyperthermia susceptible patients can be safely anesthetized with the combination of dantrolene prophylaxis and non-triggering anesthetics.^{1,2} Consequently, we felt justified in our decision. However, had the patient not been responding well to the treatment, certainly sacrifice of the kidney would be preferable to jeopardizing the patient's life.

In addition, our patient presented some complicating factors which might make the syndrome of malignant hyperthermia more severe. Despite the fact that the patient had been dialyzed twice in the 48 h prior to surgery, there was some difficulty with her potassium homeostasis. Although her serum potassium at the onset of surgery was within normal limits, certainly it is conceivable that her total body potassium was somewhat increased. One of the major factors in morbidity, and, perhaps, mortality, from malignant hyperthermia has been felt to be hyperkalemia.¹ Although there may have been one very high serum potassium in the recovery room, in fact, this was most likely either a collection or a laboratory error, for a repeat value, although high, was not within dangerous limits. An insulin-dependent diabetic, particularly one whose control was difficult, could be expected to be more susceptible to metabolic acidosis. Although our patient had a mild metabolic

acidosis in the initial stages of the surgery and anesthesia, in fact, her response to malignant hyperthermia was not unusual. This patient's newly transplanted kidney probably played an important role in reversing her acid-base and electrolyte abnormalities, which were pre-existent, but worsened by MH. Had the kidney not functioned, her postoperative course would have been much more complicated.

The lack of muscle rigidity, the slow onset of the disease, and the low serum CPK values in the perioperative period all support the classification of this case as "nonrigid" malignant hyperthermia.[‡] The reasons for the difference between rigid and nonrigid malignant hyperthermia are unclear, but, in our case, the following factors should be considered. In the first place, the trigger was only halothane, not succinylcholine. The clinical course of halogenated anesthetic triggered malignant hyperthermia is more likely to be nonrigid and delayed than that triggered by succinylcholine.^{1,‡} In addition, the patient was given two drugs which have been shown to delay the onset of malignant hyperthermia in susceptible swine, thiopental and a non-depolarizing neuromuscular blocking drug.³ Finally, the patient was taking a calcium channel blocking drug, nifedipine. Although it has been suggested that the calcium channel blocking drugs might be used in the therapy of malignant hyperthermia,⁴ in fact, the presumed pathophysiology of the disease argues against this. Calcium channel blockers affect calcium influx through the muscle cell membrane and do not have primary effects on the internal calcium controlling membrane, the sarcoplasmic reticulum. On the other hand, most evidence points to a disorder of the sarcoplasmic reticulum as being responsible for the disease.¹ In addition, there have been reports of interaction between the definite therapy drug for the disease, dantrolene, and calcium channel blockers,⁵⁻⁸ although the cardioactive calcium blockers, verapamil and diltiazem, appear to be more deleterious in this regard.^{9,10} In spite of a reasonably high dose of nifedipine, malignant hyperthermia still developed in this patient. This lends more support to the contention that calcium channel blockers have no place in the treatment of malignant hyperthermia.

Also of note was that ventilation had to be controlled overnight because of her muscle weakness. Certainly, the combination of a calcium channel blocker and a neuromuscular blocking drug might account for the persistence of muscle weakness.¹¹ In addition, dantrolene might also have contributed. On the other hand, weakness has been reported both pre- and postoperatively in patients without all these complicating factors. In any event, it is interesting that the most distressing part of the whole procedure for this patient was hav-

ing to be ventilated throughout the first 24 h of her recovery.

Finally, in reviewing her most recent anesthetic record from an adjacent institution, we discovered that she had received succinylcholine and halothane during a cesarean section (1984), but had benign intra- and postoperative courses. This is further evidence that prior exposure to triggering agents may not identify the patient who is MH susceptible.¹ In summary, the management of malignant hyperthermia is more complicated in a patient with end-stage renal disease for a living related renal transplant. The development of the syndrome may be delayed because of hesitancy to use succinylcholine in these patients, and the metabolic disturbances may be more severe because of pre-existing electrolyte and acid-base abnormalities. The use of dantrolene may be hazardous if the patient has been taking calcium channel blockers and, finally, the issue of whether or not to proceed with surgery should be based on the patient's response to treatment and the cost of prematurely terminating the procedure. We report the successful management of malignant hyperthermia in a patient with the combination of insulin-dependent diabetes, hypertension treated with a calcium channel blocker, nifedipine, with end-stage renal disease for living related renal transplantation.

REFERENCES

1. Gronert GA: Malignant hyperthermia. *ANESTHESIOLOGY* 53:395-423, 1980
2. Flewellen EH, Nelson TE, Jones WP, Arens JF, Wagner DL: Dantrolene dose response in awake man: Implications for management of malignant hyperthermia. *ANESTHESIOLOGY* 59:275-280, 1983
3. Gronert GA, Wilde JH: Variations in the onset of porcine malignant hyperthermia. *Anesth Analg* 60:499-503, 1981
4. Iwatsuki N, Koga Y, Amaha K: Calcium channel blocker for the treatment of malignant hyperthermia. *Anesth Analg* 62:861-862, 1983
5. Saltzman LS, Kates RA, Corke BC, Norfleet EA, Heath KR: Hyperkalemia and cardiovascular collapse after dantrolene and verapamil administration in swine. *Anesth Analg* 63:473-478, 1984
6. McGrath CJ, Lee JC, Rempel WE: Noneffectiveness of verapamil in preventing halothane-induced malignant hyperthermia in susceptible swine. *Am J Vet Res* 45:935-937, 1984
7. Gallant EM, Folds FF, Rempel WE, Gronert GA: Verapamil is not a therapeutic adjunct to dantrolene in porcine malignant hyperthermia. *Anesth Analg* 64:601-606, 1985
8. Lynch C, Durbin CG, Fisher NA, Veselis RA, Althaus JS: Effects of dantrolene and verapamil on atrioventricular conduction and cardiovascular performance in dogs. *Anesth Analg* 65:252-258, 1986
9. Saltzman LS, Kates RA, Norfleet EA, Corke BC, Heath KR: Hemodynamic interactions of diltiazem-dantrolene and nifedipine-dantrolene. *ANESTHESIOLOGY* 61:A11, 1984
10. Rubin AS, Zablocki AD: Hyperkalemia, verapamil, and dantrolene. *ANESTHESIOLOGY* 66:246-249, 1987
11. Durant NN, Nguyen N, Katz RL: Potentiation of neuromuscular blockade by verapamil. *ANESTHESIOLOGY* 53:395-423, 1984

[‡] Personal communication, Dr. Henry Rosenberg.