

Sacral Intervertebral Epidural Block

PAOLO BUSONI, M.D.,* ARMANDO SARTI, M.D.†

Caudal blockade is used in children because the technique is simple and the spread of local anesthetic is reasonably predictable.¹ However, on rare occasions, a caudal blockade fails due to difficulties in identifying the sacral hiatus.² In children, an alternative approach could be *via* the sacral vertebral interspaces. Yet, sacral intervertebral epidural blockade involving the introduction of a needle through the sacral interspaces has not been described. We, therefore, described the anatomical and developmental factors which made such a technique possible in 74 children.

MATERIALS AND METHODS

Seventy-four ASA I or II children, aged 2 months–13 yr, undergoing surgery were studied (table 1). The following operations were carried out: inguinal herniorrhaphy or hydrocoelectomy (35), undescended testis (17), plastic operations on penis and urethra (12), orthopedic operations on lower extremities (5), and ureteric reimplantations (5). The protocol was approved by our hospital Ethical Committee, and informed written consent was obtained from parents of all patients. Children under 1 yr of age were not premedicated. The remainder received diazepam orally $0.2 \text{ mg} \cdot \text{kg}^{-1}$ 1 h before surgery. General anesthesia was induced with nitrous oxide and halothane, after which an intravenous line was established. The children were placed in the lateral position with the legs flexed, and a line was drawn between the posterior superior iliac spines. This line crossed the second sacral vertebral arch, the midpoint of which was marked. The large space between the second and third arches was identified by palpation, 0.5–1 cm caudad to this point (fig. 1).

After thorough skin preparation, the skin over the interspace was punctured with a large-bore needle to

prevent a dermal plug being carried into the epidural space on subsequent insertion of the epidural needle. For single injection procedures, a 19-G, 80-mm epidural needle with a Crawford bevel was inserted perpendicular to the skin. A syringe containing air or normal saline attached to the hub was used to identify the epidural space by loss of resistance.³

Anesthesia beyond 1.5 h was required in 26 patients in whom an 18-G, 80-mm epidural Tuohy beveled cannula was used, and a catheter ($0.4 \times 0.85 \times 1000 \text{ mm}$)‡ inserted.

When the epidural space was entered, an aspiration test was performed. If no blood or cerebrospinal fluid was obtained, a test dose ranging between 0.5–2 ml 1% mepivacaine with epinephrine 1:200,000 was given, and breathing, heart rate, and arterial blood pressure monitored. After 3 min, 1% plain mepivacaine was injected at the rate of $0.7 \text{ ml} \cdot \text{sec}^{-1}$ in a dose based on the weight and the type of surgery to be performed. This dosage regimen has been described by Armitage⁴ for caudal analgesia and modified by us (*i.e.*, $0.5 \text{ ml} \cdot \text{kg}^{-1}$ for sacral block; $0.75 \text{ ml} \cdot \text{kg}^{-1}$ to block lower thoracic).⁵ The distance to which the needle had been inserted was noted, and this was assumed to be the distance between the skin and the epidural space.

Each child was then placed in the supine position, and the level of analgesia was measured by pinching the skin between the finger-nails while observing the child's autonomic reaction to painful stimulation.⁶

General anesthesia was discontinued, and additional diazepam administered iv to keep the child calm and quiet during surgery. All the children were followed up for 24 h by the same anesthesiologist.

RESULTS

In all cases, the S2-S3 interspace was easily identified and the sacral intervertebral approach resulted in a successful block, since the attempted level of analgesia matched the actual level of analgesia and all the operations were carried out without any further supplementation of analgesic or general anesthetic drugs. In 11 cases, previous attempts at a caudal block had failed as the sacral cornua were not identified due to anatomical

* Professor of Anesthesiology.

† Assistant in Anesthesiology.

Received from the Department of Anesthesiology of Ospedale Pediatrico "A. Meyer," Via Luca Giordano n. 13, Firenze, Italy. Accepted for publication June 26, 1987. Presented in part at the Annual Meeting of the Association of Paediatric Anaesthetists, Sheffield (England), March, 1986.

Address reprint requests to Dr. Busoni: Via II Prato, 11, 50123 Firenze, Italy.

Key words: Anesthesia; pediatrics. Anesthetic techniques: regional; sacral intervertebral epidural block.

‡ Perifix, Braun.

TABLE 1. Physical Details of Patients Studied

	Mean	Standard Deviation	Range
Age (years)	5.06	3	0.2-13.4
Weight (kg)	18.7	8	5.4-42
Height (cm)	107.6	21	59-155
Skin-to-epidural space distance (mm)	16.7	5	8-30

abnormalities or an abundance of fat tissue overlying the sacrum.

The relationship between age and skin-to-dura distance of all the patients studied was plotted in Fig. 2. There was no case of dural puncture, signs of blood on aspiration and other complications. Vomiting occurred in seven children several hours postoperatively. No child vomited during surgery or in the immediate postoperative period.

DISCUSSION

In early post-natal life, the sacrum consists of five distinct vertebrae.⁷ The vertebral bodies are separated by intervertebral discs and, posteriorly, a ligamentum flavum joins the upper border of the lamina to the lower border of the lamina above.⁸ At this stage, therefore, the sacrum is very similar to the lumbar spine. However, as ossification proceeds, fusion occurs between the sacral segments, beginning with the two lowest about the age of 18 yr, and extending cephalad until the process is complete between the 25th and 30th yr.⁷

Although other sacral intervertebral spaces could

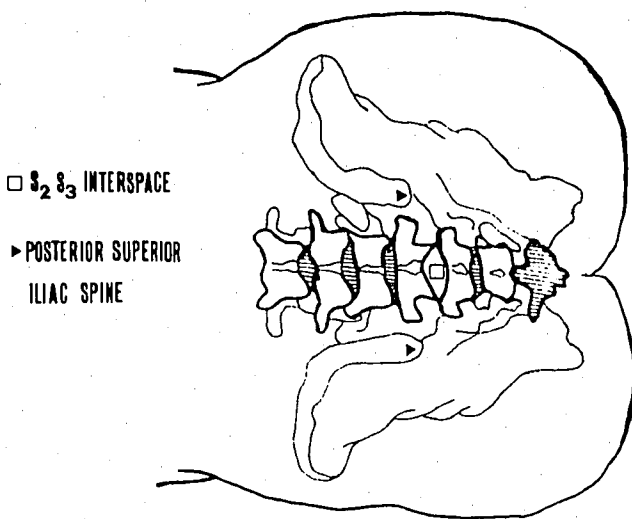


FIG. 1. Reference points for the identification of the S2-S3 interspace which is immediately below the line joining the posterior superior iliac spines.

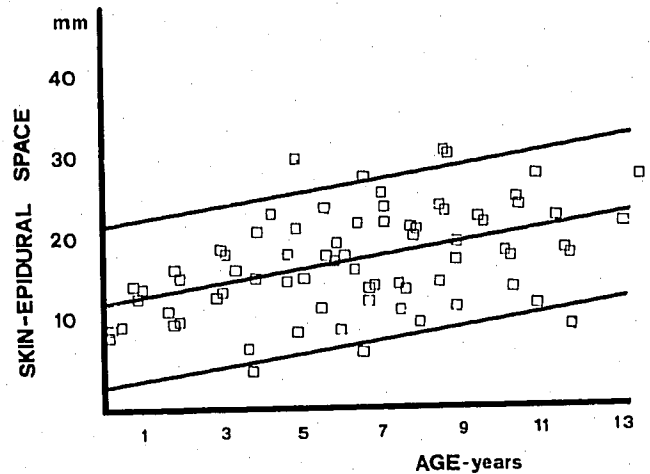


FIG. 2. Scatter diagram of the relationship between age and skin-dura distance. The regression line equation is $Y = 0.8435X + 12.46$ ($r = 0.5531$). The two parallel lines, each having vertical distance $Sy \cdot x = 1.645$, are the 90% confidence limits. X = age, years; Y = skin-dura distance (mm); $Sy \cdot x$ = standard error of estimate of Y on X .

safely be used, S2-S3 was chosen because it is the largest and the easiest space to identify. Since ossification of the sacrum proceeds from below upward, this interspace remains patent until comparatively late in a child's development—the oldest child in this series was 13.5 yr. The posterior superior iliac spines are reliable landmarks, because they are always palpable and often visible in children. The dural sac is said to end at S2,¹ but individual variation is likely, and dural puncture at S2-S3 interspace should be regarded as a possibility although it did not occur in this series.

The use of loss of resistance for identification of the epidural space has the advantage that most anesthesiologists are familiar with it. The ligament was always easy to identify, and the "give" as the needle entered the epidural space was clearly evident in every case. However, the distance of the space from the skin could not be accurately predicted because it depends largely on the amount of fat overlying the sacrum.

No undesirable sequelae were encountered in this series, except vomiting in seven patients. However, our initial study was limited only to 74 patients, and we expect that complications, such as dural puncture or toxic phenomena, are likely to occur as the number of cases increases. However, in using the S2-S3 approach, complications, such as traumatic injuries of spinal cord or spinal arteries, which are located much higher in the spinal canal,⁹ are unlikely.

Many anesthesiologists are unwilling to insert caudal catheters because it is difficult to insure that this area, so near to the anus, remains clean.¹⁰ However, if a catheter is inserted in S2-S3, this area is much easier to keep

sterile, and the danger of infections due to soiling is reduced.

In conclusion, we found sacral intervertebral epidural block to be a safe and easily performed alternative to the more commonly used caudal approach. It is particularly valuable for patients in whom an epidural catheter is required for postoperative pain control, and those in whom a caudal anatomy is distorted or caudal blockade is not desirable.

The authors are grateful to Dr. Edward N. Armitage for advice and helpful criticism.

REFERENCES

1. Schulte-Steinberg O, Rahlfs VW: Spread of extradural analgesia following caudal injection in children: A statistical study. *Br J Anaesth* 49:1027-1034, 1977
2. McCaul K: Caudal blockade, Neural Blockade. Edited by Cousins

- MJ, Bridenbaugh PO. New York, JB Lippincott, 1980, pp 275-293
3. Bromage PR: Epidural Analgesia. Philadelphia, Saunders, 1979, pp 193-194
4. Armitage EN: Caudal block in children. *Anaesthesia* 34:396, 1979
5. Busoni P, Andreuccetti T: The spread of caudal analgesia in children: A mathematical model. *Anaesth Intensive Care* 14:140-144, 1986
6. Schulte-Steinberg O, Rahlfs VW: Caudal anaesthesia in children and spread of 1% lignocaine: A statistical study. *Br J Anaesth* 42:1093-1099, 1979
7. Pick PT, Howden R: Gray's Anatomy, Descriptive and Surgical. Philadelphia, Running Press, 1974, pp 49-50
8. Testut L, Latarjet A: Anatomia Umana. Torino, Unione Tipografica Editrice Torinese, 1959, p 85
9. Cousins MJ: Epidural neural blockade, Neural Blockade. Edited by Cousins MJ, Bridenbaugh PO. New York, JB Lippincott, 1980, pp 190-191
10. Armitage EN: Regional anaesthesia in paediatrics, Clinics in anaesthesiology, Paediatric Anaesthesia. Edited by Sumner E, Hatch DJ. London, Saunders, 1985, p 560

Anesthesiology
67:995-998, 1987

Depression of the Swallowing Reflex during Sedation and/or Relative Analgesia Produced by Inhalation of 50% Nitrous Oxide in Oxygen

TAKASHI NISHINO, M.D.,* KAZUNORI TAKIZAWA, D.M.D.,†
NOBUKO YOKOKAWA, M.D.,‡ KAZUAKI HIRAGA, M.D.‡

Swallowing results in reflex closure of the glottis, and has an obvious protective value against the aspiration of foreign materials into the respiratory tract. The protective pharyngeal and laryngeal reflexes, including the swallowing reflex, are depressed by deep general anesthesia.¹⁻⁴ Perhaps swallowing reflex is also obtunded during sedation and/or relative analgesia (stage I of anesthesia). We, therefore, examined changes in activity of the swallowing reflex during sedation and/or relative analgesia produced by inhalation of 50% nitrous oxide (N₂O) in oxygen (O₂) by applying a new method which tests the swallowing response in a quantitative manner.

MATERIALS AND METHODS

Ten male volunteers aged 28-39 yr were studied. All were physicians and were in good health. The protocol of the present study was approved by the Ethics Committee of the hospital. All subjects had no oral intake for 4 h before the study. Before the beginning of the experiment, a respiratory inductive plethysmography (RIP: RespiTraceTM; Ambulatory Monitoring Inc., Ardsley, NY) was placed onto the subject and calibrated using the least squares method as described by Chadha *et al.*⁵ Then, each subject rested in the supine position for 10 min, during which time a multiple-purpose catheter having a diameter of 1.35 mm was inserted through the naris so that the tip of the catheter lay in the epipharynx. Following the insertion of this nasal catheter, the subject was asked to breathe through his nose, and the subject's mouth was sealed with a wide surgical adhesive.

The experiment was started while the subject was quietly breathing 100% O₂ through a tightly fitting nasal mask connected to a T-piece system. The swallowing reflex was induced by a bolus injection of a small amount of distilled water into the pharynx through the

* Vice-director of Operation Theater.

† Clinical fellow.

‡ Staff Anesthesiologist.

Received from the Department of Anesthesiology, National Cancer Center Hospital, Tokyo, Japan. Accepted for publication June 29, 1987.

Address reprint requests to Dr. Nishino: Department of Anesthesiology, National Cancer Center Hospital, Tsukiji 5-1-1, Chuo-ku, Tokyo 104, Japan.

Key words: Anesthetics, gases; nitrous oxide. Reflex: swallowing reflex.