

particularly pronounced in debilitated or elderly patients.

REFERENCES

1. Pleasants J: The case against relative analgesia. *Dent Clin N Am* 15:839-847, 1971
2. Brock-Utne JG, Wining TJ, Rubin J, Kingston HGG: Laryngeal incompetence during neurolept analgesia in combination with diazepam. *Br J Anaesth* 48:699-701, 1976
3. Rubin J, Brock-Utne JG, Greenberg M, Bortz J, Downing JW: Laryngeal incompetence during experimental "relative analgesia" using 50% nitrous oxide in oxygen. *Br J Anaesth* 49:1005-1008, 1977
4. Cleaton-Jones P: The laryngeal-closure reflex and nitrous oxide analgesia. *ANESTHESIOLOGY* 45:569-570, 1976
5. Chadha TS, Watson H, Birch S, Jenouri GA, Schneider AW, Cohn MA, Ackner MA: Validation of respiratory inductive

- plethysmography using different calibration procedures. *Am Rev Respir Dis* 125:644-649, 1982
6. Nishino T, Yonezawa T, Honda Y: Effects of swallowing on the pattern of continuous respiration in human adults. *Am Rev Respir Dis* 132:1219-1222, 1985
7. Parbrook GD: Levels of N₂O anesthesia. *Br J Anaesth* 39:974-982, 1967
8. Nishino T, Honda Y, Kohchi T, Shirahata M, Yonezawa T: Effects of increasing depths of anaesthesia on phrenic nerve and hypoglossal nerve activity during the swallowing reflex in cats. *Br J Anaesth* 57:208-213, 1985
9. Nishino T, Kohchi T, Honda Y, Shirahata M, Yonezawa T: Differences in the effects of hypercapnia and hypoxia on the swallowing reflex in cats. *Br J Anaesth* 58:903-908, 1986
10. Taylor PA, Towey RM: Depression of laryngeal reflexes during ketamine anaesthesia. *Br Med J* 19:688-689, 1971
11. Pontoppidan H, Beecher HK: Progressive loss of protective reflexes in the airway with the advance of age. *JAMA* 174:2209-2213, 1960

Anesthesiology
67:998-1000, 1987

Hypocalcemia and Prolonged QT Interval Following Carotid Artery Surgery

EDWARD A. ZANE, M.D.,* JAMES B. EISENKRAFT, M.D.,† MOSHE HAIMOV, M.D.‡

Hypocalcemia is a complication of thyroidectomy, and is caused by the accidental removal of the parathyroid glands or by a compromise of their vascular supply.¹ We describe a patient who, following right carotid endarterectomy, developed a prolonged QT interval due to acute hypocalcemia.

CASE REPORT

A 60-yr-old (60-kg, 160-cm) woman was evaluated for headaches associated with a tingling sensation in the left hand. Bilateral carotid artery disease was found with a 90% stenosis of the right carotid bifurcation. The patient was scheduled to undergo a right carotid endarterectomy. She had essential hypertension for 10 yr and hypothyroidism for 8 yr. She had a lumbar laminectomy performed under uneventful general anesthesia 12 yr previously. She was taking levothyroid 0.125 mg daily, captopril 12.5 mg qd, aspirin 325 mg qd, and calcium 500 mg tid as prophylaxis against postmenopausal osteoporosis. Three weeks prior to admission, the patient had reduced her calcium supplementation to 500 mg qd. Preoperative laboratory data

revealed a hematocrit of 39%, hemoglobin 12.9 gm/dl, a normal clotting profile, normal serum electrolytes, calcium 9.6 mg/dl (normal range 8.5-11.0), phosphate 3.4 mg/dl (normal range 2.5-6.0), protein 6.5 g/dl (normal range 6.5-8.5), and albumin 4.8 g/dl (normal range 3.5-4.8). On admission, the chest radiograph showed a normal-sized heart and normal lung fields. The preoperative EKG showed a normal sinus rhythm with non-specific ST-T wave changes and a QT interval, corrected for heart rate (QTc), of 0.42 s (fig. 1A).

Morphine sulfate, 10 mg im, and diazepam, 5 mg po were given for premedication. Monitoring consisted of an automated blood pressure cuff, EKG, esophageal stethoscope and temperature probe, and mass spectrometer. Anesthesia was induced with thiopental 5 mg/kg, pancuronium 0.1 mg/kg, and lidocaine 1.0 mg/kg iv, and the trachea was intubated with an 8.0-mm ID cuffed endotracheal tube. Anesthesia was maintained with nitrous oxide 50% in oxygen and isoflurane 0.4-0.6% (end tidal). The intraoperative course was unremarkable except for the incidental surgical finding of the vagus nerve lying anterior in the right carotid sheath instead of in its usual postero-lateral position. Intraoperative arterial blood pressures ranged from 125-160 mmHg systolic over 80-100 mmHg diastolic, with a heart rate between 85-90 bpm. Normocapnea was maintained throughout the procedure, and the lowest esophageal temperature measured was 36.2° C. During the procedure, 1000 cc of crystalloid solution (Normosol®) was administered iv, and the estimated blood loss was 150 cc. Residual neuromuscular blockade was reversed with neostigmine 4 mg and glycopyrrolate, 0.8 mg iv. No EKG changes were noted intraoperatively. The trachea was extubated in the operating room, and the patient was transferred to the recovery room in stable condition. There, she was mildly hypotensive (90-100/50-60 mmHg), and a postoperative EKG revealed slightly flattened T-waves as compared with the preoperative EKG and a prolonged QTc of 0.46 s (fig. 1B). The hematocrit was 35%, potassium 3.9 mEq/l, and total calcium 7.5 mg/dl. The ionized calcium concentration was 0.67 mmol/l (normal range 1.12-1.32). Ionized calcium was measured using the NOVA 6

* Resident in Anesthesiology.

† Associate Professor of Anesthesiology; Director of Research.

‡ Clinical Professor of Surgery.

Received from the Departments of Anesthesiology and Surgery, The Mount Sinai Medical Center, New York, New York. Accepted for publication June 30, 1987.

Address reprint requests to Dr. Eisenkraft: Department of Anesthesiology, Box 1010, The Mount Sinai Hospital, One Gustave L. Levy Place, New York, New York 10029.

Key words: Complications: hypocalcemia. Ions: calcium. Surgery: carotid endarterectomy.

electrolyte analyzer (NOVA Biomedical, Newton, MA). This instrument measures ionized calcium directly using an ion selective electrode. Besides a prolonged QTc interval and mild hypotension, there were no signs or symptoms of hypocalcemia, *i.e.*, no peripheral or perioral paresthesiae, carpopedal spasm, anxiety, bronchospasm, laryngospasm, seizures, chest pain, or shortness of breath.¹ Chvostek's sign was negative. Because of concern that a progression of hypocalcemia might lead to tetany or ventricular dysrhythmias, calcium gluconate, 1.0 gm, was administered slowly iv. The ionized calcium concentration increased to 1.21 mmol/l, the QTc decreased to 0.42 s (fig. 1C), and arterial blood pressure returned to the preoperative value of 120/70 mmHg. Over the next few days, plasma levels of magnesium, phosphate, and thyroid function tests were all within normal limits. The patient made an uneventful recovery from her surgery and was discharged home on the fifth postoperative day without any further complications. She was readmitted 1 month later for left carotid endarterectomy. During this second admission, and during the perioperative period in particular, no abnormalities were noted in her electrolytes (calcium 9.7 mg/dl, magnesium 1.9 mg/dl, phosphate 3.2 mg/dl, alkaline phosphatase 25 mU/ml) or in her EKGs. She was taking calcium 500 mg tid prior to the second admission.

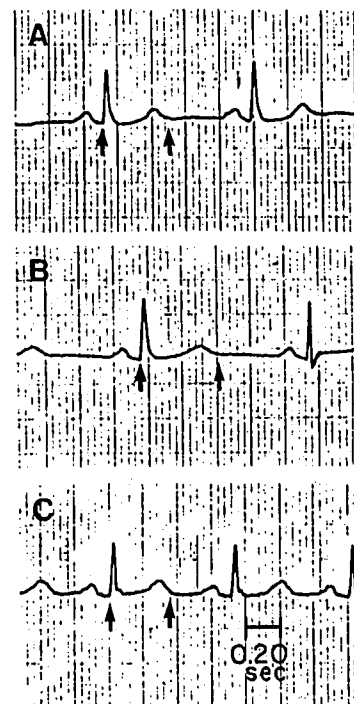
DISCUSSION

Following an uneventful carotid endarterectomy, our patient presented in the recovery room with a prolonged QT interval (QTI). The interval was prolonged even when corrected for heart rate (QTc) using a modification of Bazett's formula:² $QTc = QTI / \sqrt{R-R}$ interval. The QTI is measured from the beginning of the QRS complex to the end of the T-wave, and electrically represents both depolarization and repolarization of the ventricles. The QTI varies with age, sex, and heart rate, and is measured most accurately in an EKG lead with an initial Q before the QRS complex and where there is a distinct T-wave. The QTI should not exceed half of the R-R interval, and the upper limit of normal for the QTc is 0.44 s.²

The causes of a prolonged QTI are numerous, and include congenital and acquired etiologies.³ A few of these etiologies deserve consideration in our case. Myocardial ischemia is always a possibility in a post-surgical patient with hypertension and atherosclerotic disease, although there was no EKG evidence of ischemia. The patient was not chronically receiving any medications known to prolong the QTI, although several anesthetics can alter the QTc. Thiopental prolongs the QTc within 90 s after injection, as does succinylcholine.⁴ The potent inhaled anesthetics have not been assessed for their effects on QTc in normal patients.

Nervous system injury may alter the QTI. There was no postoperative evidence of cerebrovascular accident; however, there have been reports of prolonged QTI (in the presence of normal electrolytes and calcium) and sudden cardiac arrest following right neck dissection, secondary to surgical trauma to the cervical autonomic nervous system.⁵ Ablation of the right stellate ganglion, or stimulation of the left, prolongs the QTI and predis-

FIG. 1. EKG lead II. Paper speed 25 mm/sec. Arrows indicate points used for measurement of QTI. A. Preoperative EKG, showing QTc = 0.42 sec. B. Recovery room EKG, showing QTc = 0.46 sec. Ionized calcium was 0.67 mmol/l (normal range 1.13–1.32) C. Recovery room EKG, following treatment with calcium gluconate. QTc = 0.42 sec. Ionized calcium was 1.21 mmol/l.



poses to life-threatening ventricular dysrhythmias, especially "torsades de pointes."⁵ Because our patient had an abnormal position of the right vagus, requiring manipulation of this nerve during dissection of the carotid sheath, it is possible that concurrent right-sided sympathetic damage with predominance of left-sided sympathetic tone accounted for the prolonged QTI.

The most common causes of QTI alterations are electrolyte disturbances. It is possible that any abnormality altering sodium, potassium, magnesium, or calcium flux in cardiac muscle or conducting tissue may alter the QTI.³ Hypokalemia can cause prominent U waves and the 'Q-U' interval may be mistakenly measured, whereas hypocalcemia causes a true QTI prolongation.⁶ The relationship between ionized calcium and the duration of the QTI is well known.^{2,7-9} It is the increased duration of phase 2 of the ventricular action potential that results in an increased duration of the S-T segment and, therefore, of the QTI.¹⁰ With the exception of hypothermia, there are probably no other agents or metabolic abnormalities which prolong the duration of the S-T segment without changing the duration of the T-wave, although this can be difficult to interpret on an EKG.¹⁰

In the recovery room, our patient was found to have a total serum calcium of 7.5 mg/dl and an ionized calcium of 0.67 mmol/l. It is at concentrations below this that the symptoms of hypocalcemia and tetany begin to develop.¹ Since severe disturbances in ionized calcium homeostasis may occur without important changes in

total calcium,¹¹ and only the ionized form is physiologically active,² it is important to obtain an ionized calcium where available. Our patient had an ionized calcium of 0.67 mmol/l and, therefore, was truly hypocalcemic regardless of serum albumin or pH.

Having determined the probable cause of this patient's prolonged QTI, the etiology of the acute hypocalcemia remains unresolved. Ionized calcium concentration is affected by blood pH, which alters calcium binding to protein carboxyl groups. Acute acidosis decreases protein binding and increases ionized calcium, while acute alkalosis increases protein binding and decreases ionized calcium. Hyperventilation, sufficient to cause an increase of 0.1–0.2 units in blood pH, produces a 10–15% reduction in the ionized calcium concentration. There was, however, no reason to suspect an acute respiratory alkalosis of sufficient severity to cause such a change in this patient. Heparin may reduce ionized calcium by direct binding, although this is probably not significant in the relatively small dose (5000 units) used in this case.

A well-recognized cause of hypocalcemia is primary hypoparathyroidism following parathyroidectomy and thyroidectomy. Symptomatic hypocalcemia usually occurs 24–72 h postoperatively, but may occur in the immediate postoperative period.^{1,12} Spontaneous recovery of parathyroid function usually returns after a transient compromise of the blood supply.¹ The vascular supply to the parathyroids is *via* branches of the inferior thyroid artery, which is a branch of the thyrocervical trunk of the subclavian.¹³ It is most likely that, in our patient, compromise of this blood supply during carotid endarterectomy caused transient hypoparathyroidism with resultant hypocalcemia. This could occur if the patient had two or fewer parathyroid glands, since the contralateral glands would still be expected to produce hormone. Indeed, in a large series of adults studied at

autopsy, 0.6% had two or fewer parathyroid glands.¹⁴ Continuous monitoring of the EKG in the recovery room facilitated early detection and treatment of hypocalcemia in this patient, possibly preventing hypocalcemic tetany and/or severe ventricular dysrhythmias.

REFERENCES

1. Woodhouse NJ: Hypocalcemia and hypoparathyroidism. *Clin Endocrinol Metab* 3:323–340, 1974
2. Drop LJ: Ionized calcium, the heart, and hemodynamic function. *Anesth Analg* 64:432–451, 1985
3. Galloway PA, Glass PSA: Anesthetic implications of prolonged QT interval syndromes. *Anesth Analg* 64:612–620, 1985
4. Saarnivaara L, Lingren L: Prolongation of QT interval during induction of anaesthesia. *Acta Anaesthesiol Scand* 27:126–130, 1983
5. Otteni JC, Pottecher T, Bronner G, Flesch H, Diebolt JR: Prolongation of the QT interval and sudden cardiac arrest following right radical neck dissection. *ANESTHESIOLOGY* 59:358–361, 1983
6. Surawicz B, Lepeschkin E: Electrocardiographic pattern of hyperpotassemia with and without hypocalcemia. *Br Heart J* 8:801, 1953
7. Nierenberg DM, Ransil BJ: Q-aTc interval as a clinical indicator of hypercalcemia. *Am J Cardiol* 44:243–248, 1979
8. Rumancik WM, Denlinger JK, Nahrwold ML, Falk RB: The QT interval and serum ionized calcium. *JAMA* 240:366, 1978
9. Scheidegger D, Drop LJ: The relationship between duration of QT interval and plasma ionized calcium concentration. *ANESTHESIOLOGY* 51:143–148, 1979
10. Surawicz B: Relationship between electrocardiogram and electrolytes. *Am Heart J* 73:814–834, 1967
11. Ladenson JH, Lewis JW, Boyd JC: Failure of total calcium corrected for protein, albumin, and pH to correctly assess free calcium status. *J Clin Endocrinol Metab* 46:986–993, 1978
12. Hardy JD: *Complications in Surgery and their Management*, 4th edition. Philadelphia, WB Saunders Co, 1987, pp 309–310
13. Gardner E, Gray DJ, O'Rahilly R: *Anatomy*, 4th edition. Philadelphia, WB Saunders Co, 1975, p 690
14. Alverdy A: Parathyroid glands in thyroid surgery. *Acta Chir Scand (Suppl)* 389:1, 1968