

The Effect of Bupivacaine Scalp Infiltration on the Hemodynamic Response to Craniotomy under General Anesthesia

DAVID R. HILLMAN, M.B., B.S., F.F.A.R.A.C.S.,* GEORGE W. RUNG, M.D.,†
WALTER R. THOMPSON, M.B., B.S., F.F.A.R.A.C.S.,* NEVILLE J. DAVIS, M.B., B.S., F.F.A.R.A.C.S.‡

We have observed that skin incision for elective craniotomy is frequently accompanied by tachycardia and arterial hypertension, despite an apparently adequate prior depth of general anesthesia (GA). The potential for morbidity is high in patients with intracranial pathology where hypertension may cause significant elevation of intracranial pressure¹ or precipitate intracranial hemorrhage, particularly in the presence of vascular tumors or cerebrovascular anomalies, such as aneurysms or malformations.² The problem may be overcome by increasing anesthetic depth or by administration of antihypertensive drugs. Because these treatments take time to initiate and risk hypotension, we sought to prevent or attenuate the hemodynamic response by infiltration of the scalp with a local anesthetic prior to skin incision. As the practice had not previously been systematically evaluated, we compared the effect of scalp infiltration with 0.5% bupivacaine (without vasoconstrictor) with that of normal saline in a double blind randomized fashion.

MATERIAL AND METHODS

Forty-two patients presenting for elective craniotomy for tumor within the cranial vault were studied, as approved by our local committee. Patients with unstable hypertension, receiving beta adrenergic blocking drugs, or with previous scalp incision were excluded from the study.

Forty-two pairs of 20-ml sterile glass ampules were prepared by the hospital pharmacy, 21 pairs containing normal saline and 21 pairs containing bupivacaine 0.5% (without vasoconstrictor). The ampules were identical in outward appearance, except for a code number

which identified the contents. The availability of two vials for each code number allowed for breakage, the need for more than 20 ml for infiltration, and the need to repeat studies in the event of technical difficulties with recording equipment. The code was kept by the department secretary, and was not broken until all the data were collected and tabulated.

Each patient was premedicated with Temazepam, an oral benzodiazepine derivative, 20 mg, 1-1.5 h prior to arrival in the operating room. Prior to induction of GA, the radial artery was cannulated under local anesthesia. An electrocardiogram (ECG) monitor was attached. Arterial blood pressure was measured with a pressure transducer. ECG, heart rate (HR), mean arterial pressure (MAP), and arterial pressure wave form were recorded continuously from at least 3 min prior to induction of anesthesia until dural incision was complete. The times of induction of GA, endotracheal intubation, scalp infiltration, scalp incision, scalp flap reflection, craniotomy, and dural opening were noted on the recordings.

Induction of GA was accomplished with thiopental 5 mg/kg and phenoperidene, a potent narcotic analgesic, 0.04 mg/kg iv. Succinylcholine 1.2 mg/kg was administered iv to facilitate endotracheal intubation. Anesthesia was maintained with nitrous oxide 67%, oxygen 33%, and d-tubocurarine 0.4 mg/kg. Ventilation was controlled to maintain end tidal P_{CO_2} at 30-35 mmHg.

Infiltration of the scalp was performed by the surgeon after skin preparation, prior to draping the patient with the intention of allowing a minimum of 5 min to elapse before incision. Both the incision line and the proposed line of scalp flap reflection were infiltrated. Sustained severe hypertension (>20% rise in MAP above the pre-induction levels) was treated with additional thiopental, phenoperidine, or hydralazine, iv according to the discretion of the anesthetist. Such treatments were noted on the recordings.

Eight events were identified for the purpose of comparison: 1) pre-induction of GA, 2) post-endotracheal intubation, 3) pre-scalp infiltration, 4) post-scalp infiltration, 5) post-scalp incision, 6) scalp flap reflection, 7) craniotomy, and 8) dural incision. Mean HR and MAP data for each of these events was extracted from the polygraph tracings, using a digital plotter and micro-

* Consultant.

† Registrar.

‡ Head of Department.

Received from the Department of Anaesthesia and Intensive Care, Sir Charles Gairdner Hospital, Nedlands, Western Australia. Accepted for publication July 2, 1987.

Address reprint requests to Dr Hillman: Department of Anaesthesia and Intensive Care, Sir Charles Gairdner Hospital, Nedlands, Western Australia, 6009, Australia.

Key words: Anesthesia; neurosurgical. Anesthetics, local: bupivacaine. Anesthetic techniques, regional: infiltration.

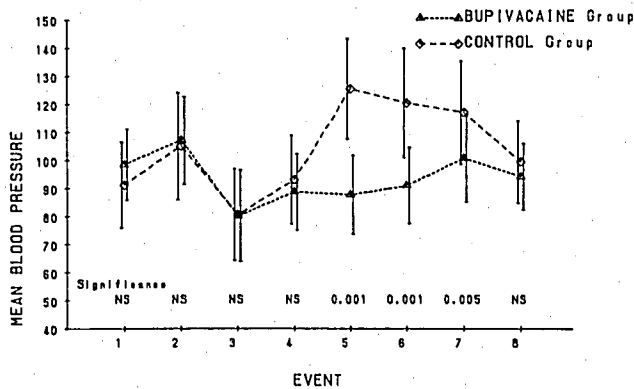


FIG. 1. Mean arterial blood pressure (mmHg) from induction of general anesthesia to dural opening in the bupivacaine and saline (control) groups. Bars indicate \pm one standard deviation. The statistical significance of the differences between each group at each event are displayed along the bottom (NS = not significant). Events: 1 = pre-induction of general anesthesia; 2 = post-endotracheal intubation; 3 = pre-scalp infiltration; 4 = post-scalp infiltration; 5 = post-scalp incision; 6 = post-scalp flap reflection; 7 = craniotomy; 8 = dural opening.

computer program to average the data over the period of extraction. This period was between 1 and 3 min (2.2 ± 0.8 min, mean \pm SD) to ensure that it truly characterized the levels at the time. To verify that the data extraction was accurate, it was also extracted manually on a separate occasion.

After data extraction and final tabulation, the code was broken and the two groups (saline [control] and bupivacaine) identified. Statistical comparison between the two groups at each event was made using an unpaired *t* test.

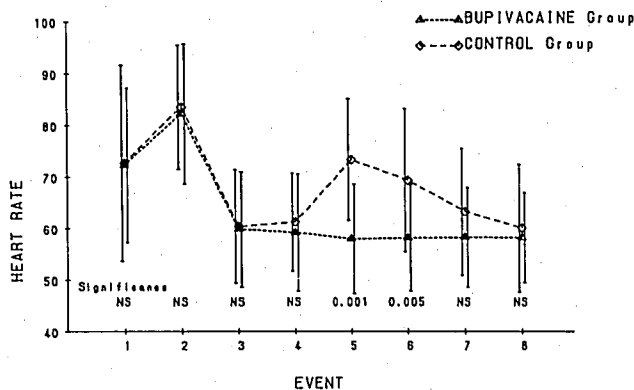


FIG. 2. Mean heart rate (min^{-1}) from induction of general anesthesia to dural opening in the bupivacaine and saline (control) groups. Bars indicate \pm one standard deviation. The statistical significance of the differences between each group at each event are displayed along the bottom (NS = not significant). Events: 1 = pre-induction of general anesthesia; 2 = post-endotracheal intubation; 3 = pre-scalp infiltration; 4 = post-scalp infiltration; 5 = post-scalp incision; 6 = post-scalp flap reflection; 7 = craniotomy; 8 = dural opening.

RESULTS

The two groups were well matched for age, weight, sex, and type of craniotomy. The saline group had ten men and 11 women with mean age 55.5 ± 12.8 yr. The bupivacaine group had nine men and 12 women with mean age 55.4 ± 15.3 yr.

The mean volumes of saline and bupivacaine injected were 14.5 ± 2.5 ml and 16.4 ± 5 ml, respectively. The mean time between infiltration of the scalp and skin incision was 5.5 ± 1.9 min in the saline group and 6.3 ± 3.2 min in the bupivacaine group.

No significant difference in MAP or HR occurred between the groups from induction of anesthesia until scalp incision commenced (Figs. 1, 2). During scalp incision, a marked difference developed between the saline group, in whom hypertension and tachycardia occurred, and the bupivacaine group, where there was little change in these variables. The difference in MAP and HR persisted through scalp reflection. The difference in MAP remained apparent during craniotomy. It was not until dural opening that both the tachycardia and hypertension in the saline group had resolved and the data of the two groups converged. Eleven patients in the saline group required additional thiopental, phenoperidine, and, in two cases, hydralazine because of sustained severe hypertension. No patients in the bupivacaine group required this treatment. No clinically apparent adverse reactions attributable to systemic absorption of bupivacaine were noted.

DISCUSSION

The notable cardiovascular stability seen in the bupivacaine group confirmed our impression that local anesthetic scalp infiltration prior to craniotomy minimizes the hemodynamic responses to skin incision. Prevention of tachycardia and hypertension circumvents the need for increase in anesthetic depth or antihypertensive treatments which take time to initiate and may transiently produce hypotension.

The benefits of local anesthetic infiltration persisted beyond scalp incision to include the craniotomy itself. Furthermore, by the time of dural opening, the hypertension and tachycardia observed earlier in the saline group had resolved. These findings are attributable to the mode of innervation of the scalp and cranium and the effect of local anesthesia. Subcutaneous local anesthetic scalp infiltration blocks peripheral nerves supplying the skin, subcutaneous tissue, muscle, and periosteum of the outer table of the skull. The periosteum of the inner table of the skull (dura mater) is innervated by nerves accompanying the meningeal arteries which are not blocked by this technique. However, the dura is relatively insensitive to painful stimuli, except in prox-

imity to the larger meningeal arteries.³ Hence, local anesthetic scalp infiltration would be expected to block most of the afferent neural pathways of significance in the production of these hemodynamic responses.

The differences observed between the two groups may have been greater had not severe hypertension been treated with additional opiate, thiopental, or hydralazine in 11 patients in the saline group. No one in the bupivacaine group required this treatment.

Mixtures of local anesthetics and vasoconstrictor have long been injected into the scalp prior to craniotomy to promote hemostasis.⁴⁻⁵ While these mixtures provided a readily available formulation of dilute vasoconstrictor, the effect of the local anesthetic content on the hemodynamic response to craniotomy under GA has not previously been systematically evaluated. We avoided the use of vasoconstrictor in our local anesthetic solution, as an accidental intravascular injection or systemic absorption may cause hypertension.⁴ We chose bupivacaine because of its long duration of action and safety when used in the vascular tissues of the scalp.⁶

The narcotic/relaxant GA used is similar to that employed in many centers.^{7,8} The results in our control group suggest that such a GA technique alone may not adequately control the hemodynamic responses to craniotomy in a large proportion of patients, at least without use of high doses of narcotics. Supplementation by local anesthetic scalp infiltration appears to overcome the problem without risk of unacceptable increases in

intracranial pressure, as may occur when volatile anesthetic agents are used, including isoflurane.⁹

In summary, our results demonstrate that local anesthetic scalp infiltration significantly improves cardiovascular stability during craniotomy under narcotic/relaxant general anesthesia, suggesting that its routine use should be considered under such circumstances.

REFERENCES

1. Lassen NA, Christensen MS: Physiology of cerebral blood flow. *Br J Anaesth* 48:719-734, 1976
2. Shapiro HM: Intracranial hypertension: Therapeutic and anesthetic considerations. *ANESTHESIOLOGY* 43:445-471, 1975
3. Penfield W: Combined regional and general anesthesia for craniotomy and cortical exploration. *Int Anesthesiol Clin* 24(3):1-11, 1986
4. Christensen KN, Jensen JK, Sogaard I: Blood pressure response to administration of local anesthetics with noradrenaline in craniotomies. *Acta Neurochirurgica* 51:157-160, 1980
5. Stoelting RK: Plasma lidocaine concentrations following subcutaneous or submucosal epinephrine-lidocaine injection. *Anesth Analg* 57:724-726, 1978
6. Colley PS, Heavner JE: Blood levels of bupivacaine after injection into the scalp with and without epinephrine. *ANESTHESIOLOGY* 54:81-84, 1981
7. Samuels SI: Anesthesia for supratentorial tumor, *Anesthesia and Neurosurgery*. Edited by Cottrell JE, Turndorf H. St Louis, CV Mosby, 1980, p 163
8. Campkin TV, Turner JM: *Neurosurgical Anaesthesia and Intensive Care*. London, Butterworths, 1980, pp 132-133
9. Grosslight K, Foster R, Colohan AR, Bedford RF: Isoflurane for neuroanesthesia: Risk factors for increases in intracranial pressure. *ANESTHESIOLOGY* 63:533-536, 1985

Anesthesiology
67:1003-1005, 1987

Intraoperative Cardiac Dysrhythmias in a Patient With Bulimic Anorexia Nervosa

DONALD E. ARNOLD, M.D.,* ROBERT J. ROSE, M.D.,† PRISCILLA STODDARD, C.R.N.A.‡

Anorexia nervosa is a syndrome characterized by extreme weight loss, distorted body image, and a fear of becoming obese. Bulimia, a distinct syndrome, is characterized by binge-eating episodes followed by self-in-

duced vomiting, fasting, and the use of diuretics and/or laxatives.¹

Preoccupation with food is common to both syndromes. The potential for marked weight fluctuations exists with bulimia, and severe weight loss often occurs with anorexia nervosa. In addition, bulimic symptoms may be part of the anorexia nervosa syndrome. Anorexia and bulimia are estimated to effect 5-10% of adolescent girls and young women.² We report a case of cardiac dysrhythmias during general anesthesia in a patient with bulimic anorexia nervosa.

* Resident in Anesthesiology.

† Assistant Professor of Clinical Surgery, Anesthesiology.

‡ Section of Anesthesiology.

Received from the Section of Anesthesiology, Department of Surgery, Dartmouth-Hitchcock Medical Center, Hanover, New Hampshire. Accepted for publication July 7, 1987.

Address reprint requests to Dr. Rose: Section of Anesthesiology, Dartmouth-Hitchcock Medical Center, Hanover, New Hampshire 03756.

Key words: Complications: dysrhythmias. Ions: potassium. Metabolism: anorexia nervosa; bulimia.

CASE REPORT

A 16-yr-old girl presented in the ambulatory surgery unit for dental extractions. The patient had a 1-yr history of anorexia nervosa with