

6. Foldes FF, Nagashima H, Boros M, Tassonyi E, Fitzal S, Agoston S: Muscular relaxation with atracurium, vecuronium, and Duador under balanced anaesthesia. *Br J Anaesth* 55:97S-103S, 1983
7. Agoston S: Clinical pharmacology of vecuronium: A preliminary report on a multicentre study in 800 patients, Proceedings of the symposium on clinical experiences with Norcuron (Org NC45, vecuronium bromide). Edited by Agoston S, Bowman WC, Miller RD, Viby-Mogensen J. Amsterdam, Excerpta Medica, 1983, pp 99-108
8. Baraka A, Noueihed R, Sinno H, Wakid N, Agoston S: Succinylcholine-vecuronium (Org NC45) sequence for cesarean section. *Anesth Analg* 62:909-913, 1983
9. Dailey PA, Fisher DM, Shnider SM, Baysinger CL, Shinohara Y, Miller RD, Abboud TK, Kim KC: Pharmacokinetics, placental transfer, and neonatal effects of vecuronium and pancuronium administered during cesarean section. *ANESTHESIOLOGY* 60:569-574, 1984
10. Rodrigue R, Durant NN, Nguyen N, Katz L, Conklin KA: Comparison of vecuronium-induced neuromuscular blockade in pregnant and nonpregnant female rabbits. *ANESTHESIOLOGY* 65:A401, 1986

Anesthesiology
67:1008-1009, 1987

Burn, Erosion, and "Sun"tan With the Use of Pulse Oximetry in Infants

KATSUYUKI MIYASAKA, M.D.,* JUN OHATA, M.D.†

The less-invasive nature of pulse oximetry has contributed greatly to monitoring in anesthesia and critical care medicine. We have been using various pulse oximeters for the past 8 yr in children, and have encountered three complications, as described below.

CASE REPORTS

Case 1. A 3-month-old infant was admitted for elective repair of a right inguinal hernia. A pulse oximeter (Nellcor® N-100 probe 1-25, Nellcor) was placed on the left great toe to collect normal baseline data the night before surgery. A nurse removed the probe 6 h later because the infant had been unusually irritable. She found a localized skin burn underneath the photo-transmitter side of the probe. The skin lesion turned into a blister (fig. 1).

Upon investigation, the surface temperature of the photo-transmitter side of this particular probe showed over 70° C. The overheating was not solved by using another new probe. The device was returned to the manufacturer for repair. The skin burn healed without any sequelae.

Case 2. A 4-month-old infant was paralyzed and ventilation controlled following repair of congenital tracheal stenosis. The ear probe of a pulse oximeter (Biox III®, Ohmeda) was placed on the upper part of the left antihelix. Because of the stable readings, the probe was left

in place for over 48 h without reclipping or relocating. An area of mild skin erosion was noted underneath the ear probe, presumably because of clipping pressure. It healed without any sequelae.

Case 3. An 8-month-old infant's ventilation was controlled following a repair of total anomalous pulmonary venous return. The left foot was fixed on a splint and a pair of fiberoptic finger probes of a pulse oximeter (Mochida MET 147®, Minolta) was attached for 5 continuous days. Upon removal of the probe, a localized tanned area coinciding with the photo-transmitter probe was noted. No thermal injury or skin burn was noted, and the hyperpigmentation had faded 3 months later.

DISCUSSION

Recent articles on the use of pulse oximetry mainly stress its usefulness and the non-invasive nature.¹⁻³ Although the complications described by us were of a mild nature, they could become serious if unnoticed for an extended period of time. Until real electric safety is established by the manufacturer, routine evaluation of the probe site is mandatory.

Pressure erosion or necrosis can and should be prevented. Until a better ear probe is developed, ear probes should be reclipped or relocated frequently during use. Although we have not experienced pressure necrosis, the tight application of flexible finger probes with elastic adhesive tape could cause this. The use of double-sided self-adhesive tape may solve this, but would prevent routine evaluation of the probe site because of possible skin abrasion upon removal, especially in premature infants. Since pulse oximetry does not require probes to be in tight contact with skin, unlike transcutaneous oxygen electrodes, the construction of probes may need to be modified to avoid these problems in pediatric use.⁴

In summary, non-invasive pulse oximetry is not necessarily harmless. We have observed one skin burn from

* Director, Department of Anesthesia and ICU, Pathophysiology Research Laboratory, Children's Medical Research Center.

† Staff Anesthetist, Department of Anesthesia and ICU.

Received from the Department of Anesthesia and ICU, and the Pathophysiology Research Laboratory, Children's Medical Research Center, National Children's Hospital, Setagaya, Tokyo, Japan. Accepted for publication July 14, 1987. Work was done at the National Children's Hospital.

Address reprint requests to Dr. Miyasaka, Department of Anesthesia and Intensive Care Unit, Pathophysiology Research Laboratory, Children's Medical Research Center, National Children's Hospital, Setagaya, Tokyo, Japan.

Key words: Anesthesia: pediatrics. Complications: burn. Monitoring: pulse oximeter.

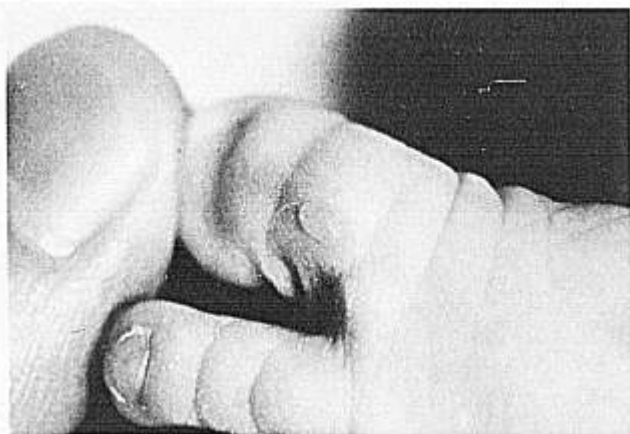


FIG. 1. A localized skin burn and blister formation developed underneath the photo-transmitter side of a pulse oximeter probe on the left great toe of a 3-month-old infant (case 1).

a 70° C LED, one ear pressure necrosis, and one ultraviolet skin tanning (with a fiberoptic model). This indicates that the probes used in pulse oximetry requires special attention and frequent probe site inspection.

REFERENCES

1. Solimano AJ, Smyth JA, Mann TK, Albersheim, SG, Lockitch G: Pulse oximetry advantages in infants with bronchopulmonary dysplasia. *Pediatrics* 78:844-849, 1986
2. Deckerdt R, Steward DJ: Non-invasive arterial hemoglobin saturation versus transcutaneous oxygen tension monitoring in the preterm infant. *Crit Care Med* 12:936-938, 1984
3. Jennis MS, Peabody JL: No burns, no gradient-pulse oximetry, an alternative to transcutaneous PO₂ (abstract). *Clin Res* 33:139A, 1985
4. Miyasaka K: Use of non-invasive oximetry during the induction of anesthesia in children, *Pulse Oximeter*. Edited by Payne JP, Severinghaus JW. New York, Springer-Verlag, 1986, pp 95-100

Anesthesiology
67:1009-1012, 1987

High-frequency Jet Ventilation During Thoracic Surgical Procedures

WILLIAM S. HOWLAND, M.D.,* GRAZIANO C. CARLON, M.D.,† PAUL L. GOLDINER, M.D.,‡
SHARON-MARIE ROONEY, M.D.,§ ISIS CONCEPCION, M.D.,¶ MANJIT S. BAINS, M.D.,**
PATRICIA M. MCCORMACK, M.D.††

Several modalities of ventilation have been proposed to prevent or minimize hypoxemia during thoracotomy,^{1,2} including ventilation at suprathreshold frequencies.³⁻⁵ Since the differences among these modalities which utilize elevated rates are considerable,⁶ we examined the impact of high-frequency jet ventilation (HFJV), administered at various rates, on gas exchange in patients undergoing thoracic surgery, both while the chest cavity was open and while it was closed.

MATERIALS AND METHODS

The subjects were 120 patients scheduled for open thoracotomy involving resection of lung parenchyma or thoracic esophagus. The research protocol was approved by the Institutional Review Board, and written consent was obtained from each patient. All were premedicated with morphine, 5 mg im, and atropine, .4 mg im, approximately 1 h before surgery. Anesthesia was induced with sodium thiopental, 4 mg/kg iv, and succinylcholine, 1 mg/kg, and was maintained with an oxygen-nitrous oxide mixture (40:60-50:50), supplemented with intravenous fentanyl, droperidol, pancuronium bromide, and sodium thiopental as needed. Endotracheal intubation was performed with an 8-8.5-mm diameter National Catheter Hi-Lo® disposable endotracheal tube. This device had an extruded lumen that permitted measurement of airway pressure 5-6 centimeters above the carina. The airway pressure port was connected to a pressure transducer and a monitoring oscilloscope through an air-filled catheter. Inspired oxygen concentration (F_IO₂) was measured with a paramagnetic oxygen analyzer placed between the ventilator Y-connector and the endotracheal tube. ECG was displayed on a monitor oscilloscope, and radial arterial and central venous pressures were directly measured *via*

* Past Chairman of Anesthesiology.

† Chief, Critical Care Medicine Service.

‡ Chairman of Anesthesiology. Current address: Department of Anesthesiology, Albert Einstein University, Bronx, New York.

§ Attending Anesthesiologist.

¶ Clinical Assistant Anesthesiologist.

** Associate Attending Surgeon.

†† Assistant Attending Surgeon.

Received from the Departments of Anesthesiology, Critical Care Medicine, and Surgery, Memorial Sloan-Kettering Cancer Center, and Cornell University Medical College, New York, New York. Accepted for publication July 15, 1987.

Address reprint requests to Dr. Carlon: Department of Anesthesiology and Critical Care Medicine, Memorial Sloan-Kettering Cancer Center, 1275 York Avenue, New York, New York 10021.

Key words: Anesthesia, thoracic; gas exchange; high-frequency jet ventilation. Lung. Surgery: thoracic. Ventilation: high-frequency; mechanical.