

Anesthesiology
67:1017, 1987

The Effect of Autotransfusion on Catecholamine Levels During Pheochromocytoma

To The Editor:—Smith *et al.*¹¹ reported abrupt hypertension with autologous blood transfusion in a patient during bilateral pheochromocytoma resection. They attributed the rise in blood pressure to high catecholamine levels in the transfused blood, but did not measure these concentrations. In order to confirm their proposed mechanism of hypertension, we measured catecholamine levels during the resection of a bilateral pheochromocytoma in a 63-yr-old man. In table 1, these levels are shown. We conclude from the very high epinephrine and norepinephrine concentrations in the packed red blood cells, that hypertension following infusion of this blood is not only possible, but likely.

MARK J. RICE, M.D.
Assistant Professor of Anesthesiology

EDWARD V. VIOLANTE, M.D.
Resident in Anesthesiology

JOHN F. KREUL, M.D.
Associate Professor of Anesthesiology

*Department of Anesthesiology
University of Wisconsin
Madison, Wisconsin 53792*

Anesthesiology
67:1017-1018, 1987

TABLE 1. Catecholamine Concentrations

Sample	Dopamine (ng/l)	Epinephrine (ng/l)	Norepinephrine (ng/l)
Pre-induction (serum)	20	740	730
Right tumor resected (serum)	60	2500	1330
Left tumor manipulation (serum)	50	16100	6700
Both tumors resected (serum)	50	430	790
Collection chamber	*	1580000	240000
First wash sample	*	1670000	260000
Second wash sample	*	550000	82000
Packed red blood cells	50	27000	3800

* Unable to quantitate secondary to high norepinephrine interference.

REFERENCE

1. Smith DF, Mihm FG, Mefford I: Hypertension after intraoperative autotransfusion in bilateral adrenalectomy for pheochromocytoma. *ANESTHESIOLOGY* 58:182-184, 1983

(Accepted for publication August 12, 1987.)

Another Aspect of Celiac Plexus Block

To the Editor:—Celiac plexus block is frequently used for relief of pain due to cancer of the pancreas.^{1,2} Its use in alcoholic pancreatitis is less well described.³ Due to anatomical variations of the celiac ganglia from T12 to L1 vertebra,⁴ diagnostic block is important prior to neurolytic block.

Fluoroscopy is routinely used during celiac plexus block to ensure correct position of the needle prior to injection. Frames can be imaged and stored or retrieved as a radiograph or as a permanent record. We have found that it is practical and useful to photograph directly from the television monitor to verify needle position. We use the Canon® camera AE-1 model with shutter speed 1/30 s and an automatic aperture. Polaroid® Polargraph 35 mm black-and-white, high-contrast, instant slide film (HC-135) with ASA 400 setting is used with a Polaroid® slide autoprocesing kit.

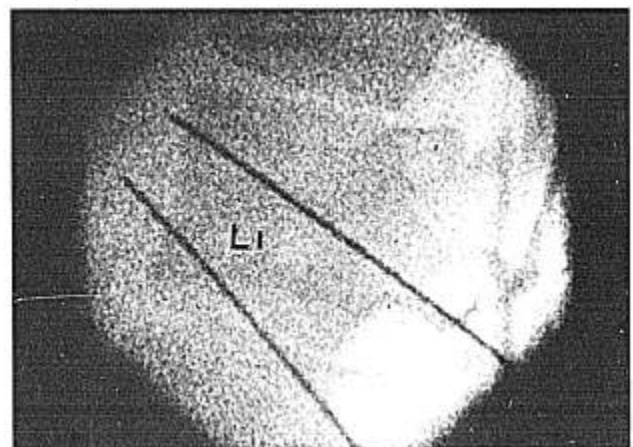


FIG. 1. Lateral view of needle positions in relations to first lumbar vertebra.