

## The Effect of Autotransfusion on Catecholamine Levels During Pheochromocytoma

*To The Editor:*—Smith *et al.*<sup>11</sup> reported abrupt hypertension with autologous blood transfusion in a patient during bilateral pheochromocytoma resection. They attributed the rise in blood pressure to high catecholamine levels in the transfused blood, but did not measure these concentrations. In order to confirm their proposed mechanism of hypertension, we measured catecholamine levels during the resection of a bilateral pheochromocytoma in a 63-yr-old man. In table 1, these levels are shown. We conclude from the very high epinephrine and norepinephrine concentrations in the packed red blood cells, that hypertension following infusion of this blood is not only possible, but likely.

MARK J. RICE, M.D.  
*Assistant Professor of Anesthesiology*

EDWARD V. VIOLANTE, M.D.  
*Resident in Anesthesiology*

JOHN F. KREUL, M.D.  
*Associate Professor of Anesthesiology*

*Department of Anesthesiology  
University of Wisconsin  
Madison, Wisconsin 53792*

TABLE 1. Catecholamine Concentrations

Sample	Dopamine (ng/l)	Epinephrine (ng/l)	Norepinephrine (ng/l)
Pre-induction (serum)	20	740	730
Right tumor resected (serum)	60	2500	1330
Left tumor manipulation (serum)	50	16100	6700
Both tumors resected (serum)	50	430	790
Collection chamber	*	1580000	240000
First wash sample	*	1670000	260000
Second wash sample	*	550000	82000
Packed red blood cells	50	27000	3800

\* Unable to quantitate secondary to high norepinephrine interference.

## REFERENCE

1. Smith DF, Mihm FG, Mefford I: Hypertension after intraoperative autotransfusion in bilateral adrenalectomy for pheochromocytoma. *ANESTHESIOLOGY* 58:182-184, 1983

(Accepted for publication August 12, 1987.)

## Another Aspect of Celiac Plexus Block

*To the Editor:*—Celiac plexus block is frequently used for relief of pain due to cancer of the pancreas.<sup>1,2</sup> Its use in alcoholic pancreatitis is less well described.<sup>3</sup> Due to anatomical variations of the celiac ganglia from T12 to L1 vertebra,<sup>4</sup> diagnostic block is important prior to neurolytic block.

Fluoroscopy is routinely used during celiac plexus block to ensure correct position of the needle prior to injection. Frames can be imaged and stored or retrieved as a radiograph or as a permanent record. We have found that it is practical and useful to photograph directly from the television monitor to verify needle position. We use the Canon® camera AE-1 model with shutter speed 1/30 s and an automatic aperture. Polaroid® Polarograph 35 mm black-and-white, high-contrast, instant slide film (HC-135) with ASA 400 setting is used with a Polaroid® slide autoprocessing kit.

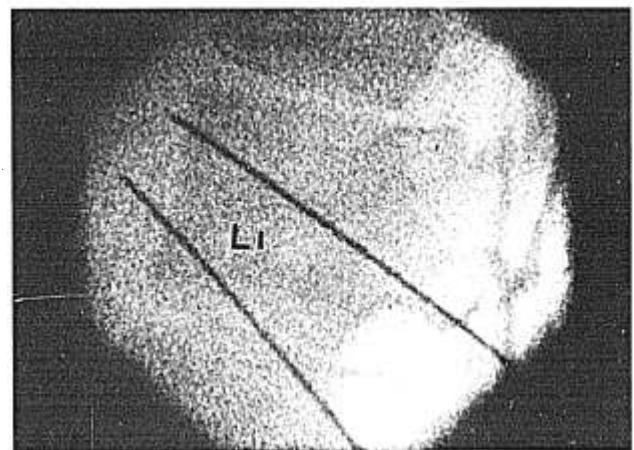


FIG. 1. Lateral view of needle positions in relations to first lumbar vertebra.

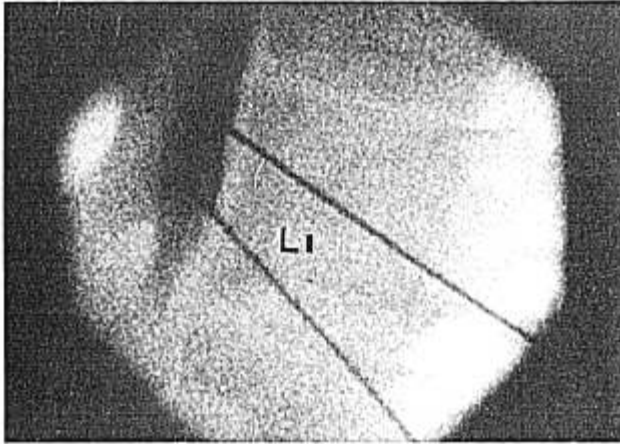


FIG. 2. Lateral view showing retroperitoneal spread of Hypaque® solution.

Antero-posterior and lateral views are taken to confirm the needle position (fig. 1). Two ml of Hypaque® 50% is diluted with 2 ml lidocaine 1%. The solution is divided equally and injected through each needle. Any spread of contrast medium is noted (fig. 2) prior to injection of the final neurolytic solution.

This method is especially useful for record keeping, presentations, lectures, and conferences.

Anesthesiology  
67:1018-1019, 1987

### Problems Associated with Endotracheal Tubes with Monitoring Lumens in Pediatric Patients

*To the Editor:*—In our institution, we have encountered several potential problems using uncuffed endotracheal tubes (ET) with a monitoring lumen (Malinckrodt, Glens Falls, NY) in neonates and pediatric patients. The monitoring lumen is a separate tube within the ET with a port located at the distal tip of the ET tube to sample end-tidal concentrations of gas. This may provide a greater correlation of end-tidal  $\text{CO}_2$  and  $\text{P}_{\text{CO}_2}$  values in patients weighing less than 8.0 kg, de-

pending upon the type of breathing circuit and ventilator utilized.<sup>1</sup>

There are several points that must be taken into account when using this type of endotracheal tube. First, the outside diameter (OD) is larger than the corresponding sized endotracheal tube without the monitoring lumen (table 1). This may affect the tube size used, especially in patients less than 1 yr of age. Also, a larger than expected OD can result in a "tight fit" in the region of the cricoid cartilage with development of ischemia with complications of post-intubation croup and subglottic stenosis.<sup>2</sup> Second, the port of the monitoring lumen can be easily obstructed with mucus, blood, etc., resulting in the loss of end-tidal gas monitoring. Third, ET tubes with monitoring lumens do not have a Murphy eye, and this may increase the risk of complete ET tube obstruction. Finally, proper stabilization of the monitoring lumen and sampling tube is necessary to minimize tension on the tube and avoid either kinking the ET tube or accidentally extubating the patient.

TABLE 1. Outside Diameters (OD) of Endotracheal Tubes With and Without Monitoring Lumens

Inside Diameter Size (mm)	OD Without (mm)	OD With (mm)
2.5	3.6	3.9
3.0	4.3	4.5
3.5	4.9	5.2
4.0	5.6	6.0
4.5	6.2	6.6
5.0	6.9	7.4
5.5	7.5	8.1

GABRIEL LU, M.D.  
Assistant Professor

ELIZABETH A. M. FROST, M.D.  
Professor

PAUL L. GOLDINER, M.D.  
Professor and Chairman

Department of Anesthesiology  
Albert Einstein College of Medicine of Yeshiva University  
1300 Morris Park Avenue  
Bronx, New York

#### REFERENCES

1. Thompson GE, Moore DC, Bridenbath LD, Artin RY. Abdominal pain and alcohol celiac plexus nerve block. *Anesth Analg* 56:1-6, 1977
2. Moore DC, Bush WH, Burnett LL. Celiac plexus block: A roentgenographic, anatomic study of technique and spread of solution in patients and corpses. *Anesth Analg* 60:369-379, 1981
3. Bell SN, Cole R, Roberts-Thomson IC. Coeliac plexus block for control of pain in chronic pancreatitis. *Br Med J* 281:1604, 1980
4. Ward EM, Rorie DK, Nauss LA, Bahn RC. The celiac ganglia in man: Normal anatomic variations. *Anesth Analg* 58:461-465, 1979

(Accepted for publication August 14, 1987.)