

6. Van Assendelft OW: Spectrophotometry of Haemoglobin Derivatives. Springfield, Charles C Thomas, 1970, pp 55-60
7. Orkin FK: Acquired methemoglobinemia and sulfhemoglobinemia, Complications in Anesthesiology. Edited by Orkin FK, Cooperman LH. Philadelphia, JB Lippincott Co., 1983, pp 495-504
8. Gilman AG, Goodman LS, Rall TW, Murad F: Goodman and Gilman's The Pharmacological Basis of Therapeutics. New York, Macmillan, 1985, pp 1212-1213
9. Smith RP, Olson MV: Drug-induced methemoglobinemia. *Semin Hematol* 10:253-268, 1973

Anesthesiology
68:282-285, 1988

Transesophageal Atrial Pacing for the Treatment of Dysrhythmias in Pediatric Surgical Patients

WILLIAM J. GREELEY, M.D.,* J. G. REVES, M.D.†

Cardiac dysrhythmias occur frequently in pediatric patients with congenital heart defects during general anesthesia, and may cause hemodynamic instability.¹ Urgent treatment of hemodynamically significant dysrhythmias in children during surgery heretofore has required antiarrhythmic therapy where efficacy is unpredictable. Alternatively, emergency transvenous cardiac pacing, which is highly invasive and technically difficult, is possible. We report two cases where transesophageal atrial pacing was successfully performed in pediatric surgical patients in the treatment of hemodynamically significant dysrhythmias during general anesthesia.

REPORT OF TWO CASES

Case 1. A 4-day-old, 3.1-kg neonate with Ebstein's anomaly (right ventricular dysplasia, tricuspid regurgitation, and Wolff-Parkinson-White syndrome) and pulmonary atresia was anesthetized for a right modified Blalock-Taussig (BT) shunt. At the time of the procedure, the patient had severe hypoxemia due to reduced pulmonary blood flow despite prostaglandin E₁ therapy. Chest radiograph showed cardiomegaly and echocardiogram demonstrated generalized hypertrophy of both ventricles in addition to the abovementioned structural defects. The electrocardiogram showed right atrial enlargement, biventricular hypertrophy, and pre-excitation syndrome (WPW). Prior to surgery, the patient developed several episodes of a wide QRS tachycardia (heart rates 240-260 bpm associated with hypotension) which was diagnosed as a reentrant supraventricular tachycardia (SVT) with antegrade conduction along the accessory pathway. These episodes were initially treated with cardioversion; the patient was then given a loading dose of procainamide (6 mg/kg iv), and a continuous iv infusion of procainamide (50 μg · kg⁻¹ · min⁻¹) was begun. Digoxin was

contraindicated because of the tendency to accelerate conduction in the accessory pathway; propranolol was inadvisable because of the presence of cardiomegaly and signs of congestive heart failure; and verapamil was not administered because of the propensity of this drug to produce significant hypotension in infants. Upon achieving therapeutic levels of procainamide, the episodes of SVT were well controlled.

General anesthesia was induced and maintained with sufentanil (10 μg/kg) and pancuronium (0.1 mg/kg) iv with a FI_{O₂} of 1.0. Ventilation was controlled, and the patient was placed in a left lateral position for the surgical procedure. In addition to standard noninvasive monitoring, a radial artery catheter was inserted for the continuous measurement of arterial blood pressure and monitoring of arterial blood gases. A 12-French cardioesophagoscope (Portex Inc., Wilmington, MA) was placed in the esophagus to the point of maximal atrial waveform, as previously reported, and used for dysrhythmia detection, as well as auscultation of heart and breath sounds.¹ During dissection of the pulmonary artery and surgical manipulation of the heart, sudden onset of a wide QRS tachycardia at 240 bpm associated with hypotension (mean arterial pressure = 30-35 mmHg) was observed (fig. 1A). Immediate cardioversion was indicated, but internal defibrillation required extension of the incision across the midline and external defibrillation required immediate breakdown of the sterile surgical field. Therefore, an urgent attempt at esophageal pacing was performed. The two esophageal electrode wires at the proximal end of the cardioesophagoscope were attached to a pacing pulse generator, and atrial pacing with the esophageal catheter was begun at a rate of 320 bpm and a pulse width of 3 ms. The current was increased until capture was achieved at 10 mA. The pacing artifact obscured the QRS, and pacing was confirmed by monitoring the arterial pressure waveform. Atrial overdrive pacing was continued for 5 s, and then the pulse generator was turned off. We observed the immediate return of the rhythm to a sinus mechanism at a rate of 150 bpm on the ECG limb leads and the return of the arterial blood pressure to normal (fig. 1B). A second, similar intraoperative episode of SVT was observed and successfully treated in the same manner. The remainder of the operative course was uneventful, and the patient was taken to the pediatric intensive care unit in satisfactory condition.

The postoperative course was marked by persistent respiratory failure due to congestive heart failure and right hemidiaphragm paralysis requiring mechanical ventilation. On the 6th postoperative day, the patient underwent an uneventful fiberoptic bronchoscopy under general anesthesia to determine reversible causes of respiratory failure. At the time of bronchoscopy, the entire esophagus was directly examined through the bronchoscope, and no evidence of esophageal injury was visualized. Because of the paradoxical motion of the paralyzed right diaphragm during spontaneous breathing contributing to ventilatory dependency, the patient was scheduled for a diaphragmatic plication at

* Assistant Professor of Anesthesiology and Pediatrics; Associate in Pediatric Cardiology.

† Professor of Anesthesiology; Director of Cardiac Anesthesia.

Received from the Division of Cardiothoracic Anesthesia, Department of Anesthesiology, Duke University Medical Center, Durham, North Carolina. Accepted for publication August 31, 1987.

Address reprint requests to Dr. Greeley: Department of Anesthesiology, Duke University Medical Center, Box 3094, Durham, North Carolina 27710.

(Key words: Anesthesia; cardiac; pediatric. Complications: dysrhythmia. Heart: pacemakers; transesophageal.)

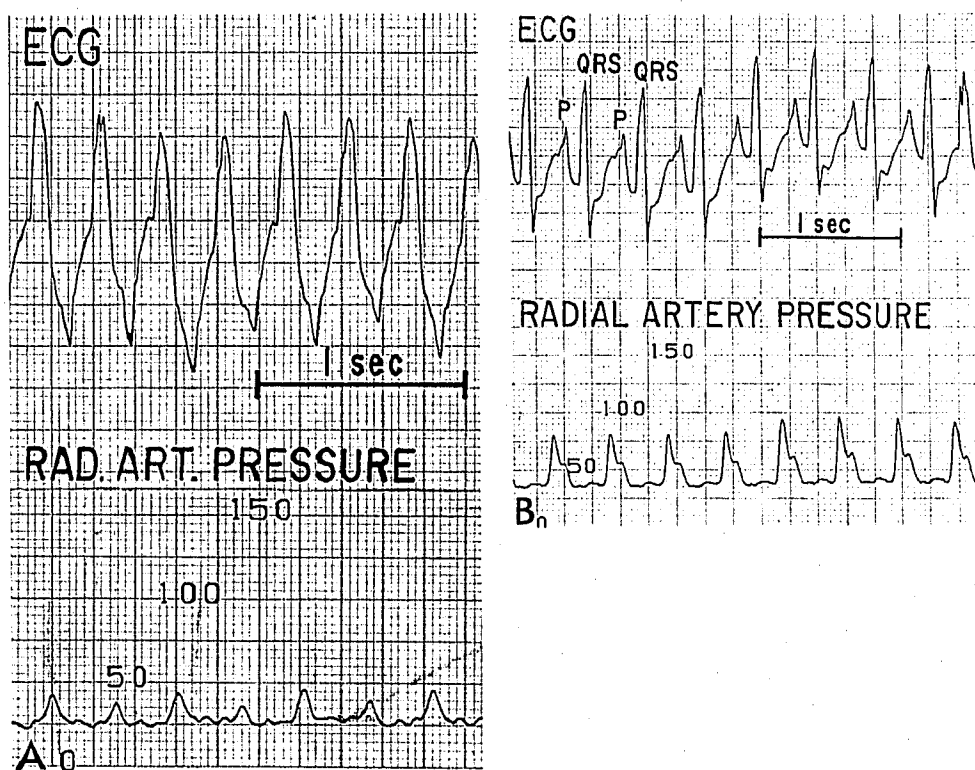


FIG. 1. Case 1. A. Continuous surface ECG recording in limb lead II of a wide QRS tachycardia (220 bpm), associated with hypotension (40/25). B. After treatment of the supraventricular tachycardia with rapid atrial transesophageal overdrive pacing, the continuous ECG recording in the esophageal lead shows sinus rhythm (150 bpm) and normal blood pressure.

the 20th day of age. At the time of surgery, the patient was receiving iv dopamine, iv furosemide for heart failure, and a procainamide iv infusion at therapeutic plasma levels for control of atrial tachyarrhythmias. Anesthesia was induced and maintained with sufentanil (10 μ g/kg) and pancuronium (0.1 mg/kg) iv with a $F_{I_{O_2}}$ of 1.0 and controlled ventilation. The anesthetic and operative courses were unremarkable, excepting two episodes of SVT associated with surgical stimulation. Both episodes of SVT were successfully treated with overdrive pacing of the atrium with the cardioesophagoscope using the pulse generator. The trachea was extubated on the 3rd postoperative day, and the patient was discharged from the hospital on the 10th postoperative day, receiving quinidine for control of SVT due to WPW syndrome. There was no apparent morbidity associated with the repetitive esophageal rapid atrial pacing.

Case 2. A 2-day-old, 3.3-kg neonate with a univentricular heart and pulmonary atresia was anesthetized for a left modified Blalock-Taussig shunt because of systemic hypoxemia. At the time of surgery, ventilation was controlled and a dopamine infusion for inotropic support and prostaglandin E_1 for maintenance of ductus arteriosus (PDA) patency and pulmonary blood flow were initiated. Monitoring included pulse oximetry and arterial blood pressure using a radial artery catheter. General anesthesia was induced and maintained with sufentanil (10 μ g/kg) and pancuronium (0.1 mg/kg) iv. Ventilation was controlled during the operative procedure. After completion of the proximal subclavian artery-to-Gortex graft anastomosis, the left pulmonary artery (PA) was cross-clamped to complete the distal anastomosis between the left PA and the Gortex graft. Because total pulmonary blood flow was PDA-dependent and the application of the cross-clamp partially occluded the PDA, pulmonary blood flow was compromised. While performing this distal anastomosis, the patient exhibited systemic arterial oxygen desaturation closely followed by bradycardia. Despite atropine and isoproterenol administration and correction of a metabolic acidosis, bradycardia persisted and perfusion remained

poor. The surgeon suggested that 5 min was required to complete the procedure, and that immediate reapplication of the cross-clamp was not possible. Thus, atrial pacing with cardioesophagoscope was attempted. Pacing was begun using a pulse generator at a rate of 150 bpm and a pulse width of 3 ms. The current was increased until capture was achieved at 8 mA. Pacing was continued until the anastomosis was completed and the cross-clamp was removed. During the period of atrial pacing, lasting 8 min, no further deterioration of systemic oxygenation or arterial blood gases was seen. The remainder of the operative course was uneventful. In the postoperative period, the patient was unable to be weaned from the ventilator due to the development of an intercurrent pneumonia, and died on the 6th postoperative day during an episode of gram negative sepsis. Autopsy revealed no gross or microscopic evidence of any esophageal damage due to pacing.

DISCUSSION

Intraoperative dysrhythmias occur occasionally in pediatric patients with cardiovascular disease, and may cause hemodynamic instability or life-threatening ventricular dysrhythmias.¹ Emergency therapy heretofore has consisted of antiarrhythmic drugs, cardioversion, transvenous pacing, or pacing from epicardial wires. The response to pharmacologic treatment may be unpredictable and/or delayed. Transvenous pacing in young infants requires access to the central circulation, and is technically difficult and time consuming. Cardioversion or pacing from epicardial wires requires exposure to the heart under sterile conditions.

Esophageal pacing offers a useful, rapid, minimally

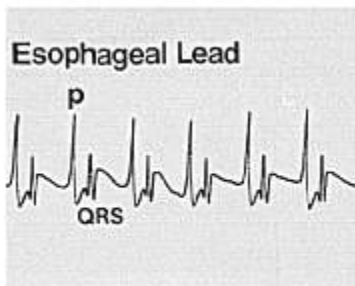


FIG. 2. An intraoperative transesophageal ECG recording showing maximal atrial electrogram amplitude (p) representing proximity of atrial electrical depolarization. Also shown is the ventricular activity (QRS) and the relationship of atrial to ventricular activity. This pattern on the esophageal electrogram

identifies the correct insertion depth necessary for optimal atrial pacing from the esophagus.

invasive, well-tolerated method of treating dysrhythmias. Cardiac pacing from an electrode within the esophagus was originally proposed in 1952 by Zoll,² and then demonstrated by Burack and Furman.³ Recent work by Gallagher *et al.*⁴ in adult patients and by Benson *et al.*⁵ in children have stressed the usefulness and safety of this technique in the treatment of life-threatening tachyarrhythmias in non-operative settings. Moreover, in the Benson *et al.* study, esophageal pacing in children was superior to antiarrhythmic therapy in the treatment of SVT and its use was recommended as a first line of therapy. In the operating room, Backofen *et al.*⁶ demonstrated the reliability of transesophageal pacing in controlling heart rates in adult patients who require temporary pacing for bradycardia during anesthesia.

Our cases suggest that emergency esophageal pacing in infants and children is feasible, and probably preferable, to emergency insertion of a transvenous catheter or drug therapy. In case one, SVT was terminated by rapid transesophageal atrial overdrive pacing, converting the rhythm to a normal sinus rhythm. In the second case, emergency transesophageal pacing was instituted for the treatment of sinus bradycardia, providing hemodynamic stability allowing the surgical procedure to be completed. In both cases, a cardioesophagoscope (Portex, Inc., Wilmington, MA) with an esophageal bipolar lead with a 22-mm interelectrode distance was positioned in the esophagus. Benson *et al.*⁷ found this interelectrode bipolar spacing to be the most efficacious and safest for transesophageal pacing.⁷ Correct catheter insertion depth is critical to minimize pacing threshold, and may be predicted by the location of the maximal bipolar atrial electrogram amplitude (fig. 2).⁷ In our patients, the thresholds needed to capture the atrium from the esophagus were 8–10 mA at a pulse duration of 3 ms. This amount of current is comparable to that used for cardiac pacing using epicardial leads, and is due to the optimal pacing characteristics of the cardioesophagoscope and the ease with which the atrium can be captured in infants and children. The current neces-

sary for transesophageal pacing these two patients was considerably lower than the reported levels of 75 mA at a pulse width of 2 ms in animals required to produce esophageal burns.⁸ In each patient, capture of the atrium was easy and reliable, and the energy levels from the pacing pulse generator did not produce demonstrable problems. There were no complications or side effects associated with the transesophageal pacing. This was determined by visual inspection of the esophagus during esophagoscopy in one patient and at autopsy in the other.

Drug therapy and DC cardioversion are standard and effective means of treating dysrhythmias which occur in the intraoperative period. There are occasions when these treatment modalities may be preferable to cardiac pacing therapy. However, for the treatment of many dysrhythmias, cardiac pacing alone or in combination with drug therapy may be the treatment of choice. The major advantages of esophageal cardiac pacing over drug therapy are that the onset and termination of pacing is immediate, safe, effective, and avoids the side effects of drug therapy. We recommend the use of esophageal atrial pacing in any pediatric patient where rapid atrial overdrive pacing is required to treat atrial dysrhythmias, such as paroxysmal atrial tachycardia, atrial flutter, or other ectopic supraventricular tachycardias. Additionally, this technique is recommended for the treatment of severe sinus bradycardia if atrioventricular conduction is intact, where overriding the spontaneous slow heart rate is accomplished by pacing the atria transesophageally. In the final analysis, the choice of therapy must be determined on the basis of clinical circumstances of each patient. Because neither ventricle is adjacent to the esophagus, experimental and clinical attempts by numerous groups to transesophageally pace the ventricle have been unsuccessful.⁴ Therefore, this technique is not recommended in situations where complete heart block is present and/or ventricular pacing is desired.

In conclusion, we describe two cases demonstrating the value of the esophageal lead for transesophageal atrial pacing in the treatment of intraoperative dysrhythmias. This technique appears to offer an effective, rapid, minimally invasive, well-tolerated method of treating dysrhythmias in children during surgery. The severity of hemodynamic instability during tachyarrhythmias and the lack of reliable intraoperative pacing capability in children emphasizes the usefulness of transesophageal atrial pacing in the pediatric age group.

REFERENCES

1. Greeley WJ, Kates RA, Armstrong BE, Grant JW: Intraoperative esophageal electrocardiography for dysrhythmia analysis and therapy in pediatric cardiac surgical patients. *ANESTHESIOLOGY* 65:669–672, 1986

- Zoll PM: Resuscitation of the heart in ventricular standstill by external stimulation. *N Engl J Med* 247:768-771, 1952
- Burack B, Furman S: Transesophageal cardiac pacing. *Am J Cardiol* 23:469-472, 1969
- Gallagher JJ, Smith WM, Ker CR, Kasell J, Cook L, Reiter M, Sterba R, Harte M: Esophageal pacing: A diagnostic and therapeutic tool. *Circulation* 62:336-341, 1982
- Benson DW, Dunnigan A, Sterba R, Benditt DG: Atrial pacing from the esophagus in the diagnosis and management of tachycardia and palpitations. *J Pediatr* 102(1):40-46, 1983
- Backofen JE, Schamble JF, Rogers MC: Transesophageal pacing for bradycardia. *ANESTHESIOLOGY* 61:777-779, 1984
- Benson DW, Sanford M, Dunnigan A, Benditt DG: Transesophageal atrial pacing threshold: Role of interelectrode spacing, pulse width and catheter insertion depth. *Am J Cardiol* 53(1):63-67, 1984
- Jenkins JM, Dick M, Collins S, O'Neill W, Campbell RM, Wilber DJ: Use of pill electrode for transesophageal pacing. *Pace* 8(4):512-527, 1985

Anesthesiology
68:285-288, 1988

Epidural Analgesia with Low-dose Bupivacaine and Fentanyl for Labor and Delivery in a Parturient with Severe Pulmonary Hypertension

DON E. ROBINSON, M.D.* CRAIG H. LEICHT, M.D., M.P.H.†

The maternal mortality among women who have primary pulmonary hypertension ranges between 40 and 60%.^{1,2} Consistent hemodynamic features include pulmonary artery pressures in excess of 30/15 mmHg or a mean PAP > 25 mmHg, right ventricular hypertrophy, and, eventually, heart failure with a low fixed cardiac output.³ Spinal or epidural anesthesia is often avoided⁴ in these patients because severe cardiovascular complications can arise when systemic vascular resistance and, hence, venous return are acutely decreased by the anesthetic-induced sympathectomy. We describe the use of a low-dose bupivacaine and fentanyl mixture for the management of labor and delivery in such a patient with severe pulmonary hypertension.

REPORT OF A CASE

A 28-yr-old woman, 162 cm, 66 kg, gravida 7, para 3, was admitted at 30 weeks of gestation because of worsening dyspnea on exertion with associated syncopal episodes. Her cardiopulmonary symptoms dated from 5 yr prior to admission and had begun immediately following her last delivery. Physical examination showed a grade III/VI holosystolic murmur, best heard at the pulmonic area, and without radiation to the neck. Pitting edema to the knees was present in both lower extremities, as well as jugular venous distention to 4 cm above the clavicle with the head elevated 30°. ECG revealed right ventricular

hypertrophy, right axis deviation, and sinus tachycardia. Chest radiograph demonstrated cardiomegaly, a prominent pulmonary artery, and cephalad distribution of flow in the pulmonary vasculature. Systemic arterial blood pressure was 82/52 mmHg with a heart rate of 105 bpm. Cardiac catheterization data included a pulmonary artery pressure (PAP) of 75/38 mmHg with a mean of 52 mmHg, right ventricular pressure of 75/23 mmHg, and right atrial pressure of 23 mmHg. Pulmonary capillary wedge pressure (PCWP) was 13 mmHg. While breathing room air, arterial blood gas analysis revealed pH 7.49, PaO₂ 100 mmHg, PaCO₂ 26 mmHg, and BE -1.6 mEq/L. Hematocrit was 29.6%, with normal serum electrolytes.

Digoxin and diuretic therapy were initiated and supplemental oxygen administered *via* nasal prongs, resulting in a rapid and marked resolution of the patient's symptoms of congestive heart failure. Because a pulmonary scan showed multiple perfusion defects with a normal ventilation scan, multiple pulmonary emboli were considered a possible etiology of her condition. Anticoagulation was instituted and maintained by a heparin drip at 1000 U/h until 3 days prior to delivery. By the morning of the planned delivery, all coagulation studies were within normal limits.

When the fetal lung profile was deemed mature by amniocentesis at 35 weeks, the patient was brought to the main operating room for elective induction of labor. Monitors included fetal heart tones, tocodynamometer, ECG, pulse oximetry (Nellcor™), arterial line, urinary catheter, and flow-directed pulmonary artery catheter. Cardiac output (CO) was measured by thermodilution. Initial hemodynamic parameters were: blood pressure 98/56 mmHg, heart rate 95 bpm, CVP 8 mmHg, PAP 53/20 mmHg with PCWP 3 mmHg, and CO 3.5 l/min. Systemic vascular resistance (SVR) and pulmonary vascular resistance (PVR) were calculated to be 1417 dyn·sec/cm⁵ and 640 dyn·sec/cm⁵, respectively. Arterial blood gas just prior to induction of labor, on O₂ 4 l/min *via* nasal prongs, showed pH 7.41, PaO₂ 160 mmHg, PaCO₂ 29 mmHg, and BE -5 mEq/l. An epidural catheter was uneventfully placed at the L2-3 interspace in the sitting position.

After ascertaining the absence of intravascular or subarachnoid effect from a 3-ml test dose of 1.5% lidocaine with 1:200,000 epinephrine, a total of 8 ml of a solution containing 0.125% bupivacaine and fentanyl 5 µg/ml was carefully titrated *via* the epidural catheter in incremental doses of ≤3 ml over a period of 15-20 min. When the onset of epidural blockade could be demonstrated by loss of sensation to cold and pinprick over the T9 to L4 dermatomes bilaterally, labor was induced with iv pitocin. The patient labored with her head elevated at 30° above horizontal and with a hip roll in place at all times. Hemodynamic measurements after institution of epidural blockade

* Fellow in Obstetrical Anesthesia.

† Staff Anesthesiologist, Director of Obstetrical Anesthesia.

Received from the Department of Anesthesia, Naval Hospital, San Diego, California 92134-5000. Accepted for publication September 2, 1987. This work was performed and supported under United States Navy Clinical Investigation Program Case Report number 84-16-1968-18. The views expressed herein are those of the authors and do not reflect the official policy or position of the Department of the Navy, Department of Defense, or the U.S. Government.

Address reprint requests to Dr. Leicht.

Key words: Anesthesia: obstetric. Anesthetics, local: bupivacaine. Anesthetic techniques: epidural; fentanyl. Heart: pulmonary hypertension.