

- Zoll PM: Resuscitation of the heart in ventricular standstill by external stimulation. *N Engl J Med* 247:768-771, 1952
- Burack B, Furman S: Transesophageal cardiac pacing. *Am J Cardiol* 23:469-472, 1969
- Gallagher JJ, Smith WM, Ker CR, Kasell J, Cook L, Reiter M, Sterba R, Harte M: Esophageal pacing: A diagnostic and therapeutic tool. *Circulation* 62:336-341, 1982
- Benson DW, Dunnigan A, Sterba R, Benditt DG: Atrial pacing from the esophagus in the diagnosis and management of tachycardia and palpitations. *J Pediatr* 102(1):40-46, 1983
- Backofen JE, Schamble JF, Rogers MC: Transesophageal pacing for bradycardia. *ANESTHESIOLOGY* 61:777-779, 1984
- Benson DW, Sanford M, Dunnigan A, Benditt DG: Transesophageal atrial pacing threshold: Role of interelectrode spacing, pulse width and catheter insertion depth. *Am J Cardiol* 53(1):63-67, 1984
- Jenkins JM, Dick M, Collins S, O'Neill W, Campbell RM, Wilber DJ: Use of pill electrode for transesophageal pacing. *Pace* 8(4):512-527, 1985

Anesthesiology
68:285-288, 1988

Epidural Analgesia with Low-dose Bupivacaine and Fentanyl for Labor and Delivery in a Parturient with Severe Pulmonary Hypertension

DON E. ROBINSON, M.D.* CRAIG H. LEIGHT, M.D., M.P.H.†

The maternal mortality among women who have primary pulmonary hypertension ranges between 40 and 60%.^{1,2} Consistent hemodynamic features include pulmonary artery pressures in excess of 30/15 mmHg or a mean PAP > 25 mmHg, right ventricular hypertrophy, and, eventually, heart failure with a low fixed cardiac output.³ Spinal or epidural anesthesia is often avoided⁴ in these patients because severe cardiovascular complications can arise when systemic vascular resistance and, hence, venous return are acutely decreased by the anesthetic-induced sympathectomy. We describe the use of a low-dose bupivacaine and fentanyl mixture for the management of labor and delivery in such a patient with severe pulmonary hypertension.

REPORT OF A CASE

A 28-yr-old woman, 162 cm, 66 kg, gravida 7, para 3, was admitted at 30 weeks of gestation because of worsening dyspnea on exertion with associated syncopal episodes. Her cardiopulmonary symptoms dated from 5 yr prior to admission and had begun immediately following her last delivery. Physical examination showed a grade III/VI holosystolic murmur, best heard at the pulmonic area, and without radiation to the neck. Pitting edema to the knees was present in both lower extremities, as well as jugular venous distention to 4 cm above the clavicle with the head elevated 30°. ECG revealed right ventricular

hypertrophy, right axis deviation, and sinus tachycardia. Chest radiograph demonstrated cardiomegaly, a prominent pulmonary artery, and cephalad distribution of flow in the pulmonary vasculature. Systemic arterial blood pressure was 82/52 mmHg with a heart rate of 105 bpm. Cardiac catheterization data included a pulmonary artery pressure (PAP) of 75/38 mmHg with a mean of 52 mmHg, right ventricular pressure of 75/23 mmHg, and right atrial pressure of 23 mmHg. Pulmonary capillary wedge pressure (PCWP) was 13 mmHg. While breathing room air, arterial blood gas analysis revealed pH 7.49, PaO₂ 100 mmHg, PaCO₂ 26 mmHg, and BE -1.6 mEq/L. Hematocrit was 29.6%, with normal serum electrolytes.

Digoxin and diuretic therapy were initiated and supplemental oxygen administered *via* nasal prongs, resulting in a rapid and marked resolution of the patient's symptoms of congestive heart failure. Because a pulmonary scan showed multiple perfusion defects with a normal ventilation scan, multiple pulmonary emboli were considered a possible etiology of her condition. Anticoagulation was instituted and maintained by a heparin drip at 1000 U/h until 3 days prior to delivery. By the morning of the planned delivery, all coagulation studies were within normal limits.

When the fetal lung profile was deemed mature by amniocentesis at 35 weeks, the patient was brought to the main operating room for elective induction of labor. Monitors included fetal heart tones, tocodynamometer, ECG, pulse oximetry (Nellcor™), arterial line, urinary catheter, and flow-directed pulmonary artery catheter. Cardiac output (CO) was measured by thermodilution. Initial hemodynamic parameters were: blood pressure 98/56 mmHg, heart rate 95 bpm, CVP 8 mmHg, PAP 53/20 mmHg with PCWP 3 mmHg, and CO 3.5 l/min. Systemic vascular resistance (SVR) and pulmonary vascular resistance (PVR) were calculated to be 1417 dyn·sec/cm⁵ and 640 dyn·sec/cm⁵, respectively. Arterial blood gas just prior to induction of labor, on O₂ 4 l/min *via* nasal prongs, showed pH 7.41, PaO₂ 160 mmHg, PaCO₂ 29 mmHg, and BE -5 mEq/l. An epidural catheter was uneventfully placed at the L2-3 interspace in the sitting position.

After ascertaining the absence of intravascular or subarachnoid effect from a 3-ml test dose of 1.5% lidocaine with 1:200,000 epinephrine, a total of 8 ml of a solution containing 0.125% bupivacaine and fentanyl 5 µg/ml was carefully titrated *via* the epidural catheter in incremental doses of ≤3 ml over a period of 15-20 min. When the onset of epidural blockade could be demonstrated by loss of sensation to cold and pinprick over the T9 to L4 dermatomes bilaterally, labor was induced with iv pitocin. The patient labored with her head elevated at 30° above horizontal and with a hip roll in place at all times. Hemodynamic measurements after institution of epidural blockade

* Fellow in Obstetrical Anesthesia.

† Staff Anesthesiologist, Director of Obstetrical Anesthesia.

Received from the Department of Anesthesia, Naval Hospital, San Diego, California 92134-5000. Accepted for publication September 2, 1987. This work was performed and supported under United States Navy Clinical Investigation Program Case Report number 84-16-1968-18. The views expressed herein are those of the authors and do not reflect the official policy or position of the Department of the Navy, Department of Defense, or the U.S. Government.

Address reprint requests to Dr. Leicht.

Key words: Anesthesia: obstetric. Anesthetics, local: bupivacaine. Anesthetic techniques: epidural; fentanyl. Heart: pulmonary hypertension.

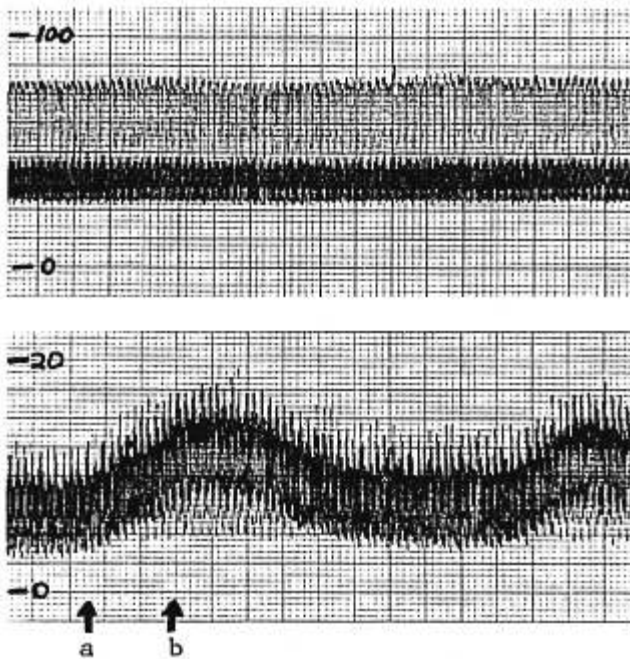


FIG. 1. Pulmonary artery (upper tracing) and central venous pressure (lower tracing) recordings during labor in a patient with primary pulmonary hypertension (in mmHg). a: Onset of contraction as indicated by rise in CVP; b: onset of contraction indicated by tocodynamometer.

showed no significant changes in arterial blood pressure, cardiac output, SVR, or PVR as demonstrated in figure 2. Excellent analgesia was noted from the very first contraction. Maintenance was provided by epidural administration of the bupivacaine/fentanyl solution at 10 ml/h via a Harvard pump. The patient never developed any degree of motor nerve blockade, nor did she ever suffer any degree of respiratory depression as assessed by her respiratory rate (never less than 15 breaths per minute) or her P_{aCO_2} (never greater than 34 mmHg). No side effects, such as pruritus or nausea, were noted.

As the intensity of contractions increased, CVP increased and decreased with each contraction; in fact, the onset of uterine contractions were heralded by a rise in the CVP before the tocodynamometer displayed any contractile activity (fig. 1). PAP was not noticeably affected by individual uterine contractions. However, with stronger contractions (and, hence, larger volume challenges due to greater volume displacement from the uteroplacental to the systemic circulation) the PAP trended steadily upward to the 60/30 mmHg range after 4 h of labor (fig. 2). Because cardiac output had also declined to 2.5 l/min and urine output was markedly decreased, dopamine was administered at $3 \mu\text{g} \cdot \text{kg}^{-1} \cdot \text{min}^{-1}$. Almost immediately (fig. 2), CO increased to 5.4 l/min, PAP returned to baseline values, and PVR decreased from 1220 to 594 $\text{dyn} \cdot \text{sec}/\text{cm}^5$. The heart rate fell from 100 to 75 bpm.

Labor proceeded uneventfully a further 10 h. However, despite continuation of low-dose dopamine and concomitant adequate cardiac output, PCWP and CVP steadily rose in the hour prior to delivery. NTG $3\text{--}4 \mu\text{g} \cdot \text{kg}^{-1} \cdot \text{min}^{-1}$ was therefore instituted, with resultant decreases in CVP from 10 to 4 mmHg and in PCWP from 15 to 4 mmHg. CO increased slightly with this therapy. A male infant was then delivered, with assigned Apgar scores of 10 at both 1 and 5 min. Despite the application of forceps (the patient was never allowed to push with contractions), no additional anesthesia was required to effect complete analgesia during delivery. Estimated blood loss during deliv-

ery was 400 ml, and total iv crystalloid replacement over the 15 h was 2500 ml. The patient was then transferred to the Intensive Care Unit for observation.

The postpartum course over the first 48 h was unremarkable, during which time anticoagulation was reinstated with heparin. She was discharged from anesthetic care. However, on the 5th postpartum day, in spite of continued intensive hemodynamic monitoring in the CCU, she became acutely hypoxemic and hypotensive. This was followed by sudden cardiovascular collapse, and all attempts at resuscitation were unsuccessful. Autopsy revealed findings consistent with primary pulmonary hypertension, with no specific cause of death.

DISCUSSION

Pregnant patients with pulmonary hypertension exhibit exquisite sensitivity to changes in afterload and preload. The pain, anxiety, and stress of delivery may exert detrimental effects by increasing pulmonary vascular resistance, while regional anesthesia may precipitate cardiovascular collapse by decreasing systemic vascular resistance and venous return. Because of the concern for possible hemodynamic changes with regional anesthesia, Mangano⁴ recommends intravenous narcotics and inhalation analgesia for labor pain in these patients. However, systemic analgesics not only may fail to relieve labor pain, but, in excessive doses, may cause maternal hypercarbia and acidosis, with resultant increases in pulmonary vascular resistance. Neonatal depression requiring narcotic reversal may also occur.

Abboud *et al.*⁵ successfully employed intrathecal morphine 1 mg for labor, but supplemental analgesia (pudendal block) was required for delivery. In addition, the use of intrathecal morphine is associated with a high incidence of pruritus, nausea and vomiting, urinary retention, and sedation, as well as a higher incidence of delayed respiratory depression when compared to epidural morphine.^{6,7} In the only other report of epidural analgesia for labor in such a patient, Sorensen *et al.*⁸ maintained segmental blockade over the T9 to L1 dermatomes with bupivacaine 0.5%. No apparent adverse effects were observed, yet the technique again required supplementation for delivery because of fear that extension of the block over a wider range of dermatomes (*i.e.*, to obtain sacral analgesia) might result in a dangerous degree of sympathectomy leading to decreased venous return. Recent reports have indicated the efficacy of low-dose bupivacaine/fentanyl mixtures for producing excellent analgesia over a broad range of dermatomes with minimal motor or autonomic side effects.⁹⁻¹¹ Indeed, in our patient, the epidural administration of such a mixture alone provided complete analgesia during all stages of labor, including outlet forcep extraction. We did not encounter any of the side effects commonly associated with epidural narcotic usage. The incidence of these side effects may be lower with the highly lipid soluble drugs, such as fentanyl or sufentanil, than with either epidural or intrathecal morphine.^{7,12,13}

The dose of fentanyl, *i.e.*, $5 \mu\text{g} \cdot \text{kg}^{-1}$, used in this case is greater than that of our current practice and was based on our clinical experience at that time. Currently, we employ a mixture of $1/8\%$ to $1/12\%$ bupivacaine with fentanyl $2 \mu\text{g} \cdot \text{ml}^{-1}$ and have found equally satisfactory results.

Even though we observed no hypotension due to our epidural blockade, similar increases in pulmonary pressures and decreases in cardiac output occurred during labor, as reported by Sorensen *et al.*⁸ We postulated impending right heart failure with shift of the interventricular septum, which was subsequently confirmed by echocardiography. Low doses of dopamine dramatically improved left ventricular stroke volume and returned pulmonary pressures to pre-labor values. The literature contains conflicting reports as to the effect of dopamine on uterine blood flow.^{17,18} At higher doses, uterine vascular resistance may increase and uterine blood flow may decrease. The effect of low-dose dopamine on uterine blood flow has not been sufficiently investigated. In this case, the fetal heart rate variability remained normal throughout the period of dopamine administration. Later, in spite of inotropic support, pulmonary artery and wedge pressures again increased as delivery became imminent. Nitroglycerin (NTG) was administered both as a treatment for these rising pressures, and as an attempt to prevent the acute increases in pulmonary pressures which might be precipitated by the autotransfusion of 1000–1500 ml of blood known to occur immediately postpartum with uterine contraction. Encouraging reports indicate that nitroglycerin $3 \mu\text{g} \cdot \text{kg}^{-1} \cdot \text{min}^{-1}$ can safely be used to provide preferential pulmonary vasodilation while maintaining systemic arterial pressure in patients with pulmonary hypertension.^{14,15} In our patient, NTG certainly increased venous capacitance while exerting minimal effect on arterial pressure, but we could not document any decrease in mean PAP or in PVR. It is possible that either our dose of NTG was not high enough to cause pulmonary vasodilation, or that a state of relatively fixed pulmonary vascular obstruction existed in this patient. This issue notwithstanding, low-dose inotropic support combined with increased venous capacitance enabled our patient to tolerate delivery-associated autotransfusion without apparent hemodynamic alteration.

This case brings to light two other points that should be considered briefly. One is the placement of an epidural catheter in a previously heparinized patient, and the other is the use of pitocin for induction in such a patient. First, there should be no increased risk of epidural hematoma formation if the heparin is discontinued for a period sufficient to allow for all coagulation factors to return to normal values; usually, 6–12 h is adequate. In this particular case, for maternal and fetal

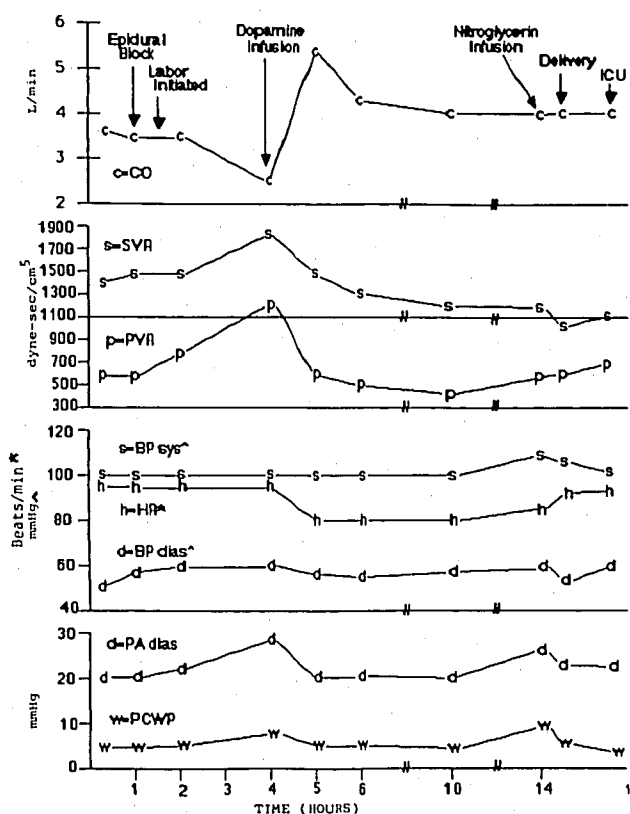


FIG. 2. Hemodynamic observations during vaginal delivery using epidural low-dose bupivacaine/fentanyl analgesia in a patient with primary pulmonary hypertension. CO = cardiac output; SVR = systemic vascular resistance; PVR = pulmonary vascular resistance; PCWP = pulmonary capillary wedge pressure.

considerations, the perinatologist chose to discontinue the heparin 72 h prior to anticipated delivery. Also of concern is the possibility of epidural bleeding upon reinstatement of heparin; however, Rao and El-Etr¹⁶ found no evidence of epidural hematoma formation in 3164 vascular surgery patients fully anticoagulated immediately after epidural catheter placement. The second consideration is that of the possible cardiovascular effects associated with the use of pitocin. Low doses given by continuous infusion generally produce no significant cardiovascular changes; however, with larger doses, especially if administered as a bolus, a 30–50% decrease in SVR has been reported.¹⁷ We monitored our patient accordingly, but observed no such changes.

We conclude that epidural administration of a low-dose bupivacaine/fentanyl solution can provide excellent analgesia for labor and delivery in parturients with severe pulmonary hypertension, and probably in those with other significant cardiac diseases, without adverse cardiovascular or respiratory effects. Invasive hemodynamic monitoring is required and the anesthetic must be slowly titrated.

REFERENCES

- Jewett JF, Ober WB: Primary pulmonary hypertension as a cause of maternal death. *Am J Obstet Gynecol* 71:1335-1341, 1956
- Nelson DM, Main E, Crafford W, Ahumada GG: Peripartum heart failure due to primary pulmonary hypertension. *Obstet Gynecol* 62:58S-63S, 1983
- Elkayam U, Gleicher N: Cardiac problems in pregnancy: Diagnosis and management of maternal and fetal disease. Edited by Elkayam U, Gleicher N. New York, A. R. Liss, Inc., 1982, pp 153-160
- Mangano DT: Anesthesia for the pregnant cardiac patient, *Anesthesia for Obstetrics*, 2nd edition. Edited by Shnider SM, Levinson G. Baltimore, Williams and Wilkins, 1979, pp 366-367
- Abboud TK, Raya JA, Noueihed R, Daniel J: Intrathecal morphine for the relief of labor pain in a parturient with severe pulmonary hypertension. *ANESTHESIOLOGY* 59:477-479, 1983
- Cousins MJ, Mather LE: Intrathecal and epidural administration of opioids. *ANESTHESIOLOGY* 61:288-289, 1984
- Abboud TK, Shnider SM, Dailey PA, Raya JA, Sarkis F, Grobler NM, Sadri S, Khoo SS, DeSousa B, Baysinger CL, Miller F: Intrathecal administration of hyperbaric morphine for the relief of pain in labour. *Br J Anaesth* 56:1351-1360, 1984
- Sorensen MB, Korshin JD, Fernandes A, Secher O: The use of epidural analgesia for delivery in a patient with pulmonary hypertension. *Acta Anaesthesiol Scand* 26:180-182, 1982
- Nalda MA, Campo F, Burzaco I: Obstetric analgesia with fentanyl-bupivacaine by the extradural route. *Br J Anaesth* 54:250P, 1982
- Youngstrom P, Eastwood D, Patel H, Bhatia R, Cowan R, Suth-eimer C: Epidural fentanyl and bupivacaine in labor: Double blind study (abstract). *ANESTHESIOLOGY* 61:A114, 1984
- Skerman JH, Thompson BA, Goldstein MT, Jacobs MA, Gupta A, Blass NH: Combined continuous epidural fentanyl and bupivacaine in labor: A randomised study (abstract). *ANESTHESIOLOGY* 63:A450, 1985
- Naulty JS, Datta S, Ostheimer GW, Johnson MD, Burger GA: Epidural fentanyl for postcesarean delivery pain management. *ANESTHESIOLOGY* 63:694-698, 1985
- Leicht CH, Rosen MA, Dailey PA, Hughes SC, Shnider SM, Baker BW, Check DB, O'Connor DE: Evaluation and comparison of epidural sufentanil and morphine for analgesia after cesarean section (abstract). *ANESTHESIOLOGY* 65:A365, 1986
- Pearl RG, Rosenthal MH: Hemodynamic effects of nitroglycerin in human pulmonary hypertension (abstract). *ANESTHESIOLOGY* 61:A31, 1984
- Pearl RG, Rosenthal MH, Schroeder JS, Ashton JPA: Acute hemodynamic effects of nitroglycerin in pulmonary hypertension. *Ann Intern Med* 99:9-13, 1983
- Rao TLK, El-Etr AA: Anticoagulation following placement of epidural and subarachnoid catheters. *ANESTHESIOLOGY* 55:618-620, 1981
- Callender K, Levinson G, Shnider SM, Feduska W, Biehl DR, Ring G: Dopamine administration in the normotensive pregnant ewe. *Obstet Gynecol* 51:586-589, 1978
- Caballum T, Zugaib M, Leib S, Nuwayhid B, Brinkman CR III, Assali NS: Effect of dopamine on hypotension induced by spinal anesthesia. *Am J Obstet Gynecol* 133:630-634, 1979

Anesthesiology
68:288-291, 1988

Negative Middle Ear Pressure and Postoperative Vomiting in Pediatric Outpatients

CAROLYNE J. MONTGOMERY, M.D., F.R.C.P.(C),* HIMAT VAGHADIA, M.B., F.R.C.P.(C),†
DEREK BLACKSTOCK, M.B., F.F.A.R.C.S.(I), F.R.C.P.(C)‡

Nitrous oxide anesthesia may cause a higher incidence of postoperative nausea and vomiting than anesthesia without nitrous oxide.^{1,2} The mechanism of this proposed effect may be related to negative middle ear pressure during recovery, stimulating the vestibular system by placing traction on the round window membrane.³ During 70% nitrous oxide administration, there is a rapid rise in middle ear pressure of approximately

1.0-2.0 cm H₂O/min⁻¹. Passive venting *via* the eustachian tube occurs at 20.0-30.0 cm H₂O.^{3,4} Negative middle ear pressures occur in the postoperative period as the nitrous oxide diffuses out rapidly. The relatively compliant walls of the eustachian tube tend to collapse and do not permit re-equilibration with atmospheric pressure.⁵ This study was designed to assess the relationship between postoperative middle ear pressure after nitrous oxide and halothane anesthesia and vomiting in pediatric outpatients.

* Clinical Fellow in Anesthesiology.

† Resident in Anesthesiology.

‡ Clinical Instructor in Anesthesiology.

Received from the Department of Anesthesia, British Columbia Children's Hospital, Vancouver, British Columbia, Canada. Accepted for publication September 14, 1987.

Address reprint requests to Dr. Blackstock: Room 1L2, Department of Anesthesia, British Columbia Children's Hospital, Vancouver, British Columbia, Canada, V6H 3V4.

Key words: Anesthesia: pediatrics. Anesthetic gases: nitrous oxide. Complications: vomiting. Ear: middle; pressure.

MATERIALS AND METHODS

With institutional approval and informed consent, 60 children, ASA physical class 1 or 2, aged 3-18 yr, were studied. Those with diseases known to increase vomiting or to contraindicate the use of nitrous oxide were excluded. Procedures on the middle ear, tonsillectomy and adenoidectomy, and ocular surgery were thus excluded. Patients with known middle ear dysfunction