

rescheduled, and the patient evaluated by muscle biopsy. If the surgery is life-saving or emergent, then I recommend intravenous dantrolene along with switching to non-triggering anesthetics and appropriate invasive monitoring.

The problem of the coincidence of trismus with malignant hyperthermia is discussed further in my editorial, and I certainly agree with Dr. Gronert's recommendation that, after trismus, patients should undergo muscle biopsy.

Although many agree that succinylcholine is a drug whose complications are so numerous that it should be used on indication only, nevertheless, succinylcholine is still used extensively in anesthesia practice. It will take many years for the new non-depolarizing relaxants to supplant succinylcholine. Therefore, I think we are

going to be faced with trismus after succinylcholine for many years to come.

HENRY ROSENBERG, M.D.
Professor and Chairman
Department of Anesthesiology
Hahnemann University
Mail Stop 310
Broad and Vine
Philadelphia, Pennsylvania 19102

REFERENCE

1. Carroll JB: Increased incidence of masseter spasm in children with strabismus anesthetized with halothane and succinylcholine. ANESTHESIOLOGY 67:559-561, 1987

(Accepted for publication December 12, 1987.)

Anesthesiology
68:655-656, 1988

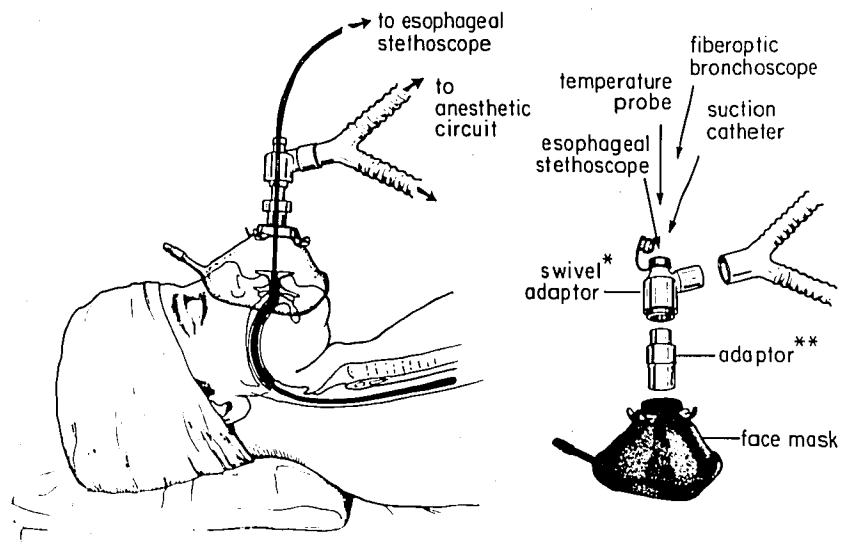
Another Use for Swivel Adaptors

To the Editor:—Heart and breath sounds are monitored with a stethoscope either placed externally on the precordium or internally in the mid-esophagus through the oro/nasopharynx. The heart beat and the breath sounds heard with the internally placed esophageal stethoscope are loud and clear because it is placed closer and separated by less dense tissue from the heart and the lung than with the precordial stethoscope. Placing the esophageal stethoscope in the oropharynx is possible only when anesthesia is administered *via* an endotracheal tube to the patient. When a face mask is used,

any probe in the oropharynx coming out between the mask and the patient's face will prevent a tight fit of the mask on the patient's face, and will interfere with adequate ventilation because of leaks.

We have designed a modification of the standard mask adaptor (fig. 1) that permits insertion of an esophageal stethoscope or any other probe (temperature, fiberoptic bronchoscope, suction catheter, or N-G tube) into the oropharynx when a face mask is being used without loss of the airtight fit of the anesthetic system. The modification consists of a swivel adaptor (Portex®)

FIG. 1. *Left.* The fully assembled system with the esophageal stethoscope passing through the swivel adaptor in an anesthetized patient. *Right.* The exploded view. *Portex® swivel adaptor Fiberoptic H 625 109. **Modified Jackson Rees' circuit (Vital Signs®) H 5102.



and a second adapter (Vital Signs®), both of which are interposed between the y piece of the circle and the mask. Stimulation of the pharynx in an inadequately anesthetized patient may cause bucking and coughing. Therefore, as when inserting an airway, the probes should be placed in the pharynx only after the patient is anesthetized.

SOMASUNDARAM THIAGARAJAH, M.D.
Associate Clinical Professor

OWEN SIMON, M.D.
Resident

*Department of Anesthesiology
Beth Israel Medical Center
Mount Sinai School of Medicine
First Avenue at 16th Street
New York, New York 10003*

(Accepted for publication December 12, 1987.)

Anesthesiology
68:656, 1988

Use of Etomidate for Elective Cardioversion

To the Editor:—Recently, the use of etomidate for elective cardioversion has been described.¹ We present a case where myoclonic movements secondary to etomidate interfered with an elective cardioversion.

A 67-yr-old, 60-kg man was scheduled for an elective cardioversion for atrial fibrillation. The patient was given .15 mg/kg of etomidate intravenously. The patient became unresponsive to verbal stimuli, and then developed gross myoclonic movements. The patient was then immediately cardioverted. The myoclonic movements continued after the cardioversion such that it was impossible to ascertain by the electrocardiogram whether the patient still had atrial fibrillation. When the myoclonic movements finally stopped, it was determined that the cardiac rhythm was still atrial fibrillation. Four minutes after the initial bolus of etomidate, the patient was awake and responsive to verbal commands. We then elected to give the patient 125 mg of thiopental intravenously. After administration of the thiopental, there were no myoclonic movements, and cardioversion restored cardiac rhythm to normal sinus rhythm.

The incidence of myoclonus after etomidate administration has been reported to be 10–38% (1.2). Any drug that causes significant myoclonus can cause difficulty in

the interpretation of electrocardiograms. The inability to readily interpret a patient's cardiac rhythm because of myoclonus can be especially troubling to both the anesthesiologist and the cardiologist. Therefore, we feel that etomidate may not be the ideal anesthetic agent for cardioversions.

MARK S. SHULMAN, M.D.
Assistant Professor

ROBERT EDELMANN, M.D.
Resident

*Department of Anesthesiology
St. Elizabeth's Hospital
Tufts University School of Medicine
Boston, Massachusetts 02135*

REFERENCES

1. Ford SR, Maze M, Gaba DM: Etomidate vs thiopental anesthesia for elective cardioversion (abstract). *ANESTHESIOLOGY* 67:A143, 1987
2. Fragen RJ, Caldwell N: Comparison of a new formulation of etomidate with thiopental—side effects and awakening times. *ANESTHESIOLOGY* 50:242–244, 1979

(Accepted for publication December 18, 1987.)

Anesthesiology
68:656–657, 1988

Inadvertent Intra-arterial Injection of Vecuronium

To the Editor:—The inadvertent intra-arterial injection of anesthetic agents has been a well-recognized operating room hazard for many years.^{1,2} Severe tissue ischemia, gangrene, and loss of a limb may follow the intra-arterial injection of a wide variety of agents, in-

cluding barbiturates, narcotics, and phenothiazines,³ although other frequently used drugs appear not to cause tissue damage.^{3,4} Awareness of the likely sequelae of intra-arterial administration of specific drugs is clearly of prognostic value, as well as of relevance to the man-