

anterior and a lateral chest radiograph. This problem was realized by Rosenberg *et al.*,<sup>1</sup> and the catheter was inserted into the pleural cavity by the surgeon while the chest was open.<sup>1</sup>

5. Intrapleural insertion of a catheter in non-thoracic surgical patients introduces the risk of tension pneumothorax. Proper equipment and personnel should be available at hand for rapid insertion of a chest tube.

The results of our pilot study are in agreement with those reported by Rosenberg *et al.*,<sup>1</sup> and were reason enough to terminate our evaluation of intrapleural analgesia. We would like to voice a word of caution regarding the high incidence of systemic side effects associated with intrapleural infusion of local anesthetics. This method does not provide effective intercostal analgesia and is of limited value for pain relief after thoracic surgery.

NABIL EL-BAZ, M.D.

*Associate Professor*

*Department of Anesthesiology*

L. PENFIELD FABER, M.D.

*Professor*

*Department of Cardiovascular and Thoracic Surgery*

ANTHONY D. IVANKOVICH, M.D.

*Professor and Chairman*

*Department of Anesthesiology*

*Rush Medical College*

*Rush-Presbyterian-St. Luke's Medical Center*

*Chicago, Illinois 60612*

#### REFERENCES

1. Rosenberg PH, Scheinin BMA, Lepantalo MJA, Lindfors O: Continuous intrapleural infusion of bupivacaine for analgesia after thoracotomy. *ANESTHESIOLOGY* 67:811-813, 1987
2. Kvalheim L, Reiestad F: Intrapleural catheter in the management of postoperative pain. *ANESTHESIOLOGY* 61:A231, 1984
3. Reiestad F, Smoskag KE, Holmquist E: Intrapleural administration of bupivacaine in postoperative management of pain. *ANESTHESIOLOGY* 65:A204, 1986
4. Seltzer JL, Larijani GE, Goldberg ME, Marr AT: Intrapleural bupivacaine—A kinetic and dynamic evaluation. *ANESTHESIOLOGY* 67:798-800, 1987
5. El-Naggar MA, Read C, Yogaratnam G, Poritz A, Bennett B: Intrapleural intercostal nerve block using 0.75% bupivacaine. *ANESTHESIOLOGY* 67:A258, 1987

(Accepted for publication December 17, 1987.)

Anesthesiology  
68:810-811, 1988

### A Stylet for Difficult Intubations

*To the Editor:*—We report a simple, inexpensive, and easy to construct device that is useful in assisting in difficult tracheal intubations.

Intubating stylets have been reported useful in performing difficult orotracheal intubations in patients with "anterior larynxes" or other causes of inadequate glottic exposure.<sup>1-3</sup> When the larynx is only partially visualized on laryngoscopy, it is difficult to insert an endotracheal tube directly, as the tube further obscures vision of laryngeal structures. In this situation, it is often possible to intubate the trachea with the thinner and more maneuverable intubating stylet, and to then guide an endotracheal tube into the trachea over the stylet.

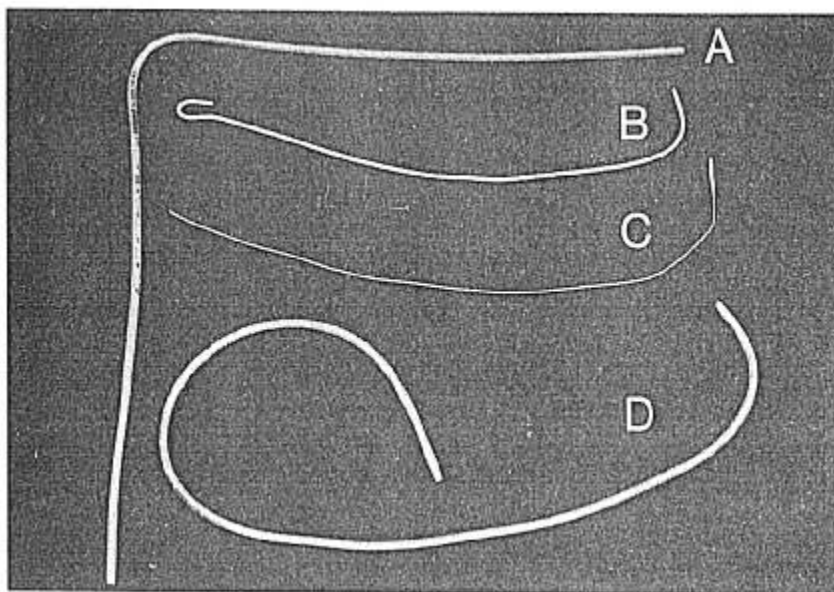
Difficulties in obtaining a suitable commercially manufactured intubating stylet led us to create our own from commercially available products. The first component of our device is marketed under the name of "Tracheal Tube Exchanger" (T.T.X.,<sup>TM</sup> Sheridan Catheter Corporation, Argyle, NY) (fig. 1A). The size

used is labeled "large—for sizes 7.5–10.0." The second component, a malleable wire with a plastic coating, is marketed by the same company under the name "Sheri-Slip<sup>TM</sup> Intubating Stylet" (SIS) (fig. 1B). As the T.T.X.<sup>TM</sup> is itself too flimsy to be effective as an intubating stylet, the SIS serves to provide the necessary stiffness.

Combining the SIS and the TTX<sup>TM</sup> to form an intubating stylet takes about 10 min. First, using a knife, strip all but 3 cm of the plastic coating from the SIS (fig. 1C). Next, slide the exposed wire of the SIS into the lumen of the T.T.X.<sup>TM</sup> until the plastic plug at the end of the SIS abutts the orifice of the T.T.X.<sup>TM</sup> Lubricate the plastic plug with an alcohol swab and drive it into the lumen until the tips are flush (fig. 1D). The tight fit of the plug into the lumen makes dislodgement of the inner wire virtually impossible.

The intubating stylet can be gas sterilized and stored at intubating locations or carried coiled in a pocket. As

FIG. 1. Intubating stylet. A. Tracheal Tube Exchanger T.T.X.<sup>TM</sup> B. Sher-i-Slip<sup>TM</sup> stylet before and after (C) removal of all but 3 cm of plastic coating, and completed intubation stylet (D).



the inner wire is shorter than the T.T.X.,<sup>TM</sup> the malleable end functions as an intubating stylet, while the pliable end can be used as an endotracheal tube exchanger following the technique described by Finucane and Kupshik.<sup>4</sup> The intubating stylet is potentially life saving in a difficult intubation. It is inexpensive, pocket portable, and easily constructed from readily available materials.

KEITH H. BERGE, M.D.  
*Resident in Anesthesiology  
Mayo Graduate School of Medicine*

RONALD J. FAUST, M.D.  
*Assistant Professor of Anesthesiology  
Mayo Medical School*

*Department of Anesthesiology  
Mayo Clinic  
Rochester, Minnesota 55905*

#### REFERENCES

1. Bedger RC, Chang J: A jet-stylet endotracheal catheter for difficult airway management. *ANESTHESIOLOGY* 66:221-223, 1987
2. Aro L, Takki S, Aromaa U: Technique for difficult intubation. *Br J Anaesth* 43:1081-1083, 1971
3. Tahir AH, Renegar OJ: A stylet for difficult orotracheal intubation. *ANESTHESIOLOGY* 39:337-339, 1973
4. Finucane BT, Kupshik HL: A flexible stilette for replacing damaged tracheal tubes. *Can Anaesth Soc J* 25:153-154, 1978

*(Accepted for publication January 10, 1988.)*

Anesthesiology  
68:811-812, 1988

### Make a Difficult Intubation Simple

*To the Editor:*—Difficult tracheal intubation due to inability to visualize the glottis is occasionally encountered in anesthesia practice. Techniques for managing this situation are well described.<sup>1</sup> Despite visualization of the vocal cords, difficulty in inserting the endotracheal tube may still occur, because of a very narrow anatomical corridor. Contributing factors include missing teeth, TMJ dysfunction, oropharyngeal masses,

thick tongue, or soft tissue edema.<sup>1</sup> This is a particularly frustrating situation that may lead to persistent attempts to forcibly place the endotracheal tube. Tissue trauma, bleeding, cuff leak, and dental injury may result.

We have inserted oral endotracheal tubes successfully in this situation by using an Argyle Aero-Flo<sup>TM</sup> Tip suction catheter as a stylet. Under direct vision, the or-