

Although  $PtcCO_2$  is an accurate estimate of  $PaCO_2$  (fig. 4),  $PtcCO_2$  monitoring during anesthesia is sometimes impractical. Factors that limit its intraoperative use include the relatively long calibration and stabilization periods, the need to change the sensor site every 2–4 h, and the difficulty in finding a site for the sensor away from the surgical field in the small premature neonate who requires numerous monitors. In the intensive care unit,  $PtcCO_2$  is more commonly used because it is accurate during the acute phase of respiratory disease. However,  $PetCO_2$  remains an alternative site of monitoring in those neonates with less severe disease.

In conclusion, we found that, in the critically ill neonate with mild to moderate lung disease, both distal  $PetCO_2$  and  $PtcCO_2$  more accurately approximate  $PaCO_2$  than proximal  $PetCO_2$ . However, in the neonate with severe lung disease,  $PtcCO_2$  is the more accurate estimate of  $PaCO_2$ .

The authors wish to thank Mr. George Volgyesi, P.Eng., for his technical advice and assistance, and Ms. Terri Cain and Ms. S. L. Loo for their assistance in preparing this manuscript.

#### REFERENCES

- Hansen TN, Tooley WH: Skin surface carbon dioxide tension in sick infants. *Pediatrics* 64:942–945, 1979
- Fisher DM, Swedlow DB: Estimating  $PaCO_2$  by end-tidal gas sampling in children. *Crit Care Med* 9:287A, 1981
- Eberhard P, Mindt TW, Schafer R: Methodologic aspects of cutaneous  $pCO_2$  monitoring. *Intensive Care Med* 7:249–250, 1981
- Meny RG, Bhat AM, Aranas E: Mass spectrometer monitoring of expired carbon dioxide in critically ill neonates. *Crit Care Med* 13:1064–1066, 1985
- Schieber RA, Namnoum A, Sugden A, Saville AL, Orr RA: Accuracy of expiratory carbon dioxide measurements using the coaxial and circle breathing circuits in small subjects. *J Clin Mon* 1:149–155, 1985
- Epstein MF, Cohen AR, Feldman HA, Raemer DB: Estimation of  $PaCO_2$  by two noninvasive methods in the critically ill newborn infant. *J Pediatr* 106:282–286, 1985
- Badgwell JM, McLeod ME, Lerman J, Creighton RE: End-tidal  $PCO_2$  measurements sampled at the distal and proximal ends of the endotracheal tube in infants and children. *Anesth Analg* 66:959–964, 1987
- Chu J, Clements JA, Cotton EK, Klaus MH, Sweet AY, Tooley WH: Neonatal pulmonary ischaemia. Part I: Clinical and physiological studies. *Pediatrics* 40:709–782, 1967
- Schena J, Thompson J, Crone RK: Mechanical influences on the capnogram. *Crit Care Med* 12:672–674, 1984
- Dumpit FM, Brady JP: A simple technique for measuring alveolar  $CO_2$  in infants. *J Appl Physiol* 45:648–650, 1978
- McCann EM, Lewis K, Deming DD, Donovan MJ, Brady JP: Controlled trial of furosemide therapy in infants with chronic lung disease. *J Pediatr* 106:957–962, 1985
- Morton WD: Three-breath determination of cardiac output in infants and children (abstract). *ANESTHESIOLOGY* 67:A486, 1987
- McCann EM, Goldman SL, Brady JP: Pulmonary function in the sick newborn infant. *Pediatr Res* 21:313–325, 1987

Anesthesiology  
69:116–119, 1988

## Anesthesia for Cerebral Aneurysm Surgery: Use of Induced Hypertension in Patients with Symptomatic Vasospasm

MARK R. BUCKLAND, M.B., B.S., F.F.A.R.A.C.S.,\* H. HUNT BATJER, M.D.,† A. H. GIESECKE, M.D.‡

There are approximately 25,000 cases per year of aneurysmal subarachnoid hemorrhage (SAH) in the United States. Despite modern neurosurgical and neu-

roanesthetic techniques, the outlook for patients suffering SAH remains bleak. Twenty percent of these patients die before reaching hospital, and another 30% die in the ensuing days and weeks.<sup>1</sup> About 80% of patients admitted to neurosurgical centers in the recent Cooperative Aneurysm Study were initially in good condition, but only 56% had favorable outcomes, despite current medical therapy.<sup>2</sup> Symptomatic vasospasm was the most common cause of death and disability for patients surviving the initial hemorrhage and reaching neurosurgical care.<sup>3</sup>

Angiographic vasospasm occurs in 40–70% of patients presenting for treatment.<sup>3</sup> Clinical vasospasm, the syndrome of ischemic consequences of cerebral arterial narrowing, parallels the time course for that of angiographic vasospasm, but only produces ischemic symp-

\* Visiting Assistant Professor, Department of Anesthesiology.  
† Assistant Professor, Department of Surgery, Division of Neurological Surgery.

‡ Professor and Chairman, Department of Anesthesiology.

Received from the Department of Anesthesiology and the Department of Surgery, Division of Neurological Surgery, University of Texas Health Science Center at Dallas, Dallas, Texas. Accepted for publication January 26, 1988.

Address reprint requests to Dr. Batjer: Division of Neurological Surgery, University of Texas, 5323 Harry Hines Boulevard, Dallas, Texas 75235.

Key words: Anesthesia; neurosurgical. Anesthetic technique: hypertension; induced.

toms in 20–30% of patients.<sup>3</sup> Since the peak incidence of angiographic spasm and clinical ischemia is approximately day 7 post-SAH,<sup>3</sup> intraoperative consideration of cerebral perfusion is of paramount importance when surgery is planned late in the first week or early in the second week post-SAH. The most effective method for improving regional hemodynamics and reversing neurological deficits has been induced hypertension and hypervolemia.<sup>1,3</sup>

Several clinical situations may preclude the use of this effective technique. Coexistent cerebral aneurysms occur in 15–30% of patients with SAH.<sup>1</sup> Induced hypertension may place unsecured aneurysms at risk. In addition, patients with significant cardiovascular disease may not be candidates for aggressive hypertensive and hypervolemic therapy.

A primary goal of the anesthetic management of patients undergoing craniotomy for cerebral aneurysm surgery is to prevent rupture or rerupture of the aneurysm by careful maintenance of its transmural pressure. Induced hypotension is often used to aid in this transmural pressure control.<sup>4,5</sup> It can, however, pose a high risk of cerebral infarction if used in the first few days after SAH in patients with underlying arterial narrowing due to vasospasm, disrupted cerebral autoregulation, and impaired perfusion reserve, even if not clinically evident. While the exact risk of infarction in this setting is not known, many patients with angiographic spasm awaken with new deficits not attributable to sacrifice of vascular structures.

Two recent cases in which cerebral aneurysms were clipped to eliminate the risk of rebleeding using induced hypertension as part of the anesthetic technique to continue treatment of ischemic symptoms of vasospasm are described.

#### CASE REPORTS

*Case 1.* A 45-yr-old woman was transferred to this institution 5 days post-SAH. Clinically, she was mildly dysphasic and lethargic (Hunt-Hess grade III). Prior angiography and computerized tomography (CT) scan revealed a left middle cerebral artery bifurcation aneurysm and subarachnoid blood. Arterial blood pressure on admission was 90–100/60 mmHg and heart rate was 60 bpm. Crystalloids and colloids (5% plasma protein fraction) were infused sufficient to increase central venous pressure (CVP) from zero to 13 mmHg. Despite this therapy, 12 h after admission, she became hemiplegic on the right and globally aphasic. An iv infusion of dopamine was commenced in the intensive care unit (ICU) and titrated to increase systolic internal blood pressure to 150–160 mmHg with complete resolution of her neurological deficit. A decision was made to perform a craniotomy and secure her aneurysm, maintaining arterial blood pressure in this range. In the operating room, an arterial line was inserted under local anesthesia, and both arterial and central venous pressures were monitored continuously. After breathing oxygen, anesthesia was induced with thiopental 350 mg iv, fentanyl 500 µg iv, and vecuronium 8 mg iv. The iv infusion of dopamine, initially running at 9.5 µg · kg<sup>-1</sup> · min<sup>-1</sup>, was

continued. Maintenance of anesthesia consisted of 0.5–1% isoflurane, in air and oxygen, with iv pancuronium for muscle relaxation. End tidal CO<sub>2</sub> was kept at 24–28 mmHg, and both mannitol and dexamethasone were given iv. CVP was maintained in the range 10–12 mmHg, and systolic arterial blood pressure, except during the actual application of the aneurysm clip, at greater than 150 mmHg. For 2 min, during clipping, the systolic blood pressure was allowed to decrease to 130 mmHg. Postoperatively, she was neurologically unchanged, and was returned to the intensive care unit (ICU), still receiving the dopamine infusion. This was continued for 4.5 days postoperatively to maintain her blood pressure in the range 150–170 mmHg, after which it was possible to gradually terminate the vasoactive infusion without deterioration in her clinical status.

*Case 2.* A 34-yr-old woman in her 31st week of pregnancy presented to the hospital with a sudden onset of headache and meningismus without loss of consciousness. Neurological examination was normal, arterial blood pressure was 120/70 mmHg, and central venous pressure (CVP) was 18 cm H<sub>2</sub>O. Computerized tomography (CT) scan revealed subarachnoid blood in the right sylvian fissure and carotid cistern. Angiography showed right posterior communicating and anterior choroidal artery aneurysms, as well as a left internal carotid artery posterior communicating aneurysm. On the day following the SAH, the obstetrician and neurosurgeon decided that the best management approach was combined clipping of her symptomatic right sided aneurysms, followed by cesarean section delivery of the infant. This was accomplished without major consequence, with the aneurysms being clipped and a male infant of 2300 gm delivered. During the procedure, systolic blood pressure was kept at or greater than 110 mmHg and fetal heart monitoring performed. Postoperatively, her course was initially uneventful. On post-SAH day 13, she developed acute left upper limb weakness, and decreased level of consciousness associated with a fall in central venous pressure (CVP) to 4–5 cm H<sub>2</sub>O. Computerized tomography (CT) scan failed to demonstrate evidence of infarction. She was taken to the intensive care unit (ICU), and, after insertion of a pulmonary artery catheter, was treated with colloids and crystalloids iv and hypertension induced by an iv dopamine infusion. With an arterial blood pressure of greater than 155 mmHg, her neurological deficit resolved. Concern was expressed about ongoing use of hypertensive therapy in a patient with an unprotected intracranial aneurysm, and a decision was made to gain surgical control of the left-sided lesion. She was taken to the OR that evening for surgery. Prior to induction of anesthesia, the arterial blood pressure was 190/80 mmHg, PCWP 4 mmHg, and heart rate 105 bpm, with dopamine infusion running at a rate of 10 µg · kg<sup>-1</sup> · min<sup>-1</sup>. After breathing oxygen, anesthesia was induced by titration of sufentanil 30 µg iv and thiopental 275 mg iv. Pancuronium 10 mg iv was then given. At no time during the sequence was the systolic blood pressure allowed to decrease below 150 mmHg, and infusion of phenylephrine 100 µg/ml was used to maintain arterial blood pressure. A bolus of thiopental 75 mg iv was given prior to endotracheal intubation, after which the systolic blood pressure increased to 170 mmHg. This sudden and dangerous elevation of blood pressure associated with noxious stimulation during dopamine administration might have been prevented by decreasing the rate of phenylephrine infusion immediately prior to tracheal intubation. Anesthesia was maintained with nitrous oxide 60% in oxygen and 0.4–0.5% isoflurane. Ventilation was controlled to keep end-tidal CO<sub>2</sub> at 25 mmHg, and the vasoactive infusions were maintained. Immediately prior to final dissection and clipping of the aneurysm, the arterial blood pressure was allowed to decrease to 130 mmHg to facilitate these maneuvers. In view of her clinically demonstrated poor tolerance of these pressures preoperatively, etomidate 13 mg iv was given in divided doses for potential cerebral protection.<sup>6</sup> Immediately after securing the aneurysm, the arterial blood pressure was brought back up to greater than 155–160 mmHg with additional

crystalloids, dopamine, and phenylephrine infusions. At the end of the procedure, muscle relaxation was reversed with neostigmine 4.0 mg iv and glycopyrrolate 0.8 mg iv. All anesthetics were discontinued, and the patient was awakened and found to be neurologically intact. She was transferred to the intensive care unit (ICU) maintaining a dopamine infusion to sustain arterial blood pressure. Her clinical condition remained stable provided her systolic blood pressure was greater than 160 mmHg. Each time her blood pressure decreased below that level, she developed focal neurological deficit. She showed an ongoing requirement for hypertensive and intravascular volume therapy, and repeat angiography 12 days after the second operation showed marked spasm of her proximal middle cerebral artery (fig. 1). After a further 10 days of continued therapy, the vasoactive agents were gradually terminated and the patient and her healthy infant were discharged.

### DISCUSSION

That cerebral vasospasm occurs post-SAH and is of major clinical importance is well established. Its pathogenesis is poorly understood. Little doubt exists that blood in the subarachnoid space is the stimulus for development of vasospasm, but the exact mechanism of arterial narrowing is unclear.<sup>3</sup> The development of an appropriate treatment for clinically significant vasospasm has been substantially limited by the lack of a reproducible animal model in which neurological deficits accompanied angiographic vasospasm. The ideal treatment for symptomatic vasospasm is obviously prevention or reversal of the vascular narrowing, and a large number of pharmacological and physical methods have been tried with variable success.<sup>1,3</sup> The other major direction in therapy has been the use of methods to improve regional perfusion in the ischemic territories and modification of the brain's tolerance to ischemia.<sup>1</sup>

Induced hypertension and hypervolemia has been the most effective method to date for improving regional hemodynamics and reversing neurological deficits. About 70% of deficits attributed to vasospasm can be reversed by this type of therapy.<sup>7</sup> However, in a number of clinical situations, the risk of this treatment may outweigh the potential benefits. Unsecured or coexistent aneurysms are likely of considerable risk of rupture in these circumstances. The other group placed at risk with this therapy are patients with significant cardiovascular disease. Increasing intravascular volume, vasopressors, and inotropes, with their associated increases in afterload, contractility, and preload, certainly have the potential to deleteriously affect the balance of myocardial oxygen supply and demand. Using this therapy in 58 patients with clinically significant, angiographically proven vasospasm, ten patients developed pulmonary edema, and one patient suffered myocardial infarction.<sup>7</sup> Its use certainly necessitates careful invasive hemodynamic monitoring in an intensive care setting.

Data collected at our institution during a period when

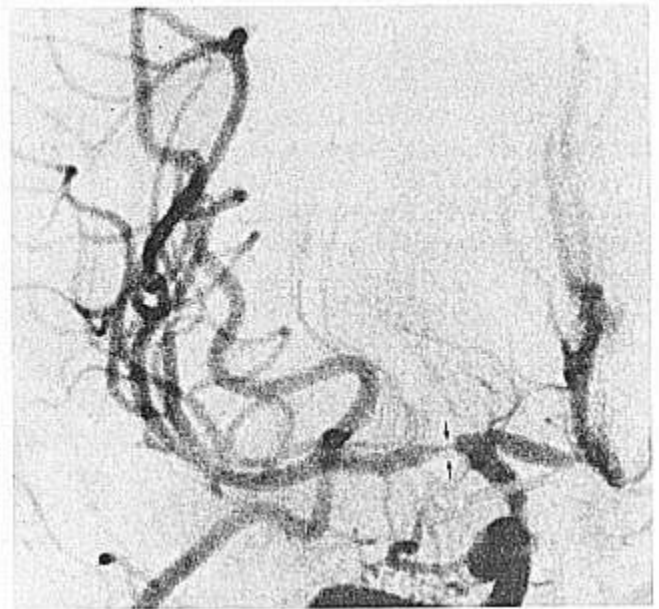


FIG. 1. Case 2. Postoperative right carotid angiogram (AP view) showing severe segmental spasm of proximal middle cerebral artery (arrowed). This study was obtained during induced hypertension 12 days after the second surgical procedure.

modest intraoperative hypotension was routinely used indicated that intraoperative rupture of a severity significant to interrupt the normal conduct of the dissection occurred in 19% of 307 consecutive aneurysm procedures.<sup>8</sup> It is likely that intraoperative rupture occurs with greater frequency when normal or elevated systolic blood pressures are maintained during subarachnoid dissection. Tremendous variability in the exact incidence of rupture would be expected due to varying complexity and size of aneurysms, the varying dissection techniques employed by neurosurgeons, and, finally, by the level of experience and skill of the individual surgeon.

In our two patients, the presence of primary unsecured, or coexistent unsecured, aneurysm made us reluctant to aggressively persist with induced hypertensive/hypervolemic therapy in the ischemic setting for a prolonged period, despite initially encouraging clinical response due to the risk of hemodynamic distention and rupture. The aneurysms were surgically secured in both cases while continuing with this treatment. The patients' hemodynamics could be maintained at their pre-anesthetic, non-symptomatic level. In both instances, this necessitated anesthesia and surgery at an arterial blood pressure greater than normal for the individual patient. Neither patient had any evidence of cardiovascular disease. In the first days after SAH, autoregulatory dysfunction is commonly observed.<sup>6</sup> Under these circumstances, cerebral perfusion becomes directly

linked to systemic arterial pressure. From a practical standpoint, at operation, it is possible to relieve turgor and pulsatility in subarachnoid conducting vessels and associated aneurysms by lowering arterial blood pressure. We did observe that, with the elevated systemic blood pressures reported in these cases, bounding subarachnoid vessels were encountered in the non-spastic segments. Using careful sharp microdissection, we felt that it was possible to operate relatively safely on the hyperdynamic cerebral vessels. Despite the anticipated brief interval of relative "hypotension" of 130 mmHg used in the second case, we felt that this preoperatively symptomatic level of blood pressure could potentially place the patient at risk for ischemic complications. Due to that concern, we empirically administered etomidate 0.2 mg/kg for potential cerebral protection. Recent encouraging experience in this institution with use of etomidate-induced burst-suppression for temporary arterial occlusion in the management of giant cerebral aneurysms supports this maneuver.<sup>6</sup> The marked cardiovascular stability and shorter elimination half-life of etomidate makes it an attractive agent for this use.<sup>9,10</sup>

In summary, the use of induced hypertension and hypervolemia as part of the anesthetic management of intracranial aneurysms is described. This technique may have a role to play in the management of a select group of patients suffering from symptomatic vasospasm after SAH, as part of the definitive surgery for their lesion and ongoing optimal medical therapy.

Anesthesiology  
69:119-122, 1988

## REFERENCES

1. Batjer HH, Samson DS: Use of extracranial-intracranial bypass in the management of symptomatic vasospasm. *Neurosurgery* 19:235-246, 1986
2. Kassel NF, Torner JC: The international cooperative study on timing of aneurysm surgery—An update. *Stroke* 15:566-570, 1984
3. Kassel NF, Sasaki T, Colohan ART, Nazar G: Cerebral vasospasm following aneurysmal subarachnoid hemorrhage. *Stroke* 16:562-572, 1985
4. Colley PS: Intracranial aneurysms—Anesthesia, *Handbook of Neuroanesthesia: Clinical and Physiological Essentials*. Edited by Newfield P, Cottrell J. Boston/Toronto, Little, Brown and Company, 1983, pp 183-206
5. Shapiro HM: Neurosurgical anesthesia and intracranial hypertension, *Anesthesia*, 2nd edition. Edited by Miller RD. New York, Churchill Livingstone, 1986, pp 1602-1604
6. Batjer HH, Frankfurt AI, Purdy PD, Smith SS, Samson DS: Use of etomidate, temporary arterial occlusion and intraoperative angiography in large and giant cerebral aneurysmal surgery. *J Neurosurg* 68:234-240, 1988
7. Kassel NF, Peerless SJ, Durward QJ, Beck DW, Drake CG, Adams HP: Treatment of ischemic deficits from vasospasm with intravascular volume expansion and induced arterial hypertension. *Neurosurgery* 11:337-343, 1982
8. Batjer H, Samson D: Intraoperative aneurysmal rupture: Incidence, outcome, and suggestions for surgical management. *Neurosurgery* 18:701-707, 1986
9. Milde LN, Milde JH: Preservation of cerebral metabolites by etomidate during incomplete cerebral ischemia in dogs. *ANESTHESIOLOGY* 65:272-277, 1986
10. Milde LN, Milde JH, Michenfelder JD: Cerebral functional, metabolic, and hemodynamic effects of etomidate in dogs. *ANESTHESIOLOGY* 63:371-377, 1985

## Unplanned Intraoperative and Postoperative Hemodilution: Oxygen Transport and Consumption during Severe Anemia

ALAN LICHTENSTEIN, M.D.,\* WILL F. ECKHART, M.D.,\* KAREN J. SWANSON, M.D.,\*  
CHARLES A. VACANTI, M.D.,† WARREN M. ZAPOL, M.D.‡

\* Clinical Fellow in Anesthesia, Harvard Medical School; Resident in Anesthesia, Massachusetts General Hospital.

† Instructor in Anesthesia, Harvard Medical School; Anesthetist, Massachusetts General Hospital.

‡ Professor of Anesthesia, Harvard Medical School; Anesthetist, Massachusetts General Hospital.

Received from the Department of Anaesthesia, Harvard Medical School, Boston, Massachusetts; and the Department of Anesthesia, Massachusetts General Hospital, Boston, Massachusetts. Accepted for publication January 26, 1988. Supported by NHLBI SCOR grant HL23591.

Address reprint requests to Dr. Lichtenstein: Department of Anesthesia, Massachusetts General Hospital, Boston, Massachusetts 02114.

Key words: Blood; anemia; hemodilution. Jehovah's Witness. Oxygen: delivery.

Treatment of unanticipated severe intraoperative blood loss in a patient who refuses blood transfusion presents a particularly difficult dilemma for the anesthesiologist. To effectively treat such a patient for a short time, oxygen delivery can be increased while minimizing oxygen consumption. Although others have described survival of anemic patients despite a low hematocrit,<sup>1</sup> our patient had hemodynamic variables and gas exchange measured with the help of a pulmonary artery catheter during severe anemia.

### REPORT OF A CASE

A 37-yr-old, 47-kg, Jehovah's Witness woman with a year-long history of Crohn's Disease was admitted for a small bowel resection and