

In summary, impaired neuromuscular activity assessed by TOF monitoring was found in 17 of 47 patients given pancuronium followed by its reversal during anesthesia. The frequency of impairment was reduced when the neuromuscular blocking drug was either atracurium, two of 46, or vecuronium, five of 57. It is recommended that rigorous neuromuscular monitoring is necessary to recognize the potentially dangerous persistent postoperative paralysis, especially if long-acting drugs are used.

REFERENCES

- Viby-Mogensen J, Jorgensen BC, Ording H: Residual curarization in the recovery room. *ANESTHESIOLOGY* 500:539-541, 1979
- Beemer GH, Rozental P: Postoperative neuromuscular function. *Anaesth Intensive Care* 14:41-45, 1986
- Fogdall RP, Miller RD: Neuromuscular effects of enflurane, alone and combined with d-tubocurarine, pancuronium, and succinylcholine in man. *ANESTHESIOLOGY* 42:173-178, 1975
- Miller RD, Way WL, Dolan WM, Stevens WC, Eger EI: Comparative neuromuscular effects of pancuronium, gallamine, and succinylcholine during forane and halothane anesthesia in man. *ANESTHESIOLOGY* 35:509-514, 1971
- Delisle S, Bevan DR: Impaired neostigmine antagonism of pancuronium during enflurane anaesthesia in man. *Br J Anaesth* 54:441-445, 1982
- Dernovoi B, Agoston S, Barvais L, Baurain M, Lefebvre R, d'Hollander A: Neostigmine antagonism of vecuronium paralysis during fentanyl, halothane, isoflurane, and enflurane anesthesia. *ANESTHESIOLOGY* 66:698-701, 1987
- Wallenstein S, Zucker LL, Fleiss JL: Some statistical methods useful in circulation research. *Circ Res* 47:1-9, 1982
- Gencarelli PJ, Miller RD: Antagonism of ORG NC45 (vecuronium) and pancuronium neuromuscular blockade by neostigmine. *Br J Anaesth* 54:53-56, 1982
- Stirt JA, Murray AL, Katz RC, Schehl DL, Lee C: Atracurium during halothane anesthesia in humans. *Anesth Analg* 62:207-210, 1983
- Williams A, Gyasi H, Melloni C, Bevan DR: Clinical experience with ORG NC45 (Norcuron) as the sole muscle relaxant. *Can Anaesth Soc J* 29:567-572, 1982
- Fahey MR, Morris RB, Miller RD, Sohn YJ, Cronnelly R, Gencarelli P: Clinical pharmacology of ORG NC45 (Norcuron). *ANESTHESIOLOGY* 55:6-11, 1981
- Smith CE, Donati F, Bevan DR: Potency of edrophonium and neostigmine as antagonists of atracurium and vecuronium. *Can J Anaesth* 24:S67, 1987
- Rupp SM, McChristian JW, Miller RD, Taboada JA, Cronnelly R: Neostigmine and edrophonium antagonism of varying intensity neuromuscular blockade induced by atracurium, pancuronium, or vecuronium. *ANESTHESIOLOGY* 64:711-717, 1986
- Lavery GC, Mirakhor RK, Gibson FM: A comparison of edrophonium and neostigmine for the antagonism of atracurium-induced neuromuscular block. *Anesth Analg* 64:867-870, 1985
- Donati F, Lahoud J, McCready D, Bevan DR: Neostigmine, pyridostigmine and edrophonium as antagonists of deep pancuronium blockade. *Can J Anaesth* 34:589-593, 1987
- Ali HH, Wilson RS, Savarese HH, Kitz RJ: The effect of tubocurarine on indirectly elicited train of four muscle response and respiratory measurements in humans. *Br J Anaesth* 47:570-574, 1975
- Donati F, Antzaka C, Bevan DR: Potency of pancuronium at the diaphragm and the adductor pollicis muscle in humans. *ANESTHESIOLOGY* 65:1-5, 1986
- Chauvin M, Lebrault C, Duvaldestin P: The neuromuscular blocking effect of vecuronium on the human diaphragm. *Anesth Analg* 66:117-122, 1987
- Laycock JRD, Donati F, Bevan DR: Potency of atracurium and vecuronium at the diaphragm and adductor pollicis muscle in humans. *Br J Anaesth* 59:1321P, 1987
- Pavlin EG, Holle R, Schoene R: Recovery of airway protection in humans after paralysis with curare. *ANESTHESIOLOGY* 57:A283, 1982
- Beecher HI, Todd DP: A study of deaths associated with anesthesia and surgery based on a study of 599,548 anesthetics in 10 institutions, 1948-1953 inclusive. *Ann Surg* 50:2-34, 1954
- Lunn JN, Hunter AR, Scott DB: Anaesthesia-related surgical mortality. *Anaesthesia* 38:1090-1096, 1983

Anesthesiology
69:276-279, 1988

Positioning the Air Aspiration Pulmonary Artery Catheter Introducer Sheath by Intravascular Electrocardiography

T. ANDREW BOWDLE, M.D., PH.D.,* ALAN A. ARTRU, M.D.†

* Assistant Professor, Departments of Anesthesiology and Pharmacetics.

† Associate Professor, Department of Anesthesiology.

Received from the Departments of Anesthesiology and Pharmacetics, University of Washington, School of Medicine, Seattle, Washington. Accepted for publication March 14, 1988.

Address reprint requests to Dr. Bowdle: Anesthesiology Service (112A), Veterans Administration Medical Center, 1660 South Columbian Way, Seattle, Washington 98108.

Key words: Embolism, air. Equipment, catheters: central venous; pulmonary artery. Heart, electrocardiography: intravascular.

Some anesthesiologists prefer a pulmonary artery catheter for monitoring during sitting neurosurgical procedures.¹⁻³ Pulmonary artery catheters provide information about circulatory dynamics, indicate when a right-to-left atrial pressure gradient exists (risk for arterial air embolism), and indicate when venous air embolism occurs. However, in the event of venous air embolism, the pulmonary artery catheter is not well suited for aspiration of large amounts of air from the right atrium, because of the small lumen of the atrial port. The inabil-

ity to aspirate large amounts of air *via* the atrial port of pulmonary artery catheters is a cause for concern because the survival rate following venous air embolism is higher when the majority of a large venous air embolus is retrieved than when only a small portion is retrieved.^{4,5} Therefore, we developed a special multi-orificed pulmonary artery catheter introducer sheath that provides an efficient pathway for air retrieval, while allowing simultaneous monitoring with a pulmonary artery catheter.⁵

This new air aspiration pulmonary artery catheter introducer sheath is long enough (25 cm) to reach the right atrium, and the last 5 cm of the sheath is perforated with 1-mm diameter holes. The size and spacing of these side holes are similar to that of the Bunegin-Albin air aspiration CVP catheter. This new introducer sheath was modeled after the Bunegin-Albin catheter, because the Bunegin-Albin catheter was previously reported to permit retrieval of a majority of a large venous air embolus and to improve survival rates following venous air embolism in anesthetized dogs.^{4,5} In sitting anesthetized dogs, this new introducer sheath retrieved an average of 69% of a 4-ml/kg venous air embolism, while only 16% was retrieved with a pulmonary artery catheter.⁵ Survival was significantly related to the amount of air removed.

One issue that has not been resolved with this new introducer sheath is that of positioning the distal tip relative to the right atrium. A previous study with the Bunegin-Albin catheter reported that the most efficient retrieval of venous air emboli occurred when the proximal orifice of the catheter was placed 1–3 cm above the junction of the right atrium and superior vena cava.⁶ Efficiency of retrieval fell dramatically if the proximal orifice of the catheter was moved 1–2 cm from the optimum position. One means for precise positioning of a catheter within the heart is by intravascular electrocardiography.⁷ However, the site of origin of the electrocardiographic complex from multi-orificed catheters is not entirely clear. Some authors have claimed that the ECG complex arises from the proximal orifice,^{8,9} while others have found that the ECG complex arises near the mid-point between the proximal orifice and the distal tip of the catheter.^{5,10} When the air aspiration pulmonary artery catheter introducer sheath was studied in dogs, post-mortem examination suggested that the ECG complex arose near the mid-point between the proximal orifice and the distal tip.⁵ We have now studied the electrocardiographic placement of the air aspiration pulmonary artery catheter introducer sheath in patients.

MATERIALS AND METHODS

The air aspiration pulmonary artery catheter introducer sheath (Cook Inc., Bloomington, IN) was placed

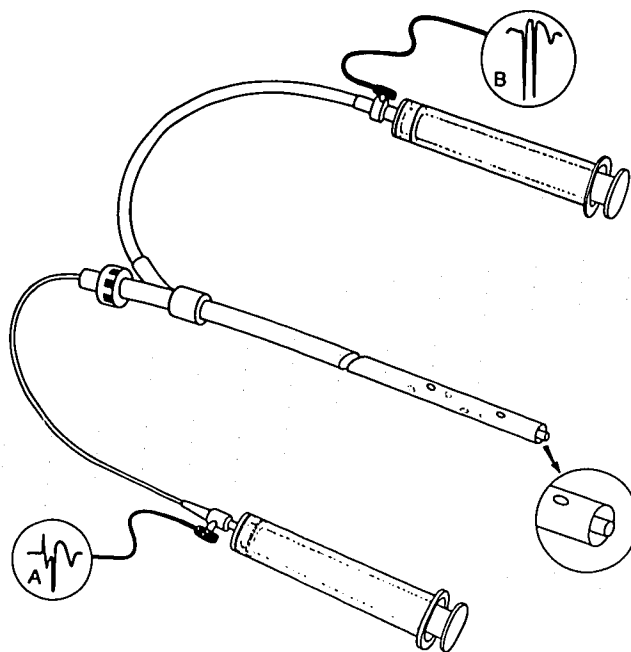


FIG. 1. The multi-orificed air aspiration pulmonary artery catheter introducer sheath is shown with a Sorenson CVP catheter placed in the lumen and protruding 1 mm beyond the tip of the introducer sheath. When the introducer sheath is positioned to record a large negative p-wave, a biphasic p-wave is recorded from the Sorenson catheter.

in six patients requiring pulmonary artery catheters as part of their anesthetic care. Informed consent was obtained. The sheath was inserted in the right internal jugular vein using the Seldinger technique and advanced about 12 cm. Blood was then aspirated through the side infusion port to remove air bubbles, and the side infusion port and the sheath were filled with sodium bicarbonate solution (1 meq/ml). An adapter for intravascular electrocardiography (Johans IVECG Adapter, Arrow International, Redding, PA) was attached to the side infusion port and the V lead of the ECG. The introducer sheath was slowly advanced while continuously recording the ECG. When the p-wave became negative and approximately the same size as the QRS complex, the introducer sheath was secured.

A Sorenson CVP catheter (15 gauge, Sorenson Research, Salt Lake City, UT) was filled with sodium bicarbonate, attached to the V lead of the ECG, and placed into the lumen of the introducer sheath (in the same manner as a pulmonary artery catheter). The Sorenson CVP catheter was advanced a measured distance, until the distal tip of the Sorenson catheter was 1 mm beyond the distal tip of the introducer sheath (fig. 1). The ECG complex deriving from the Sorenson catheter at that location was recorded and compared to the ECG complex deriving from the introducer sheath. The Sorenson CVP catheter was then slowly withdrawn until the ECG complex was identical to that recorded from

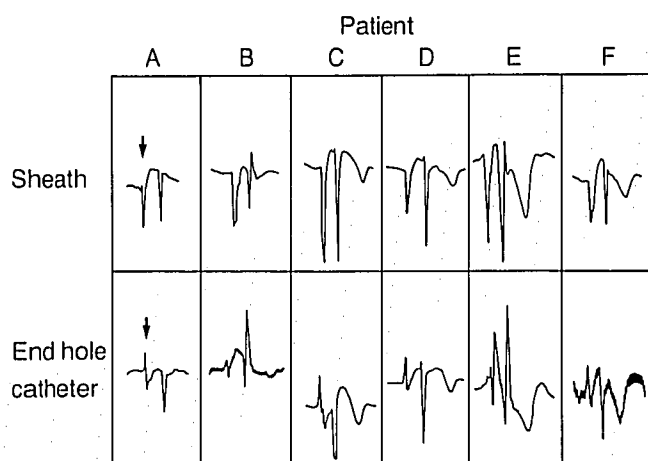


FIG. 2. The ECG complexes from six patients are shown, for the introducer sheath and the Sorenson CVP catheter, positioned as in figure 1. In column A, the p-waves are designated by arrows.

the introducer sheath. The distance the Sorenson CVP catheter was withdrawn indicated the point of origin of the introducer sheath ECG complex, as measured from the tip of the sheath.

RESULTS

The ECG complexes that were recorded from the introducer sheath, and the Sorenson CVP catheter, placed 1 mm past the end of the introducer sheath, are shown in figure 2. With the distal tips of the introducer sheath and the Sorenson catheter so positioned, the p-wave of the ECG complex from the introducer sheath was large and negative, while the p-wave of the ECG complex from the Sorenson catheter was biphasic. The distance between these two complexes, as determined by withdrawing the Sorenson CVP catheter until the ECG complex was identical to that from the introducer sheath, was 2.6 ± 0.13 cm (mean \pm SD).

DISCUSSION

Martin has studied the anatomical location of the intravascular ECG complex using a single-end-hole catheter and chest radiography.⁷ The biphasic p-wave corresponds to a mid-atrial location. When a catheter is withdrawn until the biphasic p-wave is transformed to a large negative p-wave, the catheter lays at the atrial-caval junction. Bunegin *et al.*⁶ examined the optimum position of single-orificed and multi-orificed catheters for retrieval of venous air emboli. Air aspiration was most efficient when the end-hole of the single-orificed catheter or the proximal orifice of the multi-orificed catheter was 1–3 cm above the junction of the right atrium and superior vena cava.⁶ These results were obtained *in vitro* using a human heart replica. Whether the

results apply *in vivo* is unknown. However, aspiration of catheters positioned according to their model have resulted in improved survival in dogs subjected to venous air embolism.^{4,5}

Therefore, our goal has been to place the multi-orificed sheath introducer so that the proximal orifice was above the atrial-caval junction. In our previous study of the air aspiration introducer sheath in dogs, we positioned the introducer sheath so that the p-wave of the ECG complex was large and negative. At post-mortem examination, the atrial-caval junction was in between the proximal orifice and the distal tip of the sheath, suggesting that the ECG complex arose from a point near the middle of the segment of sheath containing the side holes.⁵ We positioned introducer sheaths in patients in a similar fashion, to obtain a large negative p-wave. When so positioned, the distal tip of the introducer sheath was at the mid-atrial position, as indicated by the biphasic p-wave recorded from the Sorenson catheter. The point of origin of the ECG complex from the introducer sheath was approximately 2.6 cm proximal to the distal tip, as indicated by withdrawing the Sorenson catheter until the ECG complex from the CVP catheter and the introducer sheath were identical. This corresponds to approximately the mid-point of the 5-cm segment of sheath containing the side holes.

This result is in agreement with our study of dogs⁵ and another study that showed that the ECG complex recorded from Bunegin-Albin air aspiration CVP catheters originated at the mid-point of the distal segment containing side holes.¹⁰ Johans reported that the ECG complex from a custom-designed multi-orificed catheter originated at the proximal orifice.⁸ The reason for the difference in results is unclear, but may be related to the size of the side holes, relative to the sizes of the end hole and catheter lumen.¹⁰

There are risks associated with any invasive monitoring device. In particular, there is a theoretical risk of injury to the heart when a catheter, introducer sheath, or wire is placed within a cardiac chamber. The introducer sheath we have described should, therefore, be placed with due caution and only under electrocardiographic guidance. At the conclusion of a sitting neurosurgical procedure, when the need to aspirate air emboli is no longer present, we recommend that the sheath be withdrawn until the tip is outside of the right atrium. We further recommend that the sheath not be allowed to remain in the right atrium without a pulmonary artery catheter through the lumen. The presence of the pulmonary artery catheter prevents the abrupt end of the sheath from coming into direct contact with the atrium.

In summary, the air aspiration pulmonary artery catheter introducer sheath should be positioned elec-

trocardiographically to obtain a large, negative p-wave. When so positioned, the proximal orifice should be above the atrial-caval junction, and the distal tip should be near the mid right atrium.

REFERENCES

1. Munson ED, Paul WL, Perry JC, De Padua CB, Rhoton AL: Early detection of venous air embolism using a Swan-Ganz catheter. *ANESTHESIOLOGY* 42:223-226, 1975
2. Marshall WK, Bedford RF: Use of a pulmonary-artery catheter for detection and treatment of venous air embolism: A prospective study in man. *ANESTHESIOLOGY* 52:131-134, 1980
3. Rudehill A, Langerkranser M, Lindquist C, Gordon E: Effects of manitol on blood volume and central hemodynamics in patients undergoing cerebral aneurysm surgery. *Anesth Analg* 62:875-880, 1983
4. Artru AA, Colley PS: Bunegin-Albin catheter improves air retrieval and resuscitation from lethal air embolism in prone dogs. *Anesth Analg* 66:991-994, 1987
5. Bowdle TA, Artru AA: Treatment of air embolism with a special pulmonary artery catheter introducer sheath in sitting dogs. *ANESTHESIOLOGY* 68:107-110, 1988
6. Bunegin L, Albin MS, Hesel PE, Hoffman A, Hung T-K: Positioning the right atrial catheter: A model for reappraisal. *ANESTHESIOLOGY* 55:343-348, 1981
7. Martin JT: Neuroanesthetic adjuncts for surgery in the sitting position III. Intravascular electrocardiography. *Anesth Analg* 49:793-805, 1970
8. Johans TG: Multiorificed catheter placement with an intravascular electrocardiographic technique. *ANESTHESIOLOGY* 64:411-413, 1986
9. Warner DO, Cucchiara RY: Position of proximal orifice determines electrocardiogram recorded from multiorificed catheter. *ANESTHESIOLOGY* 65:235-236, 1986
10. Artru AA, Colley PS: The site of origin of the intravascular electrocardiogram recorded from multiorificed intravascular catheters. *ANESTHESIOLOGY*, in press

Anesthesiology
69:279-281, 1988

Difficulty in Endotracheal Intubation Due to Congenital Tracheal Stenosis: A Case Report

ZEYNEP ESENER, M.D.,* AYLÄ TÜR, M.D.,† BARIŞ DIREN, M.D.‡

Difficulty in endotracheal intubation is not uncommon, and can arise either from inability to visualize the larynx and/or from obstruction to the passage of the tracheal tube.¹ Difficulty in advancing the tube into the trachea after it has passed between the vocal cords is not common, and may be due to tracheal stenosis resulting from thyroid or mediastinal tumors, previous tracheostomy, prolonged intubation, or traumatic lesions.²⁻⁵ Congenital tracheal stenosis may also cause serious problems, but is usually seen in early childhood in patients presenting with respiratory difficulties.^{3,6} There is one report in which double lumen endobronchial tube placement was difficult due to congenital tracheal stenosis in the adult.⁷ We present a patient in whom we were unable to insert an endotracheal tube into the trachea. In this asymptomatic patient, a diagnosis of congenital tracheal stenosis was made based on bronchoscopy, tracheobronchography, and serial computerized tomographic (CT) scans.

* Professor of Anesthesiology.

† Assistant Professor of Anesthesiology.

‡ Assistant Professor of Radiology.

Received from the Departments of Anesthesiology and Radiology, Ondokuz Mayıs University Medical School, Samsun, Turkey. Accepted for publication March 16, 1988.

Address reprint requests to Dr. Esener: Department of Anesthesia, Ondokuz Mayıs University Medical School, PK 29-55001 Samsun, Turkey.

Key words: Intubation, endotracheal; congenital tracheal stenosis.

CASE REPORT

A 39-yr-old, 162 cm, 65 kg woman with cholelithiasis was scheduled for a cholecystectomy. Her medical history revealed no respiratory difficulties with daily activities, including climbing stairs and walking uphill, and she was not taking any medications. Preoperative chest radiography and routine laboratory findings were considered normal.

After receiving atropine 0.5 mg and meperidine 50 mg im, anesthesia was induced with thiopental, 400 mg iv, and succinylcholine, 100 mg iv. There was no difficulty in manually ventilating the lungs *via* a mask. The glottis was exposed by direct laryngoscopy, and a 34-Fr (OD 11.3 mm with cuff) endotracheal tube was inserted through the vocal cords with ease. However, the tip of the tube could not be advanced beyond approximately 2.5-3 cm distal from the vocal cords. The tube was withdrawn and smaller sizes were tried, but even a 28-Fr (9.3 mm OD) tube could not be advanced into the trachea, and the cuff was between the cords. Trying a smaller size was not considered appropriate at this stage, and the operation was postponed for further evaluation of the trachea. Manual ventilation was performed adequately until the neuromuscular blockade had been terminated.

Endoscopic examination, performed 2 days later, with a rigid bronchoscope (6.5 mm), revealed an annular stenosis starting 3 cm below the cords. This area was also slightly inflamed, probably due to the previous intubation attempts. The adult size bronchoscope, which was the narrowest of the adult range, could not be advanced further. The child size (3.5 mm) was passed through the narrow segment, and this segment was found to be approximately 3.5-4 cm in length and hour-glass shaped. The carina and main bronchi were normal up to the lower lobe openings. Anti-inflammatory treatment was started, and the patient was called back a week later.

Serial CT scans of the neck and mediastinum revealed a segmental narrowing of the tracheal lumen (10 mm in diameter) at the level of 1/3 median segment of trachea (between C6-7 intervertebral disk and upper level of T₂ vertebra). The cross-section of the trachea was circular along this segment (fig. 1). The transverse diameter of the tra-