

Anesthesiology
69:433, 1988

Malignant Hyperthermia and Sleep Apnea

To the Editor:—The types of surgical procedures most likely to be associated with masseter muscle rigidity (MMR) and/or malignant hyperthermia (MH) remain an unanswered question. It has, however, been reported that MH patients often demonstrate localized areas of muscle weakness or musculoskeletal abnormalities that may present as strabismus, hypermobile joints, spinal deformities, ptosis, club foot, and hernias.¹⁻³

We were recently involved in the anesthetic management of a 7-yr-old, 30-kg girl with a clinical diagnosis of obstructive sleep apnea (OSA) who presented for tonsillectomy and adenoidectomy on an ambulatory basis. There was no known family history of MH and the temporomandibular joints were normal. Anesthesia was induced with N₂O/O₂ and halothane by facemask and, once she was unconscious, succinylcholine, 1.5 mg/kg iv, was administered. Some 30 s later, MMR was noted. The patient was hyperventilated with 100% O₂ by mask using a new Jackson Rees Circuit connected to an oxygen tank. Heart rate increased from 115 to 205 bpm and axillary temperature rose from 35.7 to 36.7° C over 10 min. pH_a was 7.18, PaCO₂ 53 mmHg, PaO₂ 99 mmHg, and base excess -9.0 mEq/l. The patient was cooled, hyperventilated with 100% oxygen, and an iv bolus of dantrolene was administered. The patient went on to develop hemoglobinuria and myoglobinuria during the recovery period. Her CPK rose from 30,000 U/l (normal range 145 U/l) on the first postoperative day to a peak of 89,000 U/l on the following day and she complained of severe myalgias. She made an uneventful recovery and was discharged from the hospital 4 days later with a clinical diagnosis of MH.

The obstructive element in the OSA syndrome may be due to an imbalance between airway constricting and airway dilating pharyngeal muscle forces.^{4,5} This situation is perhaps analogous to those producing strabismus, scoliosis, etc.^{1,2} The occurrence of both OSA and MH in our patient raises the possibility of an association between MH susceptibility and OSA. While "one swallow doesn't make a summer," and a chance association between the two conditions may be the most likely explanation, closer observation of OSA patients in the future may disclose the strength of any association of MH with OSA. We

would be interested in hearing from any other anesthesiologists who might have encountered a similar concurrence of conditions.

NATHAN SCHWARTZ, M.D.
*Assistant Professor of Anesthesiology
and Pediatrics*

JAMES B. EISENKRAFT, M.D.
Associate Professor of Anesthesiology

*Department of Anesthesiology
Mount Sinai School of Medicine
One Gustave L. Levy Place
New York, New York 10029-6574*

REFERENCES

1. Britt BA: Malignant hyperthermia. *Can Anaesth Soc J* 32:666-677, 1985
2. Lewandowsky KB: Strabismus as a possible sign of subclinical muscular dystrophy predisposing to rhabdomyolysis and myoglobinuria. *Can Anaesth Soc J* 29:372-376, 1982
3. Carroll JB: Increased incidence of masseter muscle spasm in children with strabismus anesthetized with halothane and succinylcholine. *ANESTHESIOLOGY* 67:559-561, 1987
4. Saverland EK, Harper RM: The human tongue during sleep: Electromyographic activity of the genioglossus muscle. *Exp Neurol* 51:160-170, 1976
5. Brovillette R, Thach RA: Neuromuscular mechanisms maintaining extrathoracic airway patency. *J App Physiol* 46:772-779, 1979

(Accepted for publication May 10, 1988.)

Anesthesiology
69:433-434, 1988

Hypoglycemia Associated with Supraventricular Tachycardia in an Infant

To the Editor:—In pediatric patients, if dextrose-containing solution is the only intraoperative fluid infused iv, the amount necessary to maintain cardiovascular stability during use of a potent inhalational anesthetic invariably results in hyperglycemia.¹ On the other hand, withholding glucose intraoperatively could result in hypoglycemia.*

* White SE, Brown SE, Frison LM: Hypoglycemia associated with supraventricular tachycardia in an infant. *ANESTHESIOLOGY*, in press

Our solution is to infuse 5% dextrose in lactated Ringer's (D₅LR) iv at a maintenance rate providing 6 mg/kg/min of glucose.² Then, we use bolus LR to maintain blood pressure and replace deficits and intraoperative losses.

The technique we use does not require two infusions for each patient. A Pharmaseal® K-52 Novex three-way stopcock and tubing are inserted directly into a bag of LR (fig. 1). Boluses can be withdrawn quickly and easily. The same bag can be used for subsequent patients without cross-contamination.

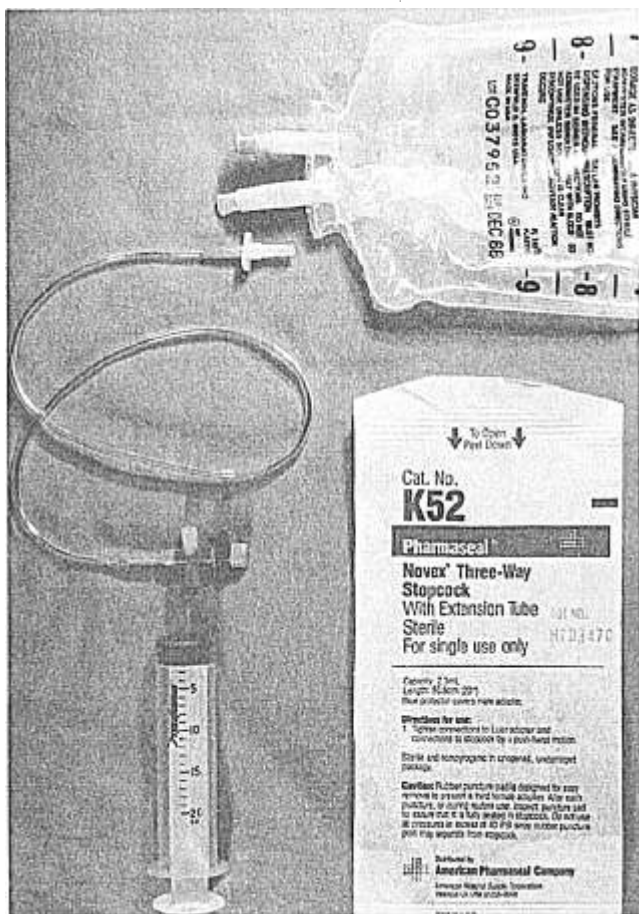


FIG. 1. Equipment for bolus administration.

Anesthesiology
69:434-435, 1988

Doppler-guided "Percutaneous" Radial Artery Cannulation in Small Children

To the Editor:—Percutaneous cannulation of the artery in small children requires considerable technical expertise. Compression of the artery reduces the blood flow and this reduction can be assessed using a Doppler blood flow detector; thus, the artery can be located. Murray *et al.*¹ cannulated the radial artery in small children by applying the Doppler technique. In their report, contact of the tip of the intravenous cannula with the artery was evidenced by changes in the Doppler tone while the cannula was advanced through the skin towards the artery. We attempted to use their method, but precise control of the position of the tip was not achieved and access to the artery seemed unreliable. The tip of the cannula should be freely movable when attempting to correct its direction toward the artery. For this purpose, a small skin incision and separation of subcutaneous tissue were performed and location of the artery was determined using the Doppler technique.

Twenty-eight children ranging in age from 1 day to 2 yr and scheduled for cardiovascular surgery were studied. In all patients being anesthetized, radial artery cannulation was required for intraoperative

If an additional K-52 tubing and stopcock are interpolated into the patient's primary iv setup, boluses can be administered to the patient without the use of a needle.

It is important to avoid both hyperglycemia and hypoglycemia. This system saves time and money and avoids needles. We have found it quite useful.

SNO E. WHITE, M.D.
Assistant Professor

STEVEN E. BROWN, M.D.
Assistant Professor

LISA M. FRISON, D.O.
Chief Resident

Anesthesia & Operative Service
Walter Reed Army Medical Center
Washington, DC 20307-5001

REFERENCES

1. Welborn LG, McGill WA, Hannalah RS, Nisselson CL, Ruttmann UE, Hicks JM: Perioperative blood glucose concentrations in pediatric outpatients. *ANESTHESIOLOGY* 65:543-547, 1986
2. Gregory GA: Monitoring during surgery, *Pediatric Anesthesia*. Edited by Gregory GA. New York, Churchill Livingstone, 1983, p 396

(Accepted for publication May 12, 1988.)

monitoring. The patient's hand and wrist were secured on an arm-board with the wrist slightly extended. A small Doppler probe (Hayashi Denki Co., Kawasaki, Japan) was placed on the skin over the radial artery proximal to the cannulation-planned point where the maximal pulsation was located on palpation. Under sterile conditions, the needle-tip of a 22-gauge cannula with a stylet (Medicut L-intravenous cannula, Nippon Sherwood Co., Tokyo) was placed on the skin surface. Gentle compression was then applied with the needle-tip while the Doppler tone was checked. The needle-tip was "walked" on the skin surface over the pulsation and the point where the Doppler tone showed a maximal decrease or disappearance was noted. Thus, the artery was located precisely in eight of 28 patients, without any invasive procedure. In the remaining 20, an incision 2-3 mm long was made above the pulsation and the subcutaneous tissue was separated with the tip of a forceps. Separation was performed beyond both margins of the artery. Arterial compression with a needle-tip was then repeated in the same manner used on the skin surface. Thus, the artery was located in 17 of the 20 patients. Overall, the artery was