

Anesthesiology
69:440, 1988

Injection Aid for "Tubex" Type Syringe

To the Editor:—Morphine sulfate, heparin, lorazepam, and oxytocin are commercially packaged in injectable syringes requiring an injection device or "tubex" to administer the drug iv or im. If no injector is available, drug injection can be difficult and frustrating. Various methods have been devised to push the rubber stopper through the syringe. These may consist of a long plastic needle cap, an intubating stylet, or other slender long object to fit inside the barrel of the drug syringe.

When a commercial injection device is unavailable, a simple and economical solution is to use the barrel of a 1 cc tuberculin syringe as a

"plunger" easily fitting into the barrel of the injectable syringe (fig. 1). The tuberculin syringe tip can also be twisted onto the screw of the rubber stopper, allowing one to aspirate as needed for im injection.

ANTHONY L. KOVAC, M.D.
Department of Anesthesiology
University of Kansas Medical Center
Kansas City, Kansas 66103

(Accepted for publication June 2, 1988.)

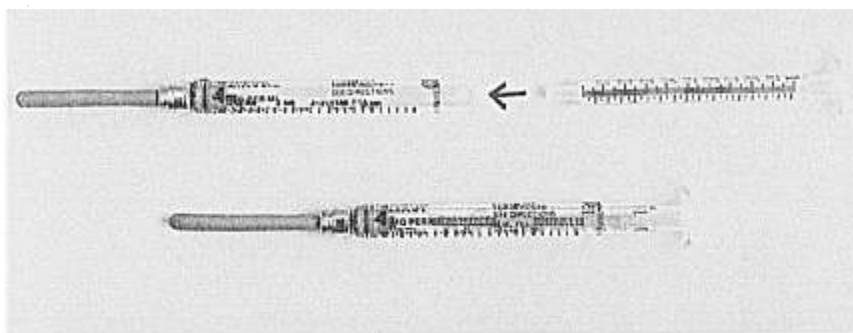


FIG. 1. One cc tuberculin syringe inserted into barrel of injectable syringe.

Anesthesiology
69:440, 1988

Electrical Erythema?

To the Editor:—We read with interest the article by Meyer *et al.*, which discussed the determination of spinal level using neuromuscular stimulation.¹ This method of assessment has been used with success at our institution with noncommunicative patients and we present an interesting complication using this technique.

A 65-yr-old, ASA physical status 3 man scheduled for transurethral resection of vesicle neck contracture received a spinal anesthetic using 50 mg hyperbaric lidocaine and 0.2 mg epinephrine. A test of the level of spinal anesthesia was performed over the right lateral abdomen and chest wall. Using the "Micro-Stim" peripheral nerve stimulator (neuro technology, Houston, Texas) with the ball probe electrodes. A sensory level of T6 was elicited. Within minutes, a linear series of erythematous macules appeared over the area of stimulation. The lesions became more prominent over the following 5 min, and then faded slowly during the subsequent 45 min. To confirm our suspicions of the lesions' etiology, we stimulated the left lateral abdomen and obtained similar results. Exposure of the skin to the ball probes without stimulation did not produce erythematous lesions. The planned surgical procedure proceeded without incident and the patient was transported to PACU.

This patient had no history of allergies, erythemas, dermatographism, physical or cholinergic urticarias, nor other systemic diseases, (*e.g.*, neoplasm, reticulosis, or collagen disease), which have all been implicated in the past as provoking causes for the formation of similar lesions.

The etiologies of localized erythematous eruptions have been attributed to various physical stimuli, including trauma, heat, chemical irri-

tants, light, and cold.² Although we have not seen this form of macular erythema reported following electrical stimulation, we feel this is the etiology in this case.

ROBERT MYYRA, M.D.
Instructor of Anesthesiology

MARK DALPRA, M.D.
Instructor of Anesthesiology

JAY GLOBERSON, M.D.
Instructor of Anesthesiology

Department of Anesthesiology
University of Michigan Medical Center
Ann Arbor, Michigan 48109

REFERENCES

1. Meyer RM, McCune WJ: Assessing the level of spinal anesthesia using a neuromuscular stimulator. *ANESTHESIOLOGY* 67: 125-127, 1987
2. Champion RH: Disorders affecting small blood vessels: Erythema and telangiectasia, *Textbook of Dermatology*, 4th edition. Edited by Rook A, Parish LC, Beare JM. Boston, Blackwell Scientific Publications, 1986, p 1084

(Accepted for publication June 2, 1988.)