

Title : MONITORING OF BLOOD FLOW SUPPLYING ILEOCOLIC ESOPHAGOPLASTY IS AN EARLY PREDICTOR OF POSTOPERATIVE LOCAL ISCHEMIC COMPLICATIONS

Authors : O RABARY* MD; L JACOB* MD; S BOUDAOU* MD; D PAYEN** MD, PHD; D GOSSOT # MD ;
E SARFATI# MD ; B EURIN* MD;

Affiliation : * Department of Anesthesiology and Intensive Care ;
service de Chirurgie Générale ; Hôpital ST LOUIS, PARIS FRANCE.
**Department of Anesthesiology and Intensive Care. Hôpital Universitaire LARIBOISIÈRE

INTRODUCTION : Cervical anastomosis leakage or stenosis may compromise clinical outcome of retrosternal esophageal replacement by ileo-colic graft (1). More dramatic is the complete necrosis of the plasty which may involve the vital prognosis. Perioperative systemic or regional hemodynamic alterations are frequently suspected as a causal factor of such complications (2). In order to evaluate in man the role of these circulatory factors, mesenteric blood flow (MBF) supplying ileo-colic esophagoplasty was monitored with implantable Doppler microprobe (3).

MATERIAL AND METHODS : 8 patients (30 ± 5 yrs ± SD) were studied under mechanical ventilation (FIO₂ = 0.4) 3 hours after the surgical procedure. Written informed consent and local Ethical Committee approval were obtained prior to the study. No patient had any history of cardiovascular or respiratory disease. They were scheduled for esophageal replacement by retrosternal ileo-colic interposition several months after esogastric caustic burns.

Systemic hemodynamic parameters were measured or calculated via a Swan Ganz catheter and a radial artery catheter : right atrial pressure (RAP), cardiac output (CO), mean systemic arterial pressure (SAP).

Mesenteric blood flow study was conducted with a laboratory miniaturized implantable flow probe secured by resorbable sutures on the adventitia of the right superior colic artery (RSCA) at the end of the surgical procedure. Probe was linked to a 8 MHz pulsed Doppler apparatus by leads coming out of the abdomen through the skin. The probe was pulled out 3 days later by traction without any damage. The apparatus used provided the ability to measure vessel diameter (D) and mean cross sectional blood flow velocity (Vm) in cm.s⁻¹. MBF was calculated as follows : MBF = $\pi D^2/4 \cdot Vm$. 60 in ml.min⁻¹ (3).

Angiographic study in 6 patients, selective superior mesenteric artery computed angiography were systematically performed within 15 days after surgery to evaluate the patency of the right superior colic artery (RSCA) supplying exclusively the plasty.

Clinical follow up was assessed until the third month. Clinical results were appreciated on the presence or not of cervical fistula, dysphagia confirmed by endoscopic diagnosis of stenosis.

RESULTS : Immediate post-operative systemic and regional hemodynamic parameters are summarized in the table. (n = 8)

HR	SAP	CO	RAP	MBF
b.nm ⁻¹	mmHg	l.min ⁻¹	mmHg	ml.min ⁻¹
92 ± 7	94 ± 4	7.2 ± 0.6	7.5 ± 0.7	43 ± 14

One patient presented an hyperkinetic shock 24 hours after surgery leading to necrotic plasty removal. His previous MBF was null. 2 patients have presented within 1 month, important cervical anastomosis leakage and stenosis. Their post-operative MBF were low (28 and 24 ml.min⁻¹) and beat by beat analysis showed end systolic reverse flow. Angiographic control demonstrated the absence of flow above the carina. Whereas it was normal in the remaining 5 patients with good clinical outcome.

DISCUSSION : In this surgery it appears clearly that the postoperative monitoring of RSCA flow is an early predictive factor of local ischemic complication. In addition to the mean value of MBF, instantaneous flow patterns such as the presence or not of reverse flow have to be considered to evaluate the down stream resistances (4). In the future early and bedside detection of plasty ischemia might reduce the delay for surgical or medical treatment of these complications.

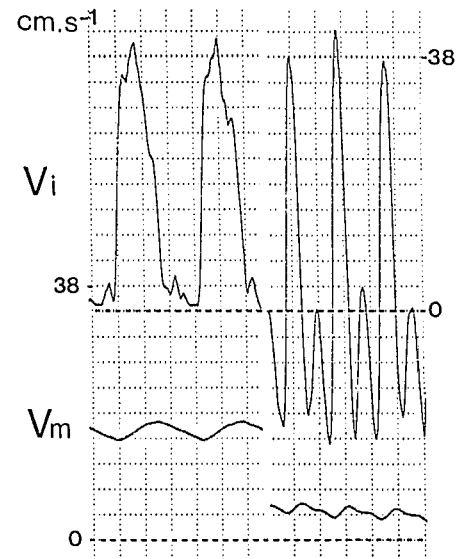


fig 1 : Instantaneous (Vi) and mean (Vm) blood flow velocity in two patients with typical reverse flow in the right.

REFERENCES :

- SARFATI E, GOSSOT D, ASSENS P, et al. Br J Surg 74, 146-148, 1987
- STONE M, MAHOUR G, WEITZMAN J, et al. Ann Surg, 203, 346-351, 1986
- PAYEN D, BOUSSEAU D, LABORDE F, et al. Circulation, 74 (Suppl III) 61-67, 1986
- TRUDINGER B, GILES W, COOK C, et al. Br J Obst Gynaecol, 92, 23-30, 1985.