

concentration of thiopental when the consciousness of the patients was clear; 2) both barbiturates and benzodiazepines, facilitate the GABA-ergic inhibition in the central nervous system,<sup>13</sup> and, therefore, benzodiazepines, administered pre- and/or intraoperatively, might have enhanced the effect of thiopental; 3) as Melzack suggested, patients had a higher pain threshold after the induction of phantom limb pain, because the increased output of the "pattern generating mechanism" could increase the descending inhibition;<sup>9</sup> and 4) phantom limb pain activated the sympathetic nervous system, which in turn enhanced the firing of the "pattern generating mechanism"<sup>8</sup> and reinforced the pain. Temporary effect of thiopental for the "pattern generating mechanism" abolished this vicious cycle.

As some authors have concluded, a history of lower limb amputation should be regarded as a contraindication to spinal anesthesia,<sup>4,5</sup> but one may have to choose spinal anesthesia for several practical reasons. When phantom limb pain occurs during spinal anesthesia, intravenous administration of subanesthetic dose of thiopental should be tried immediately.

The authors wish to thank Matsuo Matsushita, M.D., Ph.D., Professor of Anatomy, Institute of Basic Medical Sciences, University of Tsukuba, for his valuable suggestions on this manuscript; and Fujio Kaneko, M.D., Ph.D., Mito Saiseikai General Hospital, for his assistance with case presentation.

Anesthesiology  
69:600-602, 1988

## Spinal Anesthesia, Complete Heart Block, and the Precordial Chest Thump: An Unusual Complication and a Unique Resuscitation

WILLIAM L. CHESTER, M.D.\*

High spinal anesthesia (*i.e.*, above the fifth thoracic dermatome) has been associated with bradycardia and hypotension.<sup>1</sup> The presumed etiology of this phenomenon is a relative preponderance of vagal tone resulting from

## REFERENCES

1. Harrison G: Phantom limb pain occurring during spinal analgesia. *Anaesthesia* 6:114-116, 1951
2. Leatherdale RAL: Phantom limb pain associated with spinal analgesia. *Anaesthesia* 11:249-251, 1956
3. Davis T: Spinal analgesia. *ANESTHESIOLOGY* 19:682-683, 1958
4. Mackenzie N: Phantom limb pain during spinal anaesthesia. *Anaesthesia* 38:886-887, 1983
5. Sellick BC: Phantom limb pain and spinal anesthesia. *ANESTHESIOLOGY* 62:801-802, 1985
6. Moore B: Pain in an amputation stump associated with spinal anesthesia. *Med J Aust* 2:645-646, 1946
7. Tasker RR, Organ LW, Hawrylyshyn P: Deafferentation and causalgia, Pain. Edited by Bonica JJ. New York, Raven Press, 1980, pp 305-329
8. Melzack R, Loeser JD: Phantom body pain in paraplegics: Evidence for a central "pattern generating mechanism" for pain. *Pain* 4: 195-210, 1978
9. Melzack R: Phantom limb pain. *ANESTHESIOLOGY* 35:409-419, 1971
10. Mihic DN, Pinkert E: Phantom limb pain during peridural anesthesia. *Pain* 11:269-272, 1981
11. de Jong RH, Cullen SC: Theoretical aspects of pain: Bizarre pain phenomena during low spinal anesthesia. *ANESTHESIOLOGY* 24: 628-635, 1963
12. White JC, Sweet WH: Pain: Its Mechanisms and Neurosurgical Control. Springfield, Charles C. Thomas, 1955, pp 81-91
13. Harvey SC: Hypnotics and sedatives, *The Pharmacological Basis of Therapeutics*. Edited by Gilman AG, Goodman LS, Gilman A. New York, Macmillan, 1985, pp 339-371
14. Harvey SC: Hypnotics and sedatives, *The Pharmacological Basis of Therapeutics*. Edited by Gilman AG, Goodman LS, Gilman A. New York, Macmillan, 1980, pp 102-123

\* Assistant Professor of Anesthesiology, Uniformed Services University of the Health Sciences; and Staff Anesthesiologist, Bethesda Naval Hospital.

Received from the Uniformed Services University of the Health Sciences, Bethesda, Maryland; and the Department of Anesthesiology, Bethesda Naval Hospital, Bethesda, Maryland. Accepted for publication May 4, 1988.

Address reprint requests to Dr. Chester: Department of Anesthesiology, Bethesda Naval Hospital, Bethesda, Maryland 20814.

Key words: Anesthetic technique: spinal. Complication: complete heart block. Heart: precordial thump.

sympathetic blockade or, alternatively, from reflexes due to decreased atrial pressure (Bainbridge reflex). This is usually easily treated or prevented with vagolytic blockers such as atropine.

Although bradycardia and even asystole are well known complications of spinal anesthesia, third-degree heart block without ventricular escape has not been previously reported. We report a case during which complete heart block and ventricular asystole after a high bupivacaine spinal anesthetic was successfully treated by chest-thump induced pacing.

## REPORT OF A CASE

A 32-yr-old, 110-kg, 175-cm man was scheduled for repair of an uncomplicated ventral hernia. His past medical history, review of sys-

FIG. 1. Initial EKG (lead II) followed by third degree A-V block approximately 2 min after subarachnoid bupivacaine.

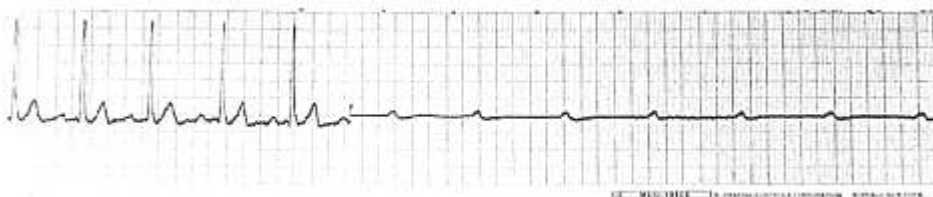
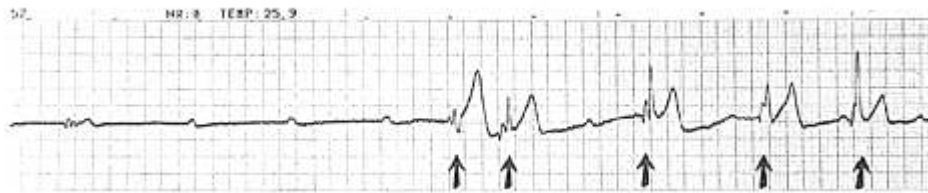

FIG. 2. Direct continuation of figure 1 showing third degree block followed by thump-induced QRS complexes (arrows).



tems, and physical examination were normal except for a 15 pack-year smoking history. Specifically, there was no history of heart disease or syncope episodes, and the patient was taking no medications. The complete blood count, electrolytes, and urinalysis were within normal limits. He was brought to the operating room with a 16-gauge iv and was monitored via a blood-pressure cuff, EKG, and pulse oximeter. After a 700-ml iv bolus of lactated Ringer's solution, arterial blood pressure was 140/88 mmHg; heart rate, 82 bpm (sinus rhythm); and respirations, 16 per minute. Fentanyl, 100  $\mu$ g, was given iv 10 min prior to starting the spinal anesthetic, and oxygen was administered at 6 l/min via nasal cannula. The patient was placed in the left lateral decubitus position, and a spinal block was administered at the L2-3 interspace with 2.0 ml (15 mg) of 0.75% bupivacaine in 8.25% dextrose. This dose of bupivacaine was chosen to achieve a T<sub>4</sub> level.

Approximately 2 min after being turned supine, the patient complained of nausea and tingling in his hands. He had loss of sensation to pinprick to C5-6 bilaterally. Within 15 s, he lost consciousness. No carotid pulse was palpable. The EKG showed P-waves at a rate of 60 bpm with no associated QRS complexes and no ventricular escape beats (fig. 1).

Ventilation was controlled with 100% oxygen and 1.2 mg atropine was injected intravenously. Simultaneously, in an attempt to initiate circulation prior to beginning formal cardiopulmonary resuscitation, repetitive precordial chest thumping was administered over the mid-sternum with mild force. This elicited ventricular QRS complexes, one per thump (fig. 2), and resulted in the patient's awakening. The patient asked why he was being subjected to this chest beating, at which point the thumping was stopped. The EKG at this point revealed persisting third degree A-V block with occasional supraventricular conduction (fig. 3), and again loss of consciousness resulted within 5-10 s. Chest thumping was again initiated; the patient again awakened and was told that this was needed to sustain his heart function. Shortly thereafter a sinus bradycardia ensued, followed by regular sinus rhythm, apparently as a result of circulation of the atropine. Arterial oxygen saturation was 91-94% prior to and after the arrest and resuscitation. No arterial blood pressure or heart rate measurements were taken during the resuscitation, which lasted approximately 3 min.

The remainder of the case proceeded uneventfully without the need for additional interventions, and the spinal level resolved gradually over 2 h. The patient was discharged 24 h later without neurologic or further cardiac complications.

#### DISCUSSION

Third degree A-V block has not been previously reported as a consequence of spinal anesthesia. Potential

causes for this dysrhythmia include intrinsic A-V nodal disease, hypotension-induced ischemia, coronary artery disease, and unopposed vagal tone due to spinal-induced sympathectomy, perhaps exacerbated by fentanyl premedication. This is a potentially lethal dysrhythmia that requires immediate intervention.

Chest thumping as a means of external cardiac pacing has extensive support in the literature.<sup>2-5,7,9</sup> Zoll *et al.* found that, in a series of ten patients, only 0.04-1.5 joules are needed to depolarize a responsive myocardium.<sup>2</sup> He successfully paced nine of the ten subjects using a 250-g, 1.34 cm<sup>2</sup> weight attached to a modified stapling gun. Scherf and Bornemann reported 11 cases of resuscitation from asystole by precordial thumping, one of whom was kept alive for 1 h solely by this means.<sup>3</sup> They also noted that the greater the duration of arrest or extent of myocardial damage, the greater the likelihood that thumping would lead to adverse ventricular rhythms or would be altogether unsuccessful. This was substantiated in a series of 316 patients reported by Caldwell *et al.* in 1985.<sup>4</sup>

The technique of precordial thumping for cardioversion, as described in the literature,<sup>4,8</sup> suggests delivering a sharp blow with moderate force over the mid-sternum beginning from a height of 15-20 cm. It should be emphasized that the force used to deliver a "pacing thump" is only 1/4-1/3 that which would be used by the author or other hospital staff for mechanical cardioversion. This was roughly estimated by having several CPR certified staff thump a bag of Ringer's solution connected to a transducer and comparing the peak pressures to those generated by "pacing thumps" delivered by the author to the same system.

There are some common analogies to the precordial thump that bear mentioning. The flick of a surgeon's finger against the ventricle is sometimes used to "pace" an asystolic heart after cardiopulmonary bypass. Ventricular extrasystoles are a frequent response to the mechanical pressure of cardiac catheterization. Pacinian corpuscles, muscle-stretch receptors, and carotid sinus pressorecep-

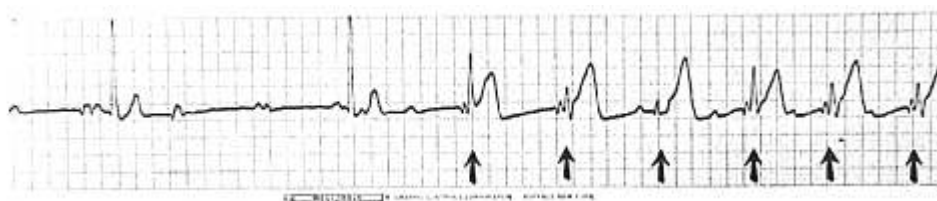

FIG. 3. Underlying rhythm after approximately 30 s of precordial thumping showing high grade A-V block with occasional supraventricular beats. Precordial thumping was resumed (arrows) again resulting in QRS complexes and patient awakening.

tors are examples of natural mechanoelectrical transducers. Coughing (which may generate 1–25 joules of energy<sup>5</sup>) has been successfully used by patients to pace or cardiovert themselves after asystole or ventricular tachycardia.<sup>6</sup>

The technique of precordial chest thumping has been used by this author and associates to temporarily pace severe sinus bradycardia or sinus arrest occurring at induction of anesthesia or during laryngoscopy. All such attempts resulted in successful temporary circulatory support until an adequate sinus rhythm was restored.

When compared to standard cardiopulmonary resuscitation and its attendant complications (rib fracture, liver laceration, myocardial and pulmonary contusions),<sup>8</sup> pacing by precordial chest thump appears to be a benign and effective initial means of resuscitation in witnessed bradycardic or asystolic arrest. The potential for inducing a more malignant rhythm with chest thumping has been reported to be as high as 44% when used without regard to duration or magnitude of cardiac dysfunction.<sup>9</sup> However, a closely monitored patient in an operating room is an ideal candidate for resuscitation by precordial chest thumping, should this become necessary. This means of

resuscitation should be considered early in the management of monitored asystolic or bradycardic arrest in the perioperative period.

#### REFERENCES

1. Wetstone DL, Wong KC: Sinus bradycardia and asystole during spinal anesthesia. *ANESTHESIOLOGY* 41(3):87–89, 1974
2. Zoll PM, Belgard AH, Weintraub MJ, Frank HA: External mechanical cardiac stimulation. *N Engl J Med* 294:1274–1275, 1976
3. Scherf D, Bornemann C: Thumping of the precordium in ventricular standstill. *Am J Cardiol* 5:30–40, 1960
4. Caldwell C, Millar G, Quinn E, Vincent R, Chamberlain DA: Simple mechanical methods for cardioversion: Defence of the precordial thump and cough version. *Br Med J* 291:627–630, 1985
5. Wei JY, Greene HL, Weisfeldt ML: Cough facilitated version of ventricular tachycardia. *Am J Cardiol* 45:174–176, 1980
6. Criley JM, Blaufuss AH, Kissel GL: Cough induced cardiac compression. *JAMA* 236:1246–1250, 1976
7. Pennington JE, Taylor J, Lown B: Chest thump for reverting ventricular tachycardia. *N Engl J Med* 283:1192–1195, 1970
8. Standards for Cardiopulmonary Resuscitation (CPR) and Emergency Cardiac Care (ECC). *JAMA* 227(suppl):837–868, 1974
9. Miller J, Tresch D, Horwitz L, Thompson BM, Aprahamian C, Darin JC: The precordial thump. *Ann Emerg Med* 13:791–794, 1984

Anesthesiology  
69:602–603, 1988

## Respiratory Artifact during Pulse Oximetry in Critically Ill Patients

JAMES SCHELLER, M.D.,\* ROBERT LOEB, M.D.†

Pulse oximetry is a valuable monitor,<sup>1–3</sup> but problems are associated with its use.<sup>4–7</sup> We report a case during which the pulse oximeter failed to detect the usual pulse

wave during mechanical ventilation with high peak inspiratory pressures, but did work when controlled ventilation was briefly interrupted.

#### REPORT OF A CASE

A previously healthy 22-yr-old man sustained trauma resulting in anoxic brain damage, bilateral hemothoraces, and multiple fractures. Massive transfusions of blood and crystalloid were required in the immediate resuscitation period. Bilateral chest tubes were placed prior to emergent abdominal exploration. The patient arrived in the operating room mechanically ventilated and comatose (Glasgow 4), with a sinus tachycardia, hypothermia (34.5° C), and an arterial blood pressure of 110/50 mmHg.

During surgery, a Siemens™ 900C anesthesia machine was used to control ventilation at a rate of 20 breaths per minute, a tidal volume

\* Resident in Anesthesiology.

† Assistant Professor of Anesthesiology.

Received from the Department of Anesthesiology, University of California, Davis Medical Center, Sacramento, California. Accepted for publication May 4, 1988.

Address reprint requests to Dr. Loeb: Department of Anesthesiology, UCD Professional Building, 4301 X Street, Sacramento, California 95817.

Key words: Monitoring: pulse oximetry. Ventilation: positive pressure.