

Postoperatively, a computerized axial tomography (CAT) scan (fig. 1) revealed a right posterior mediastinal cystic mass consistent with a bronchogenic cyst. The patient was brought to the operating room two days later for resection. Upon dissection the right vagus nerve was found to be adherent to the wall of the cyst (fig. 2) with the needle mark from prior aspiration visible nearby. The cyst communicated with the posterior tracheal wall several centimeters above the carina, and a pericardial patch was used to repair the tracheal defect.

The patient had an uneventful postoperative course. She was discharged one week later and is doing well.

DISCUSSION

Bronchogenic cysts are an unusual cause of stridor in the pediatric population. Most of the reported cases describe extrinsic compression of the tracheobronchial tree. Intrinsic obstruction by a bronchogenic cyst is exceedingly rare.

Preoperative diagnosis of a bronchogenic cyst can be difficult. A chest radiograph has been cited as the most useful diagnostic test¹; unfortunately, the cyst cannot always be visualized, as was the case in our patient. Even in retrospect, we were unable to identify the initial cyst on the chest radiograph taken prior to bronchoscopy. Erakus *et al.*² advocated a barium swallow for diagnostic purposes. This too was normal in our patient. Bronchogenic cysts should be considered in the differential diagnosis of congenital stridor.

Intraoperative bradycardia in infants is usually due to either hypoxemia or vagal output. The pulse oximeter in this case ruled out the former cause. The lack of effect

of two doses of atropine is unusual but not without explanation. Bradycardia in infants can markedly decrease cardiac output and increase circulation time. This can delay the onset of tachycardia following iv atropine.³ However, two minutes elapsed between the first dose of atropine and the administration of epinephrine. No increase in heart rate was seen during those two minutes. We attribute this refractory bradycardia to a marked increase in vagal activity. Aspiration of the intratracheal portion of the cyst most likely caused traction on the vagus nerve adherent to the wall of the cyst.

Chest compressions were not initiated in the operating room because the systolic blood pressure remained at 50 mmHg, the patient appeared well-perfused, and oxygen saturation registered 100% throughout the period of bradycardia.

In summary, we report a case of persistent bradycardia refractory to atropine, occurring presumably as a result of vagal stretching.

REFERENCES

1. Grafe WR, Goldsmith EL, Redo ST: Bronchogenic cysts of the mediastinum in children. *J Pediatr Surg* 1:384-392, 1966
2. Erakus AJ, Grescom NT, McGovern JB: Bronchogenic cysts of the mediastinum in infancy. *N Engl J Med* 281:1150-1155, 1969
3. Zimmerman G, Steward DJ: Bradycardia delays the onset of action of intravenous atropine in infants. *ANESTHESIOLOGY* 65:320-322, 1986

Anesthesiology
69:778-782, 1988

Effects of Radial Artery Cannulation on the Function of Finger Blood Pressure and Pulse Oximeter Monitors

TUULA S. KURKI, M.D.,* THEODORE J. SANFORD, JR., M.D.,† N. TY SMITH, M.D.,‡
HOLLIS DEC-SILVER, R.N., C.R.T.T.,§ NORMAN HEAD, B.S.§

* Staff Anesthesiologist, Department of Anesthesia, Helsinki University Central Hospital.

† Associate Clinical Professor of Anesthesiology, University of California, San Diego and Veterans Administration Hospital.

‡ Professor of Anesthesiology, University of California, San Diego, and Veterans Administration Hospital.

§ Research Assistant, University of California, San Diego and Veterans Administration Hospital.

Received from the Departments of Anesthesiology, University of California, San Diego and Veterans Administration Medical Center, San Diego, California; and the Department of Anesthesia, Helsinki University Central Hospital, 00290 Helsinki 29, Finland. Accepted for publication June 20, 1988. Supported in part by Ohmeda, Monitoring Systems, Englewood, Colorado.

Address reprint requests to Dr. Kurki: Department of Anesthesia, Helsinki University Central Hospital, Haartmaninkatu 4, SF-00290 Helsinki 29, Finland.

Key words: Doppler ultrasonic method. Monitoring. Noninvasive blood pressure measurement techniques. Pulse oximeter. Radial artery cannulation.

Indwelling radial artery cannulae are commonly used to continuously measure systemic blood pressure and provide information about blood gases, including hemoglobin oxygen saturation. It is also assumed that insertion of an arterial cannula can cause spasm and decreased blood flow distal to the cannula, although there are no reports as to the degree and duration of this assumed decrease in flow. In addition, percutaneous cannulation of the radial artery has known complications, including ischemic changes, bleeding, pseudoaneurysms, infection, and thrombosis.¹⁻¹¹ In an effort to avoid these and other complications, several noninvasive monitors have been introduced, including FinapresTM, a device to continuously measure blood pressure from a finger, and pulse oximeters to measure hemoglobin oxygen saturation.¹²⁻¹⁴ Both monitors rely on adequate peripheral blood

flow to function properly. During initial studies with the prototype FinapresTM to study its correlation with intraarterial blood pressure, it was noted that during, and for some time after, radial artery cannulation, the Finapres did not work.¹⁵ Also, the pulse oximeter signaled "no pulse." It was assumed that these monitors did not function properly because there was decreased distal blood flow caused by arterial cannulation. Based on these observations, a prospective study was designed to: 1) determine the incidence, degree, and time course of any changes in blood flow distal to the arterial cannula during and immediately after cannulation; 2) evaluate the impact of these changes on the noninvasive monitors, Finapres and pulse oximeter; 3) correlate the effects of multiple cannulation attempts on blood flow; and 4) determine whether or not patients taking oral vasodilator agents are protected from changes in distal blood flow during and after arterial cannulation.

MATERIALS AND METHODS

We studied 22 male patients scheduled for various surgical procedures, all of whom required continuous monitoring of blood pressure *via* an arterial cannula. The protocol was approved by the Human Subject's Committees of the University of California, San Diego, and the Veterans Administration Hospital, San Diego. All patients gave oral permission for this study.

Prior to cannulation, a modified Allen's test for occlusion of ulnar or radial arteries was performed on each patient.¹⁶ Only a hand with a normal Allen's test (*e.g.*, when the ulnar flush did not exceed 15 s) was selected for arterial cannulation. The following monitors were placed on the same hand as the artery to be cannulated.

A Doppler ultrasonic velocity meter (Model 91SL Parks, Electronics) to estimate blood velocity distal to the radial artery cannula, was placed along the course of the artery approximately 1 cm distal to the proposed puncture site. The signal from the Doppler audio output was processed by an RMS (root mean square) converter with an appropriate time constant so that a calibrated energy-related signal was obtained and recorded on a strip chart (Appendix).

A prototype finger blood pressure monitoring device was placed on the thumb of the hand chosen for cannulation. This noninvasive method for measuring blood pressure uses the arterial volume-clamp method described by Penaz in 1976, and further developed by Wesseling.^{12,13,17} Pulse pressure (FINAPP) was recorded for each patient.

A Nellcor Pulse Oximeter D-25 Oxisensor[®] was placed on the index finger. Oxygen saturation values (SaO₂) from the pulse oximeter were graphically recorded on a strip-chart recorder. This method is described by Yelderman and New.¹⁸

All data were recorded on a Hewlett-Packard[®] (Model 7788) strip-chart strip recorder as well as on a Vetter Model E FM tape recorder.

Prior to arterial cannulation, a 5-min steady-state period was recorded. Data were then recorded during and after cannulation until values returned to baseline—about 5–40 min. A cannulation attempt was defined as a "blind stick" rather than a failure to thread the cannula after arterial puncture. The cannulation technique included the following: a lidocaine skin wheal was performed with a 25-gauge needle; a 20-gauge Teflon nontapered catheter was inserted into the artery and the operators were instructed not to transfix the vessel but to attempt to enter the vessel by puncturing only the superior wall. Following successful cannulation, the anesthesiologist aspirated from the catheter to ascertain flow and then flushed the vessel with the dilute heparin solution. If the artery was punctured but the catheter could not be threaded, a 0.55-mm wire guide was used. All cannulations were monitored by one of the members of the research team.

RESULTS

The mean age of the patients was 62.1 yr, ranging from 48 to 76 yr. Six of 22 patients (27.2%) were ASA class II, 14/22 (63.6%) were ASA class III, and 2/22 (9%) were ASA class IV.

In 13/22 (59%) of patients, cannulation was successful on the first try. Of the remaining nine patients, two patients (patients 20 and 22) had at least five attempts before successful cannulation and three patients (patients 5, 18, and 19) required four attempts. Patient 4 required two attempts and patient 16 required three attempts. Arterial cannulation failed in two patients (patients 10 and 11) after five attempts on the primary hand, but was successful on the initial attempt on the alternate hand. A wire guide was used to facilitate arterial cannulation in patients 10 and 20.

We were able to collect complete data from the Doppler, FinapresTM, and pulse oximeter for 21 patients. Due to technical problems, we were not able to record the data from the Doppler for patient 1.

In all patients, when the cannula was inserted into the artery, there was a transient decrease in radial artery blood velocity distal to the cannula as indicated by the Doppler. The average maximal reduction in Doppler signal was 80% as compared with control values ($P \leq 0.001$). Nineteen patients had at least a 75% maximal reduction in Doppler measured blood velocity (fig. 1). In eight of these patients, Doppler-measured velocity decreased more than 90% after single cannulation attempts. The remaining three patients had multiple cannulation attempts. In the two patients (patients 10 and 11) in whom cannulation failed on the initial hand, cannulation was successful on the first attempt in the opposite hand. Blood velocity de-

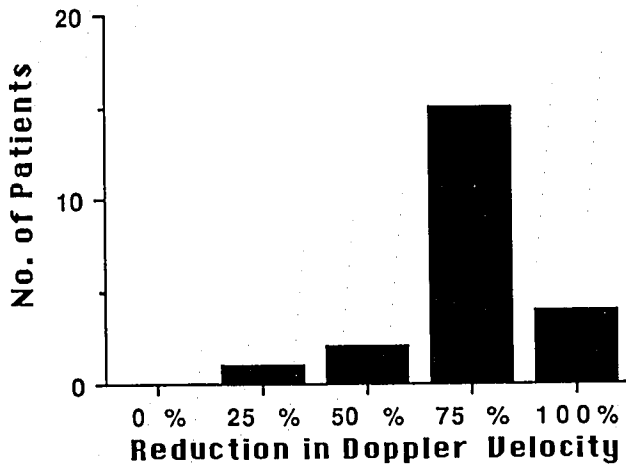


FIG. 1. The number of patients who had at least 25, 50, 75, or 100% reduction in Doppler measured velocity during arterial cannulation.

creased 80 and 95%, respectively, after successful cannulation of the opposite hand. In the two patients in whom a wire guide was needed, there was no significant difference in blood velocity decrease than the single attempt group.

After cannulation, the maximal mean reduction in Doppler measured velocity was 51% for all patients. The maximal Doppler reductions lasted 1–3 min before beginning a return to control. After cannulation, the majority of Doppler values returned to within 10% of control 1–4 min after cannulation.

FINAPP measured from the thumb decreased transiently in 72% of patients during arterial cannulation (fig. 2). The time course for these changes was also 1–4 min.

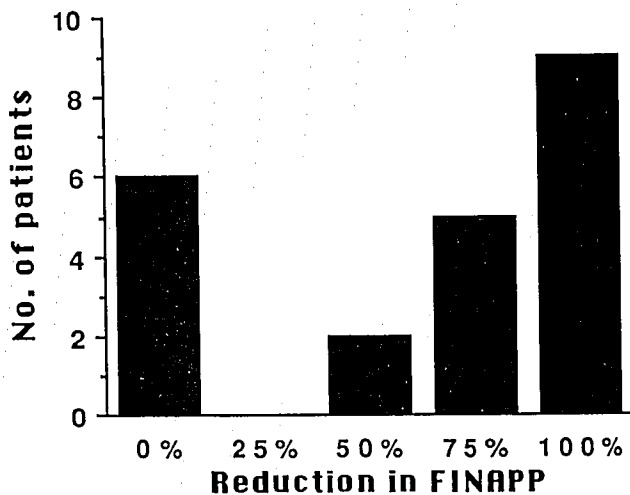


FIG. 2. The number of patients who had at least 25, 50, 75, or 100% reduction in FINAPP measured from the thumb during arterial cannulation.

FINAPP began to decrease when there was at least a 25% reduction in Doppler velocity. After cannulation, FINAPP was still decreased in 11/22 patients anywhere from 1–4 min before returning to at least control values.

SaO₂, as indicated by the pulse oximeter, was zero in four of the patients (patients 1, 3, 13, and 15) for 2–17 min during and after cannulation. In four additional patients (patients 2, 7, 11, and 12), SaO₂ was zero following the insertion of a cannula, but returned to control within 1 min.

In patients 1, 7, 13, and 17, in whom no radial artery blood flow distal to the cannula could be detected by the Doppler, the other monitors were also affected. Finapres gave "no pulse" readings, and pulse oximeter readings decreased to zero. The changes lasted for 2–4 min after cannulation, except in one case in which the pulse oximeter was zero for 17 min after cannulation (patient 1). In these four cases, cannulation of the artery was accomplished on the first attempt.

The reduction in mean finger arterial pulse pressure and mean reduction in SaO₂ are correlated to reduction in Doppler signal during the cannulation procedure (fig. 3). This figure shows that both Finapres measured pulse pressure and pulse oximeter estimated oxygen saturation were significantly affected when the reduction in Doppler velocity was greater than 65% of control.

The Allen's test performed the night before operation was abnormal in one patient (patient 7). This patient's Allen's test was abnormal in the right hand only, and cannulation was performed in the left radial artery. This patient still experienced a significant reduction in distal blood flow during cannulation.

There were ten patients taking vasodilators such as calcium channel blockers. When compared with those patients in the study not taking vasodilators, there was no statistically significant ($P < 0.67$) decrease in distal blood pressure as measured by FinapresTM.

DISCUSSION

Distal blood velocity as tracked by the Doppler decreased after radial artery cannulation in all of our patients. Despite indications by an Allen's test that there was adequate ulnar artery collateral flow, a marked decrease of distal blood velocity was indicated in 18% of patients. In this group of patients, the decrease of distal blood velocity was reflected by the loss of an adequate signal for processing by both the FinapresTM and the pulse oximeter. These changes were presumably due to spasm induced by the presence of the cannula in the artery and/or mechanical obstruction by the cannula.¹⁹ There was no correlation between the number of attempted cannulations, whether or not a wire guide was used, or the patients taking calcium channel blockers, and changes in

any of the monitors. None of our patients had any permanent ischemic changes and all monitors eventually reported values consistent with the patient's condition. In earlier studies, the incidence of transient occlusion varied from 9.8–29% following radial artery cannulation.^{19,20,21} In those studies, all the measurements had been done when the cannulas were fixed in position and mostly after the surgical procedure was completed.

This study covers the changes occurring during and after insertion of an arterial cannula. The Doppler seems to be the most sensitive monitor of blood flow impairment following cannulation. However, one of the problems in using the Doppler to measure distal blood velocity is that it is very sensitive to motion artifact and may give a false reading if moved.

Cannulation of the radial artery in most cases is performed after some test of adequate collateral ulnar arterial flow is performed. This study demonstrated that, despite indications by the Allen's test that there was sufficient collateral ulnar flow, all noninvasive monitors placed distal to the arterial cannula can be affected by changes in blood flow caused by radial artery cannulation. The FinapresTM was a moderately sensitive monitor to reduction in distal blood flow. It began to give an alarm prompt referring to a poor signal when the Doppler indicated a blood velocity decrease of greater than 30% of control.

Pulse pressure was used as a quantitative indicator of the reduction in peripheral blood pressure because the pulse pressure has been shown to be most sensitive to changes in peripheral blood flow.¹³ It should also be noted that the pulse pressure widens the more peripherally it is measured. In addition, the Finapres probe was placed on the thumb because its arterial supply is similar in structure to the radial artery rather than to digital arteries.²² This study shows that an assumed small reduction in distal blood flow (<30%) did not affect the FinapresTM or the pulse oximeter. When the reduction in distal blood velocity was marked (Doppler reduction >65%), the FinapresTM and the pulse oximeter were always affected.

Both the pulse oximeter and FinapresTM lost adequate signals when the Doppler indicated a $\geq 65\%$ decrease in velocity (fig. 3). In these cases, efforts to flush the catheters with heparinized solution were not successful in reestablishing an adequate signal. Weiss *et al.* found that papaverine in saline as a continuous infusion (0.024%) is a useful alternative to a heparinized flushing solution, which may affect blood gas samples. Further studies are needed to evaluate the possibility of injecting local anesthetic intraarterially following cannulation to reduce assumed arterial spasm.

In conclusion, our results suggest that a transient reduction in distal blood flow is common during radial artery cannulation. The finger blood pressure device and pulse oximeter react to these changes by indicating no flow or

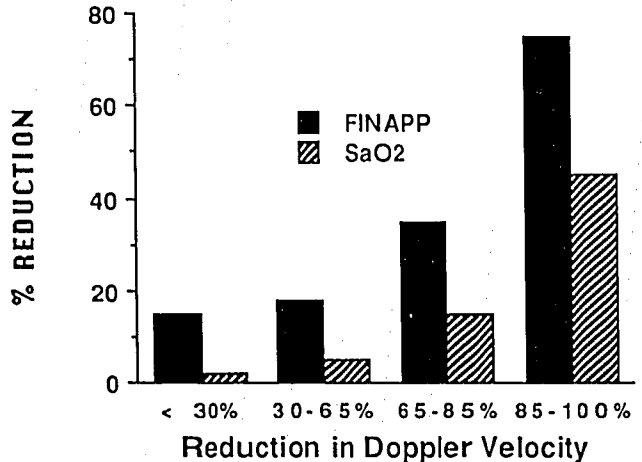


FIG. 3. The percent reduction from control for FinapresTM pulse pressure (FINAPP) and oxygen saturation (SaO₂) estimated by the pulse oximeter is plotted with respect to the maximal percent reduction in Doppler measured velocity during arterial cannulation.

pulse for several minutes following cannulation. In critically ill patients who present to the operating room and who need invasive monitoring prior to anesthesia induction, noninvasive peripheral monitors such as pulse oximeters and FinapresTM are usually placed on the patient to provide vital sign information while invasive monitors are placed. If peripheral monitors are to be used, the anesthetist must be aware that loss of signal may occur, and the probes should not be placed on the hand where a radial artery line is to be inserted. Persistent alarm of "no pulse" or "decreased pulse pressure" from noninvasive probes placed on the same hand as the arterial cannula may indicate the possibility of continued vasospasm or cannula problems. Further study is also required to see if patients taking oral vasodilators, such as calcium channel blocking drugs, are protected from distal vasospasm.

The authors wish to thank Mr. Sean de Priest for help in processing patient data.

APPENDIX

Quantification of Doppler Output. The Doppler signal has been shown to be a stationary, zero mean, random process.²³ While useful information can be obtained by simply listening to the audible signal from a continuous Doppler device, we chose to use a detection process to quantify the intensity of the back-scattered signal and display it on a strip chart. A root-mean-square (RMS) process was selected, because its output is a measure of the intensity of a noise process.²⁴

The RMS function was implemented with a Burr-Brown device type 4341.† The operations of acquiring, extracting, av-

† Burr-Brown Research Corporation Product Data Book, 1982.

eraging, and square roots are provided by the Burr-Brown 4341, such that:

$$E_{\text{out}}(t) = 1/T \int_0^t [E_{\text{in}}(t)]^2 dt$$

This is the true RMS value of a time varying signal, $E(t)$, over an averaging period T . The averaging function is provided by a single-pole RC low-pass filter whose time constant is $1/2$ RC. We used a time constant of 0.3 s. The selection criteria for Doppler signal were a flow waveform that correlated well with an arterial pressure waveform and one that had minimum signal fluctuations or noise. Since the Doppler was uncalibrated, we selected the maximum height of the Doppler signal on the strip chart during the control period, and scaled all decreases from that value.

REFERENCES

1. Bedford RF: Percutaneous radial-artery cannulation-increased safety using teflon catheters. *ANESTHESIOLOGY* 42:219-222, 1975
2. Bedford RF: Radial artery function following percutaneous cannulation with 18- and 20-gauge catheters. *ANESTHESIOLOGY* 47:37-39, 1977
3. Davis FM, Stewart JM: Radial artery cannulation: A prospective study in patients undergoing cardiothoracic surgery. *Br J Anaesth* 52:41-47, 1980
4. Jones RM, Hill AB, Nahrwold ML, Bolles RE: The effect of method of radial artery cannulation on postcannulation blood flow and thrombus formation. *ANESTHESIOLOGY* 55:76-78, 1981
5. Bedford RF, Wollman H: Complications of percutaneous radial-artery cannulation: An objective study in man. *ANESTHESIOLOGY* 38:228-236, 1973
6. Downs JB, Backstein AD, Klein EF, Hawkins IF: Hazards of radial-artery catheterization. *ANESTHESIOLOGY* 38:283-286, 1973
7. Slogoff S, Keats AS, Arlund C: On the safety of radial artery cannulation. *ANESTHESIOLOGY* 59:42-47, 1983
8. Gillies IDS, Morgan M, Sykes MK: The nature and incidence of complications of peripheral arterial puncture. *Anaesthesia* 34: 506-509, 1979
9. Mangano DT, Hickey RF: Ischemic injury following uncomplicated radial artery catheterization. *Anesth Analg* 58:55-57, 1979
10. Cannon BW, Meshier WT: Extremity amputation following radial artery cannulation in a patient with hyperlipoproteinemia type V. *ANESTHESIOLOGY* 56:222-223, 1982
11. Palm T: Evaluation of peripheral arterial pressure on the thumb following radial artery cannulation. *Br J Anaesth* 49:819-823, 1977
12. Penaz J, Voigt A, Teichmann W: Beitrag zur fortlaufenden indirekten blutdruckmessung. *Z Gesamte Inn Med* 31:1030-1033, 1976
13. Wesseling KH, de Wit B, Settels JJ, Klawer WH: On the indirect registration of finger blood pressure after Penaz. *Funkt Biol Med* 1:245-250, 1982
14. Lawson D, Norley I, Korbon G, Loeb R, Ellis J: Blood flow limits and pulse oximeter signal detection. *ANESTHESIOLOGY* 67:599-603, 1987
15. Kurki TS, Smith NT, Head N, Dec-Silver H, Quinn A: Noninvasive continuous blood pressure measurement from the finger: Optimal measurement conditions and factors affecting reliability. *J Clin Monit* 3:6-13, 1987
16. Allen EV: Thromboangiitis obliterans: Methods of diagnosis of chronic occlusive arterial lesions distal to the wrist with illustrative cases. *Am J Med Sci* 128:237-244, 1929
17. Smith NT, Wesseling KH, de Wit B: Evaluation of the two prototype devices producing noninvasive, pulsatile, calibrated blood pressure measurement from a finger. *J Clin Monit* 1:17-29, 1985
18. Yelderman M, New W: Evaluation of pulse oximetry. *ANESTHESIOLOGY* 59:349-352, 1983
19. Kim JM, Arakawa K, Bliss J: Arterial cannulation: Factors in the development of occlusion. *Anesth Analg* 54:836-841, 1975
20. Mandel MA, Dauchot PJ: Radial artery cannulation in 1000 patients: Precautions and complications. *J Hand Surg* 6:482-485, 1977
21. Weiss BM, Gattiker RI: Complications during and following radial artery cannulation: A prospective study. *Intensive Care Med* 12:424-428, 1986
22. Shaw EF, Kaplan EB: The blood supply at the hand, Kaplan's Functional and Surgical Anatomy at the Hand, third edition. Edited by Kaplan EB. Philadelphia, J. B. Lippincott Company, 1984, pp 203-221
23. Mo L, Cobbold R: A stochastic model of the backscattered Doppler ultrasound from blood. *IEEE Trans Biomed Eng* 33:20-28, 1986
24. Angelsen B, Kristoffersen K: Discrete time estimation of the mean Doppler frequency in ultrasonic blood velocity measurements. *IEEE Trans Biomed Eng* 30:207-214, 1983