

5. Stuart GG, Merry GS, Smith JA, Yelland DN: Severe head injury managed without intracranial pressure monitoring. *J Neurosurg* 59:601-605, 1983
6. Carmichael FJ, Lindop MJ, Forman JV: Anesthesia for hepatic transplantation: Cardiovascular and metabolic alterations and their management. *Anesth Analg* 64:108-116, 1985
7. Kang YG, Gelman S: Anesthesia for liver transplantation, Anesthesia for Organ Transplantation. Edited by Gelman S. Philadelphia, W. B. Saunders, 1987, pp 139-185
8. Hanid MA, Davies M, Mellon PJ, Silk DBA, Strunin L, McCabe JJ, Williams R: Clinical monitoring of intracranial pressure in fulminant hepatic necrosis. *Gut* 21:866-869, 1980
9. Ware AJ, D'Agostino AN, Combes B: Cerebral edema: A major complication of massive hepatic necrosis. *Gastroenterology* 61: 877-884, 1971
10. Paulsen AW, Valek TR, Blessing WS, Johnson DD, Parks RI, Pyron JT, Ramsay MA, Simpson BR, Swygert TH, Walling PT, Klintmalm G: Hemodynamics during liver transplantation with veno-venous bypass. *Transplant Proc* 19:2417-2419, 1987
11. Canalese J, Gimson AES, Davis C, Mellon PJ, Davis M, Williams R: Controlled trial of dexamethasone and mannitol for the cerebral edema of fulminant hepatic failure. *Gut* 23:625-629, 1982
12. Shapiro HM: Anesthesia, Neurosurgical Anesthesia and Intracranial Hypertension. Edited by Miller RD. New York, Churchill Livingstone, 1986, pp 1592-1593

Anesthesiology
70:141-144, 1989

Treatment of Isorhythmic A-V Dissociation during General Anesthesia with Propranolol

RUSSELL F. HILL, M.D.*

Isorhythmic A-V dissociation is a common cardiac dysrhythmia during anesthesia that usually occurs in patients anesthetized with one of the potent volatile anesthetics.¹⁻³ With continuous monitoring of the electrocardiogram, the P-R interval is observed to gradually shorten as the P wave approaches the QRS complex and then disappears within it. The QRS morphology does not change, and the SA node and AV node continue to depolarize independently of each other but at similar rates.^{4,5} The P wave usually remains hidden within the QRS complex giving the appearance of an A-V junctional rhythm, but it may be observed to immediately follow it or to move in and out of it. When observed the P wave morphology is not altered, unlike in true A-V junctional rhythms where the atria are depolarized from the A-V node, usually causing inverted P waves in leads II, III, and AVF.⁶

Isorhythmic A-V dissociation is usually tolerated without hemodynamic compromise and its diagnosis is frequently missed. In healthy patients anesthetized with halothane, isorhythmic A-V dissociation has been found to cause a 17% decrease in systolic blood pressure⁷ and a 14% decrease in mean arterial blood pressure⁸ with a relatively constant heart rate. Isorhythmic A-V dissociation can, however, occasionally result in a significant decrease

in arterial blood pressure.⁹ In patients with compromised cardiac function the loss of the normal atrial contribution to left ventricular filling can significantly reduce cardiac output.

Decreasing the inhaled anesthetic concentration can convert isorhythmic A-V dissociation to sinus rhythm.⁷ Previous clinical reports have demonstrated that both atropine⁹ and succinylcholine¹⁰ may be effective treatments in some cases of A-V junctional rhythm during anesthesia. The incidence of A-V junctional rhythms in patients anesthetized with fentanyl and nitrous oxide was reduced by pretreatment with praloxolol.¹¹ Intravenous propranolol was reported to successfully convert an apparent A-V junctional rhythm to a sinus rhythm in one patient.¹² Some of these rhythm disturbances were probably isorhythmic A-V dissociation.^{3,13}

Four cases of patients who developed isorhythmic A-V dissociation during cardiac surgery are presented. In each case the P wave was observed to gradually approach the QRS complex and then disappear within it. The administration of propranolol was successful in treating each episode.

CASE REPORTS

Case 1. A 74-yr-old man with class IV angina, a history of palpitations, a previous myocardial infarction (MI), and a traumatic right lower leg amputation was admitted to the hospital for evaluation of his angina. His electrocardiogram (ECG) showed a normal sinus rhythm at a rate of 75 beats/min and an old inferior MI. Cardiac catheterization revealed significant three vessel coronary artery disease, an ejection fraction of 55%, and aortic stenosis with a pressure gradient of 40 mmHg across the aortic valve. His preoperative medications, including 30 mg of diltiazem and 20 mg of isorbid dinitrate every 6 h, were continued to the time of surgery. He was scheduled for coronary revascularization

* Assistant Professor of Anesthesiology.

Received from the Department of Anesthesiology, Heart Center of Duke Hospital, Duke University Medical Center, Durham, North Carolina. Accepted for publication August 1, 1988.

Address reprint requests to Dr. Hill: Duke University Medical Center, Box 3094, Durham, North Carolina 27710.

Key words: Antiarrhythmic therapy: propranolol. Dysrhythmias: anesthesia.

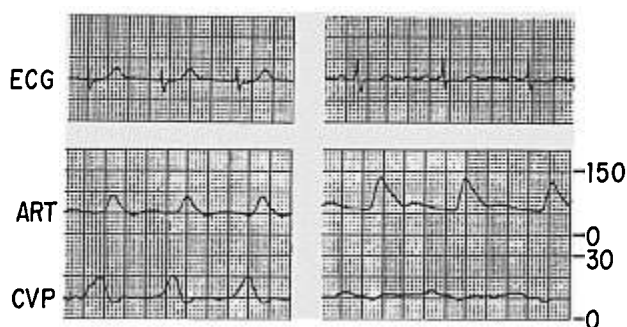


FIG. 1. ECG, radial artery (ART), and central venous pressure (CVP) tracings from case 2. Isorhythmic A-V dissociation (left) was converted to sinus rhythm (right) with propranolol. Pressure is shown in mmHg.

and aortic valvuloplasty. Following placement of iv, radial artery, and pulmonary artery catheters, anesthesia was induced with 250 μ g of sufentanil, 2 mg of midazolam, and 10 mg of vecuronium iv. The trachea was intubated, and the lungs ventilated with 0.5% isoflurane in oxygen. Following iv administration of 6 mg of pancuronium in divided doses, a change from sinus rhythm (64 beats/min) to isorhythmic A-V dissociation (68 beats/min) was noted on the ECG. Two milligrams of propranolol, given in 1 mg iv boluses, resulted in a conversion to sinus rhythm (64 beats/min) within 2 min. Disappearance of cannon A waves on the central venous pressure (CVP) tracing and an increase in arterial blood pressure from 125/55 mmHg to 145/60 mmHg accompanied the conversion to sinus rhythm.

Case 2. A 68-yr-old man with class III angina and a diastolic murmur was admitted for cardiac catheterization. His ECG showed a normal sinus rhythm with a rate of 58 beats/min, left ventricular hypertrophy, and left axis deviation. Cardiac catheterization revealed three vessel coronary artery disease, moderate aortic insufficiency, and an ejection fraction of 52%. He was scheduled for coronary revascularization and aortic valve replacement. He was taking 80 mg of verapamil every 8 h and nitroglycerin ointment preoperatively, which were continued on the morning of surgery. After insertion of iv, radial artery, and pulmonary artery catheters he was anesthetized with 2.25 mg of fentanyl and 10 mg of pancuronium iv, the trachea intubated, and lungs ventilated with 100% oxygen. Enflurane in concentrations of up to 0.7% was used to help control hemodynamic responses to surgery. Seventy-five minutes following induction of anesthesia a change from sinus rhythm (68 beats/min) to isorhythmic A-V dissociation (84 beats/min) was noted. Two milligrams of propranolol were given in 1 mg iv boluses, followed by conversion to sinus rhythm (75 beats/min) 3 min later. Sinus rhythm was associated with a loss of A waves on the CVP trace and an increase in arterial blood pressure from 90/45 to 130/60 mmHg (fig. 1).

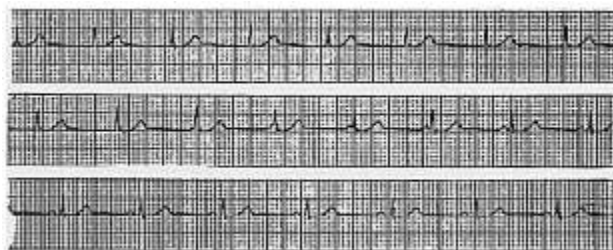


FIG. 2. Continuous recording of the ECG from case 3 after treatment with propranolol. Note the gradual emergence of the P wave from the QRS complex as isorhythmic A-V dissociation converts to sinus rhythm.

Case 3. A 42-yr-old man with a previous MI, who in the past had undergone percutaneous transluminal coronary angioplasty, was admitted to the hospital with unstable angina. Cardiac catheterization revealed significant two vessel coronary artery disease and an ejection fraction of 40%. He was referred for coronary revascularization. He had a sinus rhythm at 65 beats/min and an old anterior MI on his preoperative ECG. His preoperative medications, which included 60 mg of diltiazem every 6 h, nitroglycerin ointment, and a heparin infusion, were continued until surgery. After iv, radial artery, and pulmonary artery cannulation, anesthesia was induced with 2.0 mg of fentanyl, 10 mg of midazolam, and 10 mg of vecuronium iv. The trachea was intubated, and lungs ventilated with 0.6% halothane in oxygen. Fifteen minutes after induction of anesthesia a change from sinus rhythm (68 beats/min) to isorhythmic A-V dissociation (83 beats/min) became evident. Treatment with 1 mg of propranolol, given in 0.5 mg iv boluses, resulted in conversion to sinus rhythm (62 beats/min), which was associated with an increase in arterial blood pressure from 130/70 to 145/75 mmHg. Thirty minutes later the patient again experienced isorhythmic A-V dissociation, which was also successfully treated with 1 mg of propranolol iv (fig. 2).

Case 4. A 72-yr-old man was admitted to the hospital with an uncomplicated acute MI. Six days following his MI, cardiac catheterization showed three vessel coronary artery disease and a left ventricular ejection fraction of 45%. He had a normal sinus rhythm at a rate of 71 beats/min with an anterior MI on his preoperative ECG. The patient was taking 30 mg of diltiazem every 6 h and nitroglycerin ointment preoperatively, which were continued until surgery. The patient was brought to the operating room for coronary revascularization. Following iv, radial artery, and pulmonary artery cannulation, anesthesia was induced with 150 μ g of sufentanil, 2 mg of midazolam, and 10 mg of vecuronium iv. The trachea was intubated and the lungs ventilated with 100% oxygen. Sixty minutes after induction of anesthesia, his ECG showed a change from sinus rhythm (64 beats/min) to isorhythmic A-V dissociation (88 beats/min). Treatment with 1 mg of propranolol iv resulted in a return to sinus rhythm (65 beats/min) within 5 min.

DISCUSSION

The mechanism of isorhythmic A-V dissociation was described in 1946 when Segers¹⁴ reported that if two spontaneously beating fragments of frog myocardium were placed in contact, they often contracted simultaneously at equal rates. For development of synchronization to occur the individual spontaneous rates had to be within 25% of each other. The synchronized rate of the two fragments was usually equal to the more rapidly beating fragment and was the result of acceleration of the more slowly beating tissue.

When normal A-V sequential contraction is interrupted, and the atria and ventricles beat independent of each other, A-V dissociation is said to exist. Sometimes the atria and ventricles contract almost simultaneously at a common rate, similar to the frog cardiac tissue described by Segers.¹⁴ This phenomenon has been called atrioventricular synchronization, or when happening for only a short time, accrochage.¹⁵ The term isorhythmic dissociation is now more commonly used. This dysrhythmia is well described in several clinical settings.^{4,15-18}

The appearance of atrioventricular junctional rhythms during general anesthesia with volatile anesthetics oc-

curred in 4–46% of patients in several clinical investigations.^{1,2,19–24} Many of these were actually examples of isorhythmic A-V dissociation. Kuner *et al.*² and Alexander *et al.*² found that over 50% of the rhythms appearing to be junctional were isorhythmic A-V dissociation. Rhythms of junctional appearance have also been observed during anesthesia with nitrous oxide and fentanyl,²⁵ following administration of pancuronium as in the first case,²⁶ and frequently after reversal of muscle relaxants with anticholinesterase drugs.^{27–30}

The four patients discussed in this report were all anesthetized primarily with opioids following preoperative sedation with a benzodiazepine. Inhaled anesthetics were used in low concentrations. None of the patients were given preoperative beta adrenergic blockers, which reduce the incidence of junctional rhythms during anesthesia.¹¹ All were taking calcium channel blockers, which may have increased the chance of isorhythmic A-V dissociation. The appearance of junctional rhythms has been reported in patients treated with verapamil.³¹ In all of the present cases the P wave was seen to gradually approach and then hide within the QRS complex, giving the appearance of an A-V junctional rhythm. Treatment with small doses of iv propranolol was effective in converting isorhythmic A-V dissociation to sinus rhythm in all four patients, which is consistent with this author's clinical experience. During conversion to sinus rhythm, the P wave gradually receded from the QRS complex. Restoration of sinus rhythm increased systolic blood pressure by an average of 18%, which is similar to previous reports.^{7,8}

Propranolol slows conduction and increases the effective refractory period of the A-V node. It reduces the rate of spontaneous diastolic depolarization and therefore the rate of impulse formation in cells that exhibit automaticity.³² Propranolol may preferentially slow the spontaneous rate of depolarization of accelerated A-V nodal tissue, thus allowing the sinus node to reassume control of heart rate with a conversion to sinus rhythm.

Propranolol should be used to treat isorhythmic A-V dissociation only after the diagnosis is certain. Beta adrenergic blockers are contraindicated for treatment of junctional escape rhythms, which result from default of normal SA node pacemaker function as in SA block, sick sinus syndrome, or high AV block.⁶ Junctional escape occurs after a longer beat-to-beat interval than in the normal dominant sinus rhythm, producing a slower rhythm, usually from 30 to 60 beats/min. It functions as a safety mechanism and should be not suppressed. Isorhythmic A-V dissociation, however, generally results from acceleration of the A-V node, giving rise to a rhythm that is faster than the dominant sinus rhythm. Propranolol should be used with a great deal of caution in patients with disease, such as bronchospasm or poor ventricular function, which is aggravated by the known actions of the

drug. A short-acting drug with more beta 1 receptor specificity such as esmolol may be preferred in situations in which the side effects of beta adrenergic blockade are potentially detrimental.

In conclusion, isorhythmic A-V dissociation is a common rhythm disturbance during general anesthesia. Small doses of iv propranolol are effective in converting this rhythm to normal sinus rhythm.

REFERENCES

1. Kuner J, Enescu V, Utsu F, Boszormenyi E, Bernstein H, Corday E: Cardiac arrhythmias during anesthesia. *Dis Chest* 52:580–587, 1967
2. Alexander JP, Bekheit S, Fletcher E: Dysrhythmia and oral surgery II: junctional rhythms. *Br J Anaesth* 44:1179–1182, 1972
3. Sethna DH, Deboer GE, Millar RA: Observations on "junctional rhythms" during anaesthesia. *Br J Anaesth* 56:924–925, 1984
4. Schubart AF, Marriott HJL, Gorten RJ: Isorhythmic dissociation atrioventricular dissociation with synchronization. *Am J Med* 24:209–214, 1958
5. Marriott HJL, Menendez MM: A-V dissociation revisited. *Prog Cardiovasc Dis* 8:522–538, 1966
6. Marriott HJL, Myerburg RS: Recognition of arrhythmias and conduction abnormalities, *The Heart*, 6th edition. Edited by Hurst JW. New York, McGraw-Hill, 1986, pp 433–475
7. Laver MB, Turndorf H: Atrial activity and systemic blood pressure during anesthesia in man. *Circulation* 28:63–71, 1963
8. Haldemann G, Schaer H: Haemodynamic effects of transient atrioventricular dissociation in general anaesthesia. *Br J Anaesth* 44:159–162, 1972
9. Boba A: Significant effects on the blood pressure of an apparently trivial dysrhythmia. *ANESTHESIOLOGY* 48:282–283, 1978
10. Galindo A, Wyte SR, Wetherhold JW: Junctional rhythm induced by halothane anesthesia-treatment with succinylcholine. *ANESTHESIOLOGY* 37:261–262, 1972
11. Saarnivaara L, Kentala E, Kautto UM, Yrjola H: Electrocardiographic changes during microlaryngoscopy in practolol-pre-treated patients under balanced anaesthesia. *Acta Anaesthesiol Scand* 30:128–131, 1986
12. Breslow MJ, Evers AS, Lebowitz P: Successful treatment of accelerated junctional rhythm with propranolol: Possible role of sympathetic stimulation in the genesis of this rhythm disturbance. *ANESTHESIOLOGY* 62:180–182, 1985
13. Sosis M, Cooper PS, Herr G: The diagnosis of "junctional rhythms" with halogenated anesthetics. *ANESTHESIOLOGY* 63:233–234, 1985
14. Segers M: Les phenomenes de synchronisation au niveau du coeur. *Arch Int Physiol Biochim* 54:87–106, 1946
15. Marriott HJL: Atrioventricular synchronization and accochage. *Circulation* 14:38–43, 1956
16. Segers M, Lequime J, Denolin H: Synchronization of auricular and ventricular beats during complete heart block. *Am Heart J* 33:685–691, 1947
17. Fletcher E, Morton P, Murtagh JG, Bekheit S: Atrioventricular dissociation with accochage. *Br Heart J* 33:572–577, 1971
18. Marriott HJL: Interactions between atria and ventricles during interference-dissociation and complete A-V block. *Am Heart J* 53:884–889, 1957
19. Wright CJ: Dysrhythmias during oral surgery: A comparison between halothane and enflurane anaesthesia. *Anaesthesia* 35: 775–778, 1980

20. Ryder W, Wright PA: Halothane and enflurane in dental anesthesia. *Anaesthesia* 36:492-497, 1981
21. Lindgren L: ECG changes during halothane and enflurane anaesthesia for E.N.T. surgery in children. *Br J Anaesth* 53:653-662, 1981
22. Thomas VJE, Kyriakou KP, Thurlow AC: Cardiac arrhythmias during outpatient dental anaesthesia: A comparison of controlled ventilation with and without halothane. *Br J Anaesth* 50:1243-1245, 1978
23. Bertrand CA, Steiner NV, Jameson AG, Lopez M: Disturbances of cardiac rhythm during anesthesia and surgery. *JAMA* 216:1615-1617, 1971
24. Saarnivaara L: Comparison of halothane and enflurane anaesthesia for tonsillectomy in adults. *Acta Anaesthesiol Scand* 28:319-324, 1984
25. Saarnivaara L, Kentala E: Comparison of electrocardiographic changes during microlaryngoscopy under balanced anaesthesia induced by althesin or thiopentone. *Acta Anaesthesiol Scand* 24:321-324, 1980
26. Saemund O, Dalentius E: Pancuronium and nodal rhythm. *Br J Anaesth* 53:780, 1981
27. Cronnelly R, Morris RB, Miller RD: Edrophonium: Duration of action and atropine requirement in humans during halothane anesthesia. *ANESTHESIOLOGY* 57:261-266, 1982
28. Urquhart ML, Ramsey FM, Royster RL, Morrell RC, Gerr P: Heart rate and rhythm following an edrophonium/atropine mixture for antagonism of neuromuscular blockade during fentanyl/N₂O/O₂ or isoflurane/N₂O/O₂ anesthesia. *ANESTHESIOLOGY* 67:561-565, 1987
29. Azar I, Pham AN, Karambelkar DJ, Lear E: The heart rate following edrophonium-atropine and edrophonium-glycopyrrolate mixtures. *ANESTHESIOLOGY* 59:139-141, 1983
30. Takkkunen O, Salmenpera M, Heinonen J: Atropine vs. glycopyrrolate during reversal of pancuronium block in patients anaesthetized with halothane. *Acta Anaesthesiol Scand* 28:377-380, 1984
31. Walker WS, Winniford MD, Mauritsen DR, Johnson SM, Hillis LD: Atrioventricular junctional rhythm in patients receiving oral verapamil therapy. *JAMA* 249:389-390, 1983
32. Wit AL, Hoffman BF, Rosen MR: Electrophysiology and pharmacology of cardiac arrhythmias: IX. Cardiac electrophysiologic effects of beta adrenergic receptor stimulation and blockade, Part C. *Am Heart J* 90:795-803, 1975

Anesthesiology
70:144-146, 1989

Fiberoptic Endobronchial Intubation for Resection of an Anterior Mediastinal Mass

DIRK YOUNKER, M.D.,* RANDALL CLARK, M.D.,† LEWIS COVELER, M.D.‡

Growth of a cervical goiter through the thoracic inlet into the retrosternal space is a rare cause of an anterior mediastinal mass.¹ This uncommon lesion frequently presents with life-threatening respiratory obstruction.²⁻⁴ It is not sensitive to radiation therapy and carries a mortality rate approaching 3% if not surgically corrected.^{5,6} In common with other types of anterior mediastinal masses, loss of respiratory muscle tone may precipitate complete obstruction of the tracheobronchial tree, which may not be relieved by passage of an endotracheal tube through the vocal cords.^{7,8} If this occurs, an intraoperative death may rapidly follow.⁹ The case of a patient in whom fiberoptic endobronchial intubation during spontaneous respiration allowed safe induction of anesthesia for excision of a massive intrathoracic goiter is presented.

* Assistant Professor.

† Chief Resident.

‡ Associate Professor.

Received from the Department of Anesthesiology, Baylor College of Medicine, Houston, Texas. Accepted for publication August 1, 1988.

Address reprint requests to Dr. Younker: Department of Anesthesiology, Baylor College of Medicine, One Baylor Plaza, Suite 435-D, Houston, Texas 77025.

Key words: Anesthesia: thoracic. Intubation, endotracheal: fiberoptic technique.

CASE REPORT

A 60-yr-old, 178-cm, 120-kg woman was scheduled for urgent mediastinoscopy and median sternotomy for resection of an anterior mediastinal mass. Two months prior to admission she had noticed a progressive hoarseness of her voice, a continual sense of fullness in her upper chest, and a complete inability to sleep on her back. Three weeks prior to admission she developed audible wheezing and shortness of breath, which was so severe that she could not walk more than a few short steps. The patient had a long history of exogenous obesity.

Admission vital signs were as follows: blood pressure 130/80 mmHg, heart rate 80 beats/min, respiratory rate 26 breaths/min, and axillary temperature 37° C. Admission hemogram, serum electrolytes, liver function tests, coagulation profile, urinalysis, and ECG were completely within normal limits. Analysis of arterial blood gases (F_IO₂ 0.2) revealed the following: PaO₂ 46 mmHg, PaCO₂ 71.4 mmHg, pH_a 7.27, % hemoglobin saturation 73. Analysis of arterial blood following administration of 2 l/min O₂ by nasal cannulae showed: PaO₂ 73 mmHg, PaCO₂ 66 mmHg, pH_a 7.39, % hemoglobin saturation 95.

A chest radiograph obtained at admission showed a left upper mediastinal mass with displacement of the cervical and thoracic trachea to the right; a small mass in the right hilum was also noted. An Iridium-131 thyroid scan revealed a cold nodule in the left lobe of the thyroid with an area of nonhomogeneous uptake extending into the mediastinum. Computerized tomography of the thorax revealed continuity of the cervical, mediastinal, and hilar masses with posterior displacement of the trachea and extrinsic compression of the carina. An aortogram demonstrated compression of the aorta and brachiocephalic vessels. Severe dyspnea prevented measurement of flow-volume loops in the upright or supine positions.