

common in that institution, whereas the published studies focused on intravenous administration.

My reasons for advocating discontinuing the anesthetic after an episode of trismus are stated in the editorial in ANESTHESIOLOGY.⁵ I also feel that serial postoperative CKs should be performed in all cases of trismus. We have found that, where the CK is over 20,000, MH is diagnosed with regularity on contracture tests.⁶ In some cases, underlying myopathies have been found when the CK does not return to normal within a short period of time.

It is true that a limited number of centers perform muscle biopsies (however, this number is growing each year), and time and expense is involved. However, given the confusion as to whether trismus may imply malignant hyperthermia, failure to biopsy will frequently lead to the patient being labeled as MH susceptible; therefore, he or she, along with other family members, would require "special" care. In some cases, this entails preoperative dantrolene administration and the inconvenience of being referred to only selected hospitals and individuals willing to anesthetize an MH susceptible patient.

Dr. Berry also feels that monitoring techniques are available to detect MH early after its onset. Not all hospitals and not all operating rooms are equipped with end-tidal CO₂ monitoring nor with the availability of venous and arterial blood gas measurement within a reasonable period of time. Indeed, not all facilities have dantrolene on hand!⁷

Finally, I certainly agree with Dr. Berry's statement regarding weighing risk/benefit ratios each time we use a drug during anesthesia. It is clear that every "expert" will draw his/her own conclusions regarding the meaning of trismus and the clinical implications of this sign. This problem will continue to plague clinicians until such time as a reliable noninvasive diagnostic test for MH is developed, an understanding of the pathophysiology of trismus and malignant hyper-

thermia is achieved and/or a satisfactory substitute for succinylcholine is introduced into clinical practice.

HENRY ROSENBERG, M.D.
Professor and Chairman
Department of Anesthesiology
Hahnemann University
Broad and Vine
Philadelphia, Pennsylvania 19102-1192

REFERENCES

1. Ellis FR, Halsall PJ: Suxamethonium spasm. A differential diagnostic conundrum. *Br J Anaesth* 56:381-383, 1984
2. Van Der Spek AFL, Fong WB, Ashton-Miller JA, Stohler CS, et al: The effects of succinylcholine on mouth opening. *ANESTHESIOLOGY* 67:459-465, 1987
3. Schwartz L, Rockoff MA, Koka BU: Masseter spasm with anesthesia: Incidence and implications. *ANESTHESIOLOGY* 61:772-775, 1984
4. Ording H: Incidence of malignant hyperthermia in Denmark. *Anesth Analg* 64:700-705, 1985
5. Rosenberg H: Trismus is not trivial. *ANESTHESIOLOGY* 67:453-455, 1987
6. Rosenberg H, Fletcher JG: Masseter muscle rigidity and malignant hyperthermia susceptibility. *Anesth Analg* 65:161-164, 1986
7. Hein HAT, Roer N, Jantzen J-P: Malignant hyperthermia: Are we really prepared? (letter). *ANESTHESIOLOGY* 66:448-449, 1987

(Accepted for publication September 14, 1988.)

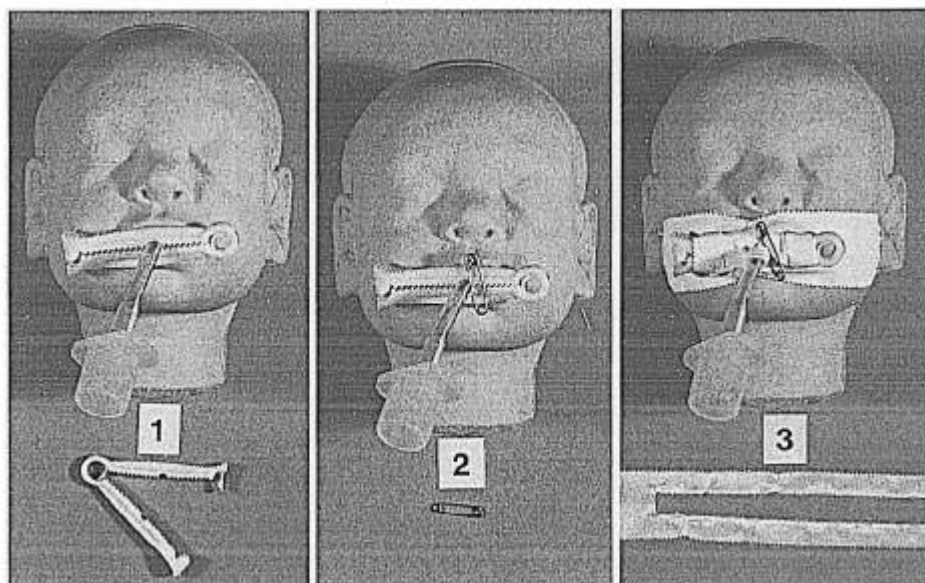
Anesthesiology
70:163-164, 1989

An Infant Model to Facilitate Endotracheal Tube Fixation in the Pediatric ICU Patient

To the Editor:—As pediatric anesthesiologists, we recognize and share the concerns others have expressed regarding inadvertent tracheal extubation in infants and children. These patients are particularly at

risk because of their inability to cooperate and because of the short length of the infant trachea. A 13% incidence of "spontaneous" tracheal extubation has been documented in one pediatric ICU setting.¹ Others

FIG. 1. The infant model for orotracheal tube fixation. The components used to secure the orotracheal tube are numbered in order of their application.



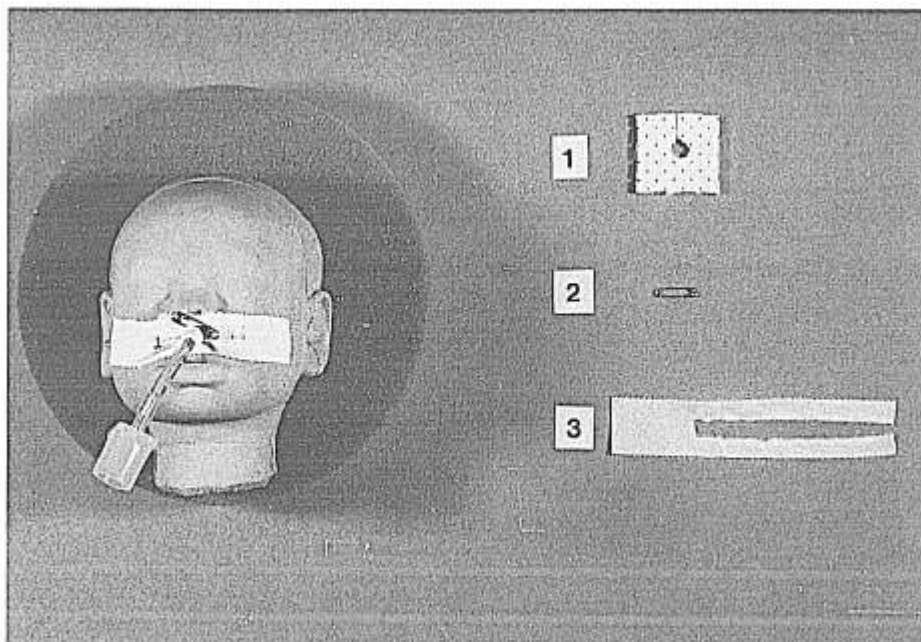


FIG. 2. The model for nasotracheal tube fixation. The components used to secure the nasotracheal tube are numbered in order of their application.

have reported cases in which death resulted or was narrowly averted following self-extubation² and have emphasized the need for ventilator alarms and appropriate sedation and patient restraints.^{2,3} Equally important is stabilization of the oral or nasal tracheal tube.

Situated in a large metropolitan area, we routinely train and work with ten to 15 residents from four or more anesthesia programs at a time. The wide variation in level of training and clinical skills exhibited by our trainees has impressed upon us the need for some type of teaching aid to standardize and ensure proper tube fixation. For this reason, lifelike models of infants were designed at our request by Mr. Raymond Evenhouse of the University of Illinois School of Biocommunication Arts in Chicago. These models are used to display our method for securing both oral and nasal tracheal tubes (figs. 1, 2). The "cored-out" umbilical cord clamp (fig. 1, #1) snapped around the orotracheal tube and the small safety pin placed through the wall and peripheral lumen of the oro- or nasotracheal tube minimize inadvertent advancement of the endotracheal tube into a mainstem bronchus. The tape, and adhesive applied to the underlying skin, minimize accidental extubation. Padding (fig. 2, #1) is applied around the nasotracheal tube to prevent pressure necrosis of the external naris. The residents simply refer to the models prior to securing the tube to ensure proper technique.

The models have facilitated resident education in a teaching environment with many personnel from varied clinical backgrounds, and we believe they increase patient safety in the critical care setting.

PATRICK K. BIRMINGHAM, M.D.
Associate in Clinical Anesthesia

*Northwestern University
Attending Anesthesiologist
Children's Memorial Hospital*

BABETTE HORN, M.D.
Assistant Professor

*Northwestern University
Attending Anesthesiologist
Children's Memorial Hospital
2300 Children's Plaza
Chicago, Illinois 60614*

REFERENCES

1. Scott PH, Eigen H, Moya LA, Georgitis J, Laughlin JL: Predictability and consequences of spontaneous extubation in a pediatric ICU. *Crit Care Med* 13:228-232, 1985
2. Hall D: Accidental removal of endotracheal tubes. *Br Med J* 1: 1424, 1979
3. Baum VC, Barnum J, Howe J: Accidental extubations in pediatric patients. *Crit Care Med* 13:1873, 1985

(Accepted for publication September 14, 1988.)

An Alternative Method for Management of Accidental Dural Puncture for Labor and Delivery

To the Editor:—After accidental dural puncture during attempted epidural analgesia for labor, it is common practice to repeat the epidural block in an adjacent interspace. Occasionally, this leads to spinal anes-

thesia that may progress to total spinal blockade.¹ Resultant motor block creates great inconvenience for the parturient and may increase the incidence of instrumental deliveries.