

Anesthesiology  
70:170, 1989

*In Reply:*—The Quest product codes discussed, 9113 and 9107, incorporate luer-locking one-way check valves. They are designed to allow multiple access to a single site using luer-locking connections, thus eliminating the need for the use of needles. Additionally, as the term "one-way" implies, the check valves are designed to prevent flow in one direction (retrograde) and allow flow in the other (toward the patient). The set is not designed to inhibit either fluid flow or air flow toward the patient. Therefore, if a valve is not in use, it should be capped off both to prevent air ingress and to minimize the risk of contamination associated with leaving any port open.

A spring-loaded check valve such as that used in the Cutter set performs differently. It is designed to prevent flow in one direction (retrograde) and restrict flow in the other (toward the patient). Flow toward the patient can occur only after enough pressure has been created to

open the valve. The pressure required to open the valve is significant enough to prevent gravity flow through it. Fluid must be pumped or pushed through it. With the absence of this pressure, there is no flow of either fluid or air to the patient.

As pointed out in the letter, it is important that users understand the difference in performance of these two types of check valves.

THELMA MACEDO  
Product Manager  
Quest Medical Inc.  
4103 Billy Mitchell Drive  
Dallas, Texas 75244

(Accepted for publication September 29, 1988.)

Anesthesiology  
70:170-171, 1989

## A Tracheal Tube Extension for Emergency Tracheal Reanastomosis

*To the Editor:*—A variety of preformed and other specialized endotracheal tubes have been fashioned in recent years to address special surgical or anesthetic circumstances. Recently, a surgical emergency gave us an opportunity to fashion yet another airway device from readily available materials.

A 28-yr-old approximately 100-kg white man arrived at the emergency room following a motor vehicle accident, having sustained multiple injuries including bilateral pedicle fracture of C2 with anterior subluxation and angulation of C2 on C3, multiple rib fractures with flail chest, and suspicion of a partial tracheal transection, with subcutaneous emphysema. Following nasotracheal intubation by an emergency room physician, the patient arrived to the operating room awake, combative, and neurologically intact. His blood alcohol level was 252 mg%.

Fiberoptic bronchoscopy revealed a complete tracheal transection with a gap of 5 cm. Alternative ventilation plans discussed between surgical and anesthesia teams included passing an endotracheal tube onto the field, should the upper airway segment separate further from the lower segment.

Following induction of anesthesia, neuromuscular blockade was accomplished with pancuronium bromide, and the patient was positioned and prepped for right thoracotomy. His lungs became progressively difficult to ventilate in the ensuing 5 min, with increased peak airway pressure, hypotension, and bradycardia. Thoracotomy revealed severe mediastinal emphysema with ineffective lung expansion. The distal tracheal segment was identified and mobilized, and a sterile 7.0-mm anode tube was passed onto the field and inserted into the distal tracheal segment. A sterile anesthesia circuit was also passed onto the field and connected to the anesthesia machine, and the patient's lungs were ventilated uneventfully.

After securing the anode tube in the distal tracheal segment, the proximal tracheal segment was identified and mobilized with the patient in the lateral decubitus position. Segment separation was approximately 7-8 cm, preventing an ordinary 33-cm endotracheal tube from being passed to the distal segment during tracheal anastomosis. A nasogastric tube was passed through the *in situ* nasotracheal tube, and a long endotracheal tube was fashioned (fig. 1) and passed over the nasogastric tube until the tip was visualized in the proximal tracheal segment. It was then guided by the surgical team into the distal segment, following

removal of the anode tube, and primary anastomosis was accomplished. Leak-testing with positive airway pressure up to 60 cm of water revealed an intact anastomosis.

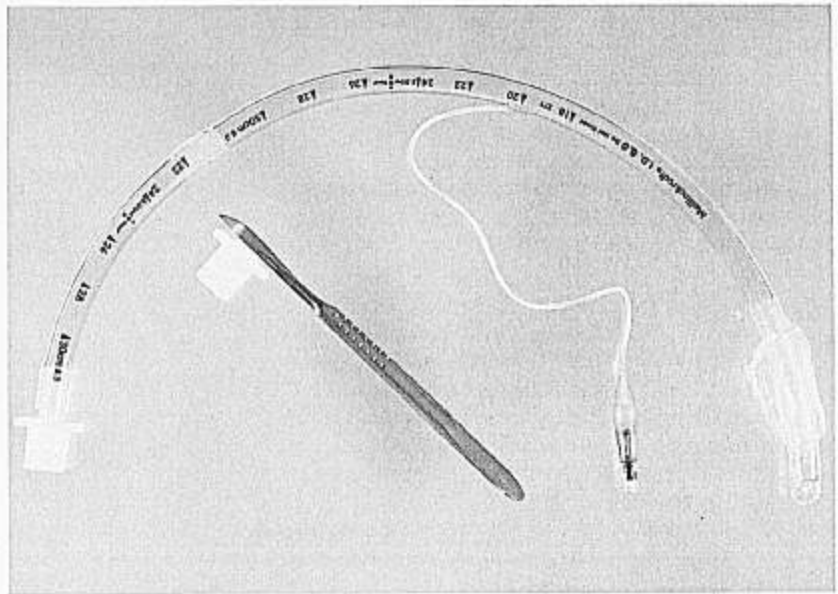
Postoperatively, the modified nasotracheal tube was sutured to the ala, and left in place as a stent until the 18th postoperative day, when fiberoptic bronchoscopy with the tube withdrawn revealed a well-healed suture line without evidence of stricture; the patient's trachea was uneventfully extubated.

Traumatic rupture of the trachea is a rarely encountered entity demanding skill and versatility in dealing with surgical emphysema, airway and circulatory compromise, and concomitant traumatic injuries.<sup>1</sup> Surgical experience with elective reconstruction of the trachea has been reported by Grillo,<sup>2,3</sup> and elective anesthetic management described by Geffin *et al.*,<sup>4</sup> Lee and English,<sup>5</sup> and Ellis *et al.*<sup>6</sup> In the last two papers, the technique employed was one of a long narrow catheter with bronchoscopic injection ventilation to the distal tracheal segment. The patients were an 8-yr-old child and a 23-kg 13-yr-old child. Air entrained through the distal tracheal segment while ventilating with 100% oxygen is a significant contributor to the tidal volume in this technique, but works much more effectively in smaller patients. Frequent suctioning is also required in the surgical field in order to prevent the aspiration of blood into the tracheal segment and lung.

In the emergent circumstance reported here, we confronted a large, intoxicated, combative patient with a presumptive diagnosis of tracheal rupture. Immediate surgical intervention was required to repair a rapidly worsening situation. Anticipation of surgical field intubation into the distal tracheal segment was facilitated by flexible fiberoptic bronchoscopy to localize the extent of tracheal damage, and the fashioning of a long tracheal tube permitted primary repair of the widely separated segments with a cuffed seal and positive pressure ventilation.

ROBERT S. HOLZMAN, M.D.  
Associate in Anesthesiology  
The Children's Hospital  
300 Longwood Avenue  
Boston, Massachusetts 02115  
Instructor in Anesthesiology  
Harvard Medical School

FIG. 1. Extended tracheal tube illustrating site of incision at the 15-mm connector, and location of the cut segment within the modified tube. This part is used as a bridge from the proximal original tracheal tube to the extension segment of a second tracheal tube.



#### REFERENCES

1. Seed RF: Traumatic injury to the larynx and trachea. *Anaesthesia* 26:55-65, 1971
2. Grillo HC: Surgical approaches to the trachea. *Surg Gynecol Obstet* 2:347-352, 1969
3. Grillo HC: Reconstruction of the trachea. *Thorax* 28:667-679, 1973
4. Geffin B, Bland J, Grillo HC: Anesthetic management of tracheal resection and reconstruction. *Anesth Analg* 48:884-894, 1969
5. Lee P, English ICW: Management of anaesthesia during tracheal resection. *Anaesthesia* 29:305-306, 1974
6. Ellis RH, Hinds CJ, Gadd LT: Management of anaesthesia during tracheal resection. *Anaesthesia* 31:1076-1080, 1976

(Accepted for publication October 3, 1988.)

Anesthesiology  
70:171-172, 1989

### The Relationship Between Malignant Hyperthermia and Neuroleptic Malignant Syndrome

*To the Editor:*—During the past year, two somewhat contradictory articles,<sup>1,2</sup> addressing the possible relationship between malignant hyperthermia (MH) and neuroleptic malignant syndrome (NMS) have been published. These two iatrogenic highly fatal hyperthermic syndromes are clinically very similar and a common pathophysiology has been suggested.<sup>1,3</sup> Therefore, some have warned that patients with a history of NMS might be at a greater risk for developing MH when exposed to volatile anesthetics.<sup>1,3</sup> The risk of developing MH has also been suggested in susceptible NMS patients undergoing electroconvulsive therapy (ECT), a procedure involving succinylcholine administration just prior to every repeated electrical stimulation.<sup>5,4</sup> Based on their findings of enhanced *in vitro* response of skeletal muscle to halothane in NMS patients, Carrof *et al.*<sup>1</sup> suggest an association between the two syndromes, and imply that a conservative approach, avoiding triggering agents (*e.g.*, halothane, succinylcholine), should be taken during anesthesia of known NMS patients. Since NMS is not very rare (0.5–1.4% of neuroleptic exposures),<sup>5</sup> and as major psychiatric disorders are quite common, annual incidence of new NMS cases might exceed thousands each year. Denying these many patients life-saving surgery or ECT is a very crucial decision and should be based on a convincing body of evidence. In order to elucidate the actual risk for MH in patients who suffered from NMS, we undertook a retrospective study of their surgical and ECT histories.<sup>6</sup> We recruited 20 patients who fulfilled Levenson's

criteria for definite diagnosis of NMS and inquired about their surgical and ECT history. Nine of the NMS patients had 12 uneventful operations involving the administration of succinylcholine and halothane. Twelve of the patients had received ECT, including five patients who were safely treated with ECT for their NMS episodes. In no case did complications ensue, despite 147 iv administrations of succinylcholine in a dose range of 15–30 mg. This outcome is corroborated by published reviews of this issue.<sup>2,6</sup> In summary, our retrospective study, as well as another recent *in vitro* study,<sup>7</sup> did not show significant cross vulnerability for MH in post-NMS patients, and leads us to conclude, in contrast to Carrof *et al.*,<sup>1</sup> that NMS patients are not at a considerable risk for fatal consequences of MH.

HAGGAI HERMESH, M.D.  
DOV AIZENBERG, M.D.  
MARGO LAPIDOT, PH.D.  
HANAN MUNITZ, M.B., B.S.  
*Geha Psychiatric Hospital  
Beilinson Medical Center  
Sackler School of Medicine  
Tel Aviv University  
Petah Tikva 49 100, Israel*