

Needle Bevel Direction and Headache after Inadvertent Dural Puncture

Mark C. Norris, M.D.,* Barbara L. Leighton, M.D.* Cheryl A. DeSimone, M.D.†

To study the effect of needle bevel direction on the incidence and severity of headache following inadvertent dural puncture occurring during the identification of the epidural space, the authors randomly assigned obstetric anesthesia residents to identify epidural space with the bevel of the epidural needle oriented either parallel or perpendicular to the longitudinal dural fibers. If dural puncture occurred, an observer unaware of the needle bevel direction, daily assessed the presence and severity of any subsequent headache. Of the 1,558 women who received epidural analgesia during this study, 41 women suffered dural puncture, 20 with the needle bevel oriented perpendicular to the longitudinal dural fibers and 21 with the needle bevel inserted parallel to the dural fibers (NS). Fourteen of 20 women in the group in which the needle bevel was perpendicular to dural fibers developed a moderate to severe headache, whereas only five of 21 in the group in which the needle bevel was parallel to dural fibers did so ($P < 0.005$). Similarly, we administered a therapeutic blood patch to ten of 20 women in the perpendicular group but to only four of 21 in the parallel group ($P < 0.05$). Thus, identifying the epidural space with the needle bevel oriented parallel to the longitudinal dural fibers limits the size of the subsequent dural tear and, therefore, lowers the incidence of headache should dural perforation occur. (Key words: Anesthetic techniques: epidural. Complications: dural puncture.)

DURAL PUNCTURE occasionally occurs while attempting to identify the epidural space. When using a 17- or 18-g needle, headache follows dural puncture in 70% of parturients.¹ This high incidence of postdural puncture headache represents a significant cause of postpartum maternal morbidity. Orienting the bevel of a 22- or 25-g needle parallel to the longitudinal dural fibers significantly diminishes the incidence of headache following subarachnoid anesthesia.² In the current study, we asked the question: does identifying the epidural space with the bevel of the 17- or 18-g Hustead needle oriented parallel rather than perpendicular to the longitudinal dural fibers decrease the incidence and severity of headache following inadvertent dural puncture?

Methods

Thomas Jefferson University Institutional Review Board approved our protocol. First year anesthesia residents, assigned to the labor floor, perform the majority of labor epidural anesthetics in our institution. At the beginning of their first obstetric anesthesia rotation, we randomly assigned each resident to identify the epidural space with the needle bevel oriented either parallel or perpendicular to the longitudinal dural fibers. The residents induced epidural analgesia at a lower lumbar interspace with the patient in either the upright or lateral decubitus position. After identifying the epidural space by loss of resistance to air or saline using a 17- or 18-g Hustead needle, the resident advanced a 19- or 20-g nylon catheter 2 to 3 cm cephalad and withdrew the needle. The residents trained to orient the needle bevel parallel to the longitudinal dural fibers rotated the epidural needle 90° before inserting the epidural catheter.

In the event of dural puncture, an obstetric anesthesia fellow or attending, unaware of the orientation of the needle bevel at the time of dural puncture, saw the patient daily until discharge. This observer assessed the presence and severity of any postpartum headache using a standardized headache severity scale (fig. 1). We offered the option of therapeutic epidural blood patch to women experiencing a moderate or severe headache that did not respond to 24 hours of conservative therapy. Conservative therapy consisted of bed rest, ibuprofen and po caffeinated fluid intake. We made no attempt to prevent headaches with bed rest, intravenous (iv) caffeine, or prophylactic epidural injection of saline or blood.

At the conclusion of our study, we used chi-square to determine the significance of any differences between the techniques in the incidence or severity of headache and considered $P < 0.05$ significant.

Results

Dural puncture occurred in 2.6% of all attempted epidural anesthetics. The needle bevel direction did not alter the risk of dural puncture (table 1). The incidence of dural puncture with 17- or 18-g needles in each group was similar. Dural puncture occurred twice in four of the 41 women in whom dural puncture occurred. Orienting the

* Assistant Professor of Anesthesiology.

† Instructor in Anesthesiology.

Received from the Department of Anesthesiology, Thomas Jefferson University, Philadelphia, Pennsylvania. Accepted for publication December 1, 1988. Presented to the Society of Obstetric Anesthesia and Perinatology San Francisco, California, May 1988.

Address reprint requests to Dr. Norris: Department of Anesthesiology, Jefferson Medical College, Philadelphia, Pennsylvania 19107.

Headache Severity Scale:**0 - No headache****1 - Mild headache, no interference with daily activities****2 - Moderate headache, ambulatory but some interference with daily activities****3 - Severe headache, bedridden****Headache Severity:**

Immediate day 1 day 2 day 3 day 4

Blood Patch: Yes No Date: _____

Comments: _____

FIG. 1. Headache severity scale. Patients were seen daily and headache graded as none, mild, moderate, or severe using these criteria.

needle bevel parallel to the longitudinal dural fibers significantly decreased both the incidence and severity of headache ($P < 0.03$) (fig. 2) and the need for therapeutic epidural blood patch ($P < 0.05$) (table 1). All women who received epidural blood patch obtained significant immediate pain relief and had complete resolution of their symptoms within 24 h.

Discussion

Beginning with Gaston Labat,³ some anesthesiologists have recommended orienting the needle bevel parallel to the spine while performing dural puncture. Franksson and Gordh⁴ demonstrated that if the needle bevel "is placed at right angles to the longitudinal direction of the dura, several longitudinal fibres in the inelastic dura will be cut off, with diminished prospects of rapid closing of the opening. If the bevelled part is held parallel with the direction of the fibres, they will be broken and a narrow slot-like opening will be obtained, with a greater tendency

TABLE 1. Results

	Perpendicular	Parallel	P Value
Epidurals	771	787	NS
No. of women who suffered dural punctures	20	21	
Needle size			
17 g	4	2	NS
18 g	16	19	
No. of dural punctures/patient			
1	19	18	NS
2	1	3	
Blood patch			
No	10	17	<0.05
Yes	10	4	

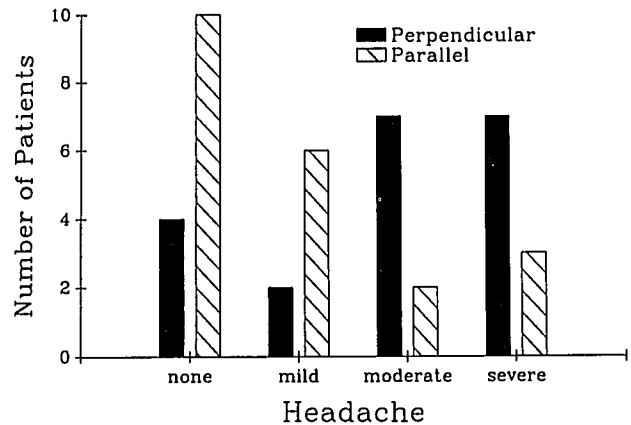


FIG. 2. Effect of needle bevel direction on headache severity. Orienting the needle bevel parallel to the longitudinal dural fibers significantly decreased the incidence and severity of headache ($P < 0.03$).

to contraction." They counted 80 torn dural fibers following dural puncture with the needle bevel held perpendicular but only 45 torn fibers following dural puncture with the needle bevel held parallel to the dural fibers. Clinically, Mihic,² using 22- or 25-g needles, reported a headache incidence of 16.1% following dural puncture with a perpendicular bevel orientation. The headache incidence declined to 0.24% (one headache in 420 non-pregnant patients) using the parallel insertion technique.

This study addressed the relation between headache and needle bevel orientation following dural puncture with larger gauge needles commonly used to identify the epidural space, 73% of parturients in whom dural puncture with a needle bevel perpendicular to dural fibers occurred developed a moderate to severe headache, whereas only 31% did so with a parallel needle bevel orientation. Similarly, the requirement for therapeutic blood patch decreased from 50% to 19% following dural puncture with the parallel insertion technique. These results support the proposal put forth by others²⁻⁴ that piercing the dura with the needle bevel oriented parallel to the longitudinal dural fibers minimizes the size of the dural tear and favors rapid healing.

A potential drawback of the parallel insertion technique as used in this study is the need to rotate the needle bevel 90° after identifying the epidural space to encourage cephalad passage of the epidural catheter. Experts differ with regard to the advisability of this maneuver. Bromage warned against rotation of an epidural needle once in the epidural space.⁵ However, Moore specifically recommended rotating the needle 270° with intermittent aspiration to detect partial dural perforation.⁶ A recent study suggested that rotating an epidural needle while advancing it toward the dura may increase the risk of dural puncture.⁷ In this study, we avoided advancing the needle further into the epidural space while turning it

and found no increased risk of complication in the parallel insertion group.

Factors other than needle bevel direction can potentially alter the incidence of postlumbar puncture headache. Headache incidence increases with increasing needle gauge.⁸ Differences in needle design (*i.e.*, sharp or dull bevels) might also influence the amount of trauma to the dura and the risk of subsequent headache. Intentional subarachnoid injection of large amounts (35–50 ml) or air when performing pneumoencephalography frequently causes a severe headache.⁹ Presumably subarachnoid injection of small amounts (<5 ml) of air during attempts to locate the epidural space (with the loss of resistance) technique would also occasionally cause a headache. In this study, we attempted to control for these and the myriad of other factors that might have influenced our results by having residents trained in either technique performing epidural anesthesia concurrently. Thus, similar numbers of women in each group suffered dural puncture with a 17-g needle (table 1). Four women in each group developed cephalgia immediately upon dural puncture, presumably because of subarachnoid air injection. Thus, the differences in incidence and severity of postdural puncture headache found in this study can reasonably be attributed to the needle bevel orientation rather than some other confounding variable.

In conclusion, this study demonstrates that identifying the epidural space with the needle bevel oriented parallel to the longitudinal dural fibers significantly decreases the risk of headache and the requirement for therapeutic epidural blood patch should dural puncture occur.

References

1. Craft JB, Epstein BS, Coakley CS: Prophylaxis of dural-puncture headache with epidural saline. *Anesth Analg* 52:228–231, 1973
2. Mihic DN: Postspinal headache and relationship of needle bevel to longitudinal dural fibers. *Reg Anesth* 10:76–81, 1985
3. Labat G: The trend of subarachnoid block. *Surg Clin North Am* 10:671–681, 1930
4. Franksson C, Gordh T: Headache after spinal anesthesia and a technique for lessening its frequency. *Acta Chir Scand* 94:443–454, 1946
5. Bromage PR: *Epidural Analgesia*, 2nd edition. Philadelphia, W. B. Saunders, 1978, p 195
6. Moore DC: *Regional Block*, 4th edition. Chicago, Charles C Thomas, 1965, p 145
7. Meiklejohn BH: The effect of rotation of an epidural needle. *Anaesthesia* 42:1180–1182, 1987
8. Albright GA: *Major regional anesthesia: Fundamental considerations*, *Anesthesia in Obstetrics, Maternal, Fetal, and Neonatal Aspects*, 2nd edition. Edited by Albright GA, Ferguson JE II, Joyce TH III, Stevenson DK. Boston, Butterworths, 1986, pp 227–268
9. White YS, Bell DS, Mellick R: Sequelae to pneumoencephalography. *J Neurol Neurosurg Psychiatry* 36:146–151, 1973