

## Anesthetic Management of Tetralogy of Fallot with Absent Pulmonary Valve

MICHAEL P. HOSKING, M.D.,\* FROUKJE BEYNEN, M.D.†

The syndrome of tetralogy of Fallot is characterized by biventricular origin of the aorta above a large ventricular septal defect (VSD), right ventricular hypertrophy, and pulmonary outflow obstruction. Absence of the pulmonary valve occurs in 2.6-6.0% of patients with tetralogy of Fallot.<sup>1-3</sup> Pulmonary regurgitation and massive dilatation of the main pulmonary artery and its first- and second-order branches is uniformly present.<sup>2-4</sup> Severe central and intrapulmonary bronchial compression may result secondary to aneurysmally dilated central pulmonary arteries and abnormal branching of segmental arteries, respectively.<sup>5-9</sup> These patients may present in infancy with severe respiratory compromise and require nursing while in the prone position to maintain airway patency.<sup>6</sup> We report the anesthetic implications and management of a case of tetralogy of Fallot with absent pulmonary valve in an infant who experienced severe respiratory distress in the supine position.

## REPORT OF A CASE

At birth the patient, a 2897-g, full-term male, was noted to be cyanotic and was transferred to our institution for evaluation. Tetralogy of Fallot with absent pulmonary valve syndrome was diagnosed by echocardiographic examination. The patient received digoxin and was acyanotic and without symptoms at discharge 3 days later. Over the next 12 wk, episodes of respiratory distress developed, increasing in frequency and severity. Because respiration was compromised in the supine position, a crib with an adjustable tilt board was constructed and the patient was maintained in the prone position at a 60° incline. Additional therapy included theophylline, isoetharine, chest physical therapy, and antibiotics for recurrent respiratory infections. At 3 mo of age, the patient was admitted for increasingly frequent cyanotic spells.

On admission, the patient, weighing 4.3 kg, presented with a blood pressure of 100/60 mmHg, pulse rate of 160 beats/min, and respiratory rate of 50 breaths/min. There was marked expiratory wheezing

in all lung fields and decreased breath sounds over the left upper lobe. The liver was enlarged. No peripheral edema was present. The cardiothoracic ratio on chest roentgenogram was 0.72 with markedly dilated pulmonary arteries, pulmonary vascular engorgement, hyperinflation of the left upper lobe, and left-sided aortic arch. Arterial blood gas analysis revealed a PaO<sub>2</sub> of 39 mmHg; P<sub>CO</sub><sub>2</sub> of 39 mmHg, and a pH of 7.38 with the child breathing 40% oxygen in a mist tent. Arterial hemoglobin was 10.3 g/dl and was 73% saturated. An ECG revealed normal sinus rhythm, rate of 150 with right ventricular hypertrophy.

Because severe cyanotic spells occurred when the patient was moved from the prone position, cardiac catheterization was not possible. A two-dimensional Doppler echocardiogram confirmed the diagnosis of tetralogy of Fallot with absent pulmonary valve. Moderate right ventricular outflow obstruction was present at the midcavity level secondary to a prominent anterior muscle band. The central pulmonary arteries were markedly dilated with normal relationships of the great arteries.

Upon arrival in the operating room, a blood pressure cuff, precordial stethoscope, ECG leads, and pulse oximeter sensor were appropriately placed and monitored. The patient was maintained in the semiprone position, with the operating room table in the reverse Trendelenburg position. A 22-g intravenous (iv) cannula was inserted into a scalp vein. While investigating whether tracheal intubation with the infant in the prone position would be possible after induction of anesthesia, insertion of the laryngoscope blade was well tolerated by the awake infant, and optimal visualization of the airway was achieved. Therefore, awake intubation in the prone position with a 4.0-mm endotracheal tube was performed without disturbing the infant or causing hemodynamic instability. Anesthesia was induced with fentanyl 58 µg/kg and muscle relaxation was achieved with pancuronium 1.0 mg. Ventilation was controlled with a minute volume of 1.8 l, rate of 25, and FiO<sub>2</sub> 0.40. The patient remained hemodynamically stable after being turned to the supine position and the airway (monitored by stethoscope) remained patent with positive pressure ventilation of 10 cmH<sub>2</sub>O PEEP. A 20-g 4-inch left femoral artery catheter, 5-Fr double-lumen central venous pressure (CVP) and an additional 22-g iv catheter in the right hand were inserted. Anesthesia was maintained with fentanyl (total dose 116 µg/kg), isoflurane 0.25% and air/oxygen. Arterial blood gas analysis prior to cardiopulmonary bypass (CPB) with FiO<sub>2</sub> of 0.4 revealed a PaO<sub>2</sub> of 64 mmHg, P<sub>CO</sub><sub>2</sub> of 47 mmHg, and a pH of 7.42.

Prior to CPB, mannitol 0.5 g/kg and dexamethasone 0.5 mg/kg were administered. After systemic heparinization, CPB was instituted, thiopental 8 mg/kg was administered, and the infant was cooled to 15° C. The aorta was crossclamped, 100 ml of cardioplegic solution delivered to the aortic root, and circulatory arrest was induced for 33 min. The VSD was closed, the right ventricular outflow tract was reconstructed with a 14-mm Hancock conduit, and the aneurysmally dilated pulmonary arteries were resected and plicated. Total CPB time was 154 min; the aorta was crossclamped for 36 min. Nitroprusside 1.0 µg · kg<sup>-1</sup> · min<sup>-1</sup> was used during weaning from CPB. The left ventricular pressure measured after CPB was 105/8 mmHg, and right ventricular pressure was 50/8 mmHg. A postoperative two-dimensional echocardiogram estimated a right ventricular pressure of 35 mmHg, indicating a normal pulmonary artery pressure.

\* Cardiovascular Anesthesia Fellow, Mayo Graduate School of Medicine, Rochester, Minnesota.

† Assistant Professor of Anesthesiology, Mayo Medical School; Consultant, Department of Anesthesiology, Mayo Clinic, Rochester, Minnesota.

Received from the Department of Anesthesiology, Mayo Clinic, Rochester, Minnesota. Accepted for publication December 9, 1988.

Address reprint requests to Dr. Beynen: Department of Anesthesiology, Mayo Clinic, 200 First Street SW, Rochester, Minnesota 55905.

Key words: Tetralogy of Fallot; ventricular septal defect.

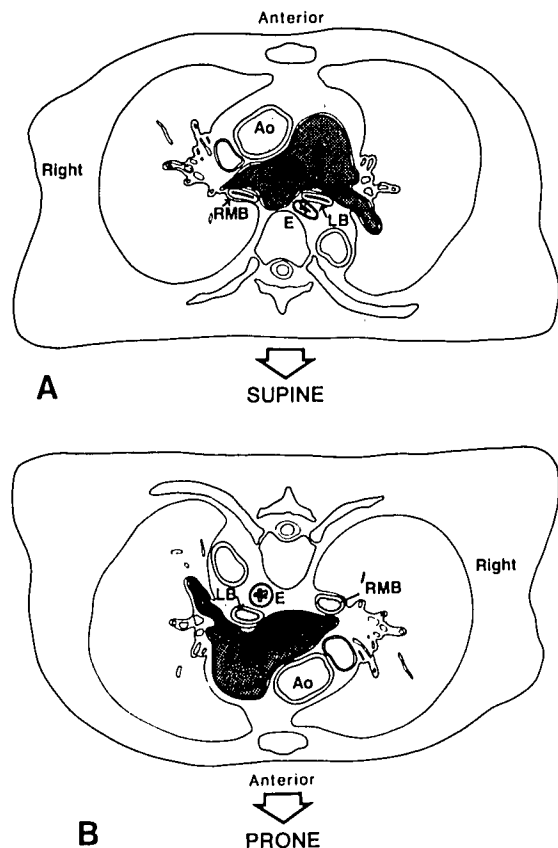


FIG. 1. A. Cross-sectional view (as viewed from the patient's feet) of a patient with tetralogy of Fallot and absent pulmonary valve. The aneurysmally dilated pulmonary arteries cause obstruction of the mainstem bronchi with the patient in the supine position. RPA = right pulmonary artery; RMB = right mainstem bronchus; LB = left mainstem bronchus; E = esophagus; AO = aorta. B. Patient in the prone position. Pulmonary arteries are displaced anteriorly and bronchial caliber improves. Reprinted from Arensman FW, Francis PD, Helmsworth JA, Benzing G III, Schreiber JT, Schwartz DC, Kaplan S: Early medical and surgical intervention for tetralogy of Fallot with absence of pulmonic valve. *J Thorac Cardiovasc Surg* 87:430-436, 1982, with permission.

The patient was transferred to the intensive care unit. Postoperatively, copious secretions were aspirated from the endotracheal tube from previously obstructed bronchi. Pulmonary care included chest physical therapy, ultrasonic nebulizer treatments, aminophylline, and isoetharine. Initially, the infant continued to be ventilated with 10 cm PEEP, which was gradually decreased and followed by 5 cm continuous positive airway pressure (CPAP) for several days. Following steady improvement, the trachea was extubated on the fifth postoperative day, and the infant was discharged from the hospital on the 12th postoperative day.

#### DISCUSSION

Patients with tetralogy of Fallot with absent pulmonary valve may present with a wide spectrum of symptoms, from asymptomatic with a normal lifespan to severe airway compromise and congestive heart failure manifested shortly after birth. Operative procedures to relieve re-

spiratory symptoms have been described in approximately 70 infants younger than 1 yr of age with an operative mortality of 35-100%.<sup>1,4-12</sup>

Respiratory compromise may be severe in these infants secondary to bronchial compression by the aneurysmally dilated pulmonary arteries. Elevated right ventricular pressures and the resultant high pulmonary artery pressures in combination with increased stroke volume (pulmonary valve insufficiency and VSD) create large pulsations in the pulmonary vessels, which may cause almost complete obliteration of the bronchial lumen during systole, more prominent during expiration than inspiration.<sup>8</sup> Although some patients with less severe airway compression tolerate a supine or lateral position, induction of anesthesia with the patient in the semiprone position may be necessary to maintain airway patency. The prone position will cause the pulmonary arteries to move toward the anterior chest wall and relieve bronchial compression (fig. 1). After tracheal intubation the patient can be moved to the supine position and the lungs auscultated as PEEP is gradually increased until breath sounds are equal and well distributed bilaterally. In this infant, 10 cmH<sub>2</sub>O PEEP was required. Gentle hyperinflation with suctioning and lavage may be successful in opening obstructed airways and relieving areas of atelectasis or air trapping. A flat stethoscope with adequate padding may be placed on the back of the infant over areas of atelectasis or hyperinflation for the purpose of monitoring ventilation and additional adjustments of PEEP intraoperatively.

Patients with the absent pulmonary valve syndrome may present a different hemodynamic profile than those with classic tetralogy of Fallot. The combination of a large VSD and only mild pulmonary stenosis generally results in left-to-right shunting (ratio of pulmonary-to-systemic blood flow of 1.5 to 3.3) after the physiologically elevated pulmonary resistance of the newborn period decreases.<sup>6,13</sup> Pulmonary insufficiency secondary to absence of the valve and the left-to-right shunt across the VSD result in volume overload of the right ventricle in addition to the increased pressure load caused by the outflow tract obstruction. This combination of mild obstruction to ventricular ejection with free valvular insufficiency results in the massive dilatation of the central pulmonary arteries.<sup>9</sup> In addition, these unique loading conditions predispose the right ventricle to failure. Respiratory maneuvers to maintain pulmonary vascular resistance and avoid increased left-to-right shunting include the use of high mean airway pressures (e.g., PEEP) and avoidance of hypocarbia and hyperoxia.<sup>14,15</sup> Prior to CPB ventilation was controlled to maintain a slightly elevated P<sub>CO<sub>2</sub></sub> and an air-oxygen mixture adjusted to obtain the lowest possible F<sub>I<sub>O<sub>2</sub></sub></sub> that would yield an arterial oxygen saturation of 90%.

The preferred surgical treatment of tetralogy of Fallot with absent pulmonary valve is complete repair utilizing

CPB. The hypertrophied infundibulum is resected if necessary and patch closure of the VSD is carried out. A right ventriculotomy is extended across the pulmonary valve ring with patch enlargement of the outflow tract. The aneurysmally dilated pulmonary arteries are resected or plicated back to normal proportions. In symptomatic infants, elimination of pulmonary insufficiency by prosthetic valve replacement is recommended.<sup>1,4</sup> After repair and delivery of a high  $FI_{O_2}$ , the lungs are hyperventilated to produce a respiratory alkalosis and consequent decreased pulmonary vascular resistance. The routine insertion of bilateral chest tubes at the end of surgery prevents the occurrence of tension pneumothorax, which may easily develop with hyperventilation in infants with both atelectatic and emphysematous lung fields. Elevated pulmonary vascular resistance, especially in infants with a right ventriculotomy, which may lead to right ventricular dysfunction, should be prevented. Furthermore, there is a higher incidence of increased bleeding post-CPB because of the extensive suture line in the pulmonary arteries. Therefore, if blood is needed for transfusion after the patient has been disconnected from CPB, well-oxygenated blood (with low  $P_{CO_2}$  and normal or alkaline  $pH$ ) from the bypass machine is hemoconcentrated by the autotransfusion device and is transfused instead of stored blood with low  $pH$ ,  $Pa_{O_2}$  and elevated  $P_{CO_2}$ , which may (when transfused rapidly) increase pulmonary vascular resistance and increase right ventricular workload.

Postoperative care requires aggressive chest physiotherapy and use of bronchodilators. Compression of the proximal and frequently also distal airways<sup>5</sup> *in utero* and postnatally may cause structural damage to the cartilaginous support of the airways. The postoperative course, frequently with prolonged ventilation or CPAP, should reveal whether surgical correction of the aneurysmally dilated proximal pulmonary arteries has been effective in relieving the respiratory obstruction. No improvement is to be expected, however, if the damage to the proximal airway is beyond recovery or if severe compression of the distal airway is present. A generous right ventriculotomy incision for the repair may seriously impair right ventricular contractility, and inotropic support and vasodilator therapy may be required in addition to hyperventilation and a high  $FI_{O_2}$ .

In conclusion, the anesthetic management of tetralogy of Fallot with absent pulmonary valve is reported. This rare congenital anomaly may result in severe positional airway compromise and right ventricular failure. The anesthetic management of this syndrome has not been previously reported. An understanding of the anatomic and

physiologic principles and their anesthetic implications will lead to improved management of these extremely ill infants.

#### REFERENCES

1. McCaughan BC, Danielson GK, Driscoll JD, McGoan DC: Tetralogy of Fallot with absent pulmonary valve: Early and late results of surgical treatment. *J Thorac Cardiovasc Surg* 89:280-287, 1985
2. Nagao GI, Daoud G, McAdams AJ, Schwartz DC, Kaplan S: Cardiovascular anomalies associated with tetralogy of Fallot. *Am J Cardiol* 20:206-215, 1967
3. Lev M, Eckner FAD: The pathologic anatomy of tetralogy of Fallot and its variants. *Chest* 45:251-261, 1964
4. Ilbawi MN, Idriss FS, Muster AJ, Wessel HU, Paul MH, DeLeon SY: Tetralogy of Fallot with absent pulmonary valve: Should valve insertion be part of the intracardiac repair? *J Thorac Cardiovasc Surg* 81:906-915, 1981
5. Rabinovitch M, Grady S, David I, Van Praagh R, Sauer U, Buhmeyer K, Castaneda AR, Reid L: Compression of intrapulmonary bronchi by abnormally branching pulmonary arteries associated with absent pulmonary valves. *Am J Cardiol* 50:804-813, 1982
6. Arensman FW, Francis PD, Helmsworth JA, Benzing G III, Schreiber JT, Schwartz DC, Kaplan S: Early medical and surgical intervention for tetralogy of Fallot with absence of pulmonary valve. *J Thorac Cardiovasc Surg* 84:430-436, 1982
7. Stellin G, Jonas RA, Goh TH, Brawn WJ, Venables AW, Mee RBB: Surgical treatment of absent pulmonary valve syndrome in infants: Relief of bronchial obstruction. *Ann Thorac Surg* 36:468-475, 1983
8. Corno A, Picardo S, Ballerini L, Gugliantini P, Marcelletti C: Bronchial compression by dilated pulmonary artery: Surgical treatment. *J Thorac Cardiovasc Surg* 90:706-710, 1985
9. Ilbawi MN, Fedorchik J, Muster AJ, Idriss FS, DeLeon SY, Gidding SS, Paul MH: Surgical approach to severely symptomatic newborn infants with tetralogy of Fallot and absent pulmonary valve. *J Thorac Cardiovasc Surg* 91:584-589, 1986
10. Dunnigan A, Oldham HN, Benson DW: Absent pulmonary valve syndrome in infancy: Surgery reconsidered. *Am J Cardiol* 48:117-122, 1981
11. Agarwal KC, Khan MAA, Karpawich PP, Amato JJ: Successful surgical repair of absent pulmonary valve syndrome in infancy. *Am Heart J* 109:174-177, 1985
12. Karl TR, Musumeci F, de Leval M, Pincott JR, Taylor JFN, Stark J: Surgical treatment of absent pulmonary valve syndrome. *J Thorac Cardiovasc Surg* 91:590-597, 1986
13. Cheatham JP, Latson LA, Gutgesell HP: Echocardiographic pulsed Doppler features of absent pulmonary valve syndrome in the neonate. *Am J Cardiol* 49:1773-1777, 1982
14. Drummond WH, Gregory GA, Heymann G, Phibbs RA: The independent effects of hyperventilation, tolazoline, and dopamine in infants with persistent pulmonary hypertension. *J Pediatr* 98:603-611, 1981
15. Ferrara B, Johnson DE, Chang PN, Thompson TR: Efficacy and neurologic outcome of profound hypocapnic alkalosis for the treatment of persistent pulmonary hypertension in infancy. *J Pediatr* 105:457-461, 1984