

FIG. 1. Reusable sensor secured to signal cable by $\frac{1}{8}$ -inch metal cabling.

was instituted with the reusable sensor that securely fastened the reusable sensor to the Nellcor® patient signal cable by means of $\frac{1}{8}$ -inch metal cabling and loop sleeves* such that the reusable sensor could not be separated from the patient cable without using large cable cutters (fig. 1).

All ORs were converted to using reusable sensors secured with cabling in October, 1987. Disposable sensors are still available in the OR—there are some instances in which only they will work, e.g., small pediatric patients. When this occurs, the reusable sensor is simply unplugged from the patient cable connector (slid up the patient cable and out of the way) and the disposable sensor plugged in its place. In addition, when the infrequent report of a failed reusable sensor does occur, disposable sensors can be used temporarily until a technician checks out the reported failure, cuts the securing cable, and replaces the failed reusable sensor. Many reported sensor failures are loose connections, bad patient cables, or operator error.

Since our conversion from all disposable to all reusable pulse oximeter sensors, the cost per patient use for the department has been

reduced from \$2.73 to \$1.09, which includes the cost of replacing broken reusable sensors, with annual savings last year of over \$42,000.

In a large teaching department such as ours, securing the reusable pulse oximeter sensor to the patient cable was necessary to insure against loss and encourage management to be a part of the replacement process. Smaller Anesthesia departments or hospitals may not need this measure of control. It appears reusable pulse oximeter sensors are very cost effective when used routinely.

GARY F. MARUSCHAK, R.C.P.T.
Manager, Supplies and Equipment

ROBERT M. JOHNSON, R.C.P.T.
Administrator

*Department of Anesthesiology and Critical Care Medicine
The Johns Hopkins Hospital
601 North Broadway
Baltimore, Maryland 21205*

(Accepted for publication March 16, 1989.)

* Small Parts, Inc., Miami, Florida 33238-1736

Cool Fingers and Pulse Oximetry

To the Editor:—Frequently, intraoperative monitoring of patients via pulse oximetry is inhibited during a surgical procedure when the pulse oximeter fails to detect pulsation, from which arterial oxygen saturation is estimated. Hemodynamically the patient may be stable, but, on palpation, may have cool extremities. Because we did not think passive heating, which has been used in the past, would be helpful during this particular case, we devised an alternative solution to this problem.

While monitoring a patient undergoing radical prostatectomy with the D25 probe of a Nellcor® N100 pulse oximeter placed on the pa-

tient's right first finger, the oximeter ceased to function, despite effective shielding from ambient light interference. We palpated the patient's fingers, found they were quite cool, and therefore assumed the loss of signal was due to inadequate pulse amplitude. We loosely wrapped the patient's forearm with a pediatric warming blanket, connected it to the warming source, and set the temperature at 39° C. After approximately 15 min, pulsation in the finger was reestablished and the pulse oximeter resumed readings of SpO₂. We placed an adult D25 Nellcor® finger probe on the first finger of the patients opposite hand, but pulsation was not detected. We then measured the skin tem-

perature of the distal finger pad on the adjacent index finger and found the temperature of the pad to be 25.2° C while that on the warmed extremity was 32.8° C. Esophageal temperature was 35.5° C.

We recommend this technique for use in a patient with cool fingers and in whom the pulse oximeter is not detecting pulsation.

DAVID A. PAULUS, M.D., M.S.
*Associate Professor of Anesthesiology and
Mechanical Engineering*

MARK C. MONROE, M.D.
Resident in Anesthesiology

*Colleges of Medicine and Engineering
University of Florida College of Medicine
Gainesville, Florida 32610-0254*

(Accepted for publication March 23, 1989.)

Anesthesiology
71:169, 1989

Acute Treatment after Accidental Intrathecal Injection of Hypertonic Contrast Media

To the Editor:—Acute neurotoxicity of hypertonic solutions of contrast media is well established in experimental studies¹⁻² and in humans.³ However, until now, no treatment has been proposed. We describe a treatment used in one case of accidental intrathecal injection of hypertonic solution of meglumine amidotrizoate (Angiografin®).

A 69-year-old, 80-kg man with a history of inferior myocardial infarction and colon carcinoma with pulmonary and painful coccygeal

metastases was scheduled for insertion of a thoracic intrathecal catheter with an implantable pump for intrathecal opioid administration. In order to verify the position of the catheter in the subarachnoid space, 10 ml of hypertonic solution of contrast media was accidentally injected through the reservoir of the implantable device (fig. 1). Concomitantly, signs of neurotoxicity, including spastic paraparesis, cutaneous hyperesthesia, spontaneous pain of the lower extremities, and cardiovascular effects including tachycardia 150 bpm and ST segment depression, occurred. The patient was immediately admitted to the intensive care unit where an effort was made to dilute the contrast media by infusion of saline into the subarachnoid space. A second catheter was inserted into the lumbar subarachnoid space via the L4-L5 interspace and sterile saline was injected in 10 ml aliquots up to a total of 180 ml. After each injection of 10 ml of sterile saline 10 ml of cerebrospinal fluid were withdrawn through the lowest catheter. Cardiovascular and neurological signs soon disappeared and no sequelae were noted 24 h later.

JACK TARTIERE, M.D.
JEAN-LOUIS GERARD, M.D.
Assistant in Anesthesiology

JEAN PENY, M.D.
JEAN-MICHEL HURPE, M.D.
Assistant in Anesthesiology

JACQUES QUESNEL, M.D.
Professor of Anesthesiology

*Département d'Anesthésiologie
Hôpital Côte de Nacre
14033 CAEN Cedex, France*

REFERENCES

1. Oftedal S-I, Kaye K: Epileptogenic effect of water-soluble contrast media: An experimental investigation in rabbits. *Acta Radiol [Suppl] (Stockh)* 335:45-56, 1973
2. Salvesen S, Nilsen PL, Holterman NH: Effects of calcium and magnesium ions on the systemic and local toxicities of the N methylglucamine (meglumine) salt of metrizoic acid (Isopaque). *Acta Radiol [Suppl] (Stockh)* 270:180-193, 1966
3. Junck L, Marshall WH: Neurotoxicity of radiological contrast agents. *Ann Neurol* 13:169-484, 1983

(Accepted for publication March 23, 1989.)

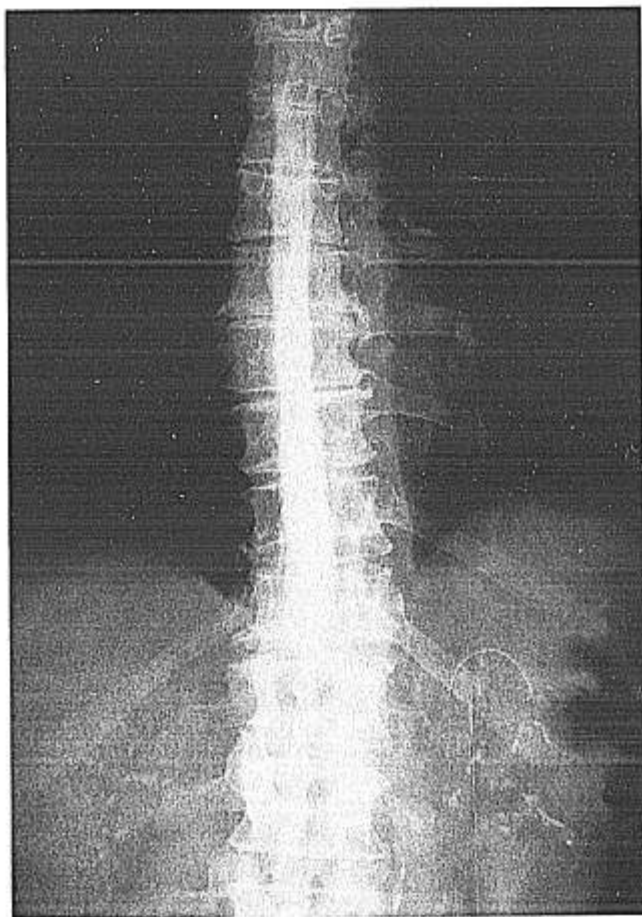


FIG. 1. Radiography after injection of the hypertonic solution of the contrast media through the reservoir of the implantable device showing the subarachnoid space and the renal opacification.