

Although not routinely used at our institution, mass spectrometers and infrared gas analyzers are available that can measure inspired and expired anesthetic agents concentrations. A recent case report describes the detection of mixed anesthetic agents by mass spectrometry during anesthesia.⁹

Pending definitive recommendations from the manufacturer, our department now requires that the function of the vapor exclusion system of all Narkomed machines be checked every month, including a physical check of the tightness of the Allen screws and jam nuts.

REFERENCES

1. Pierce EG, Cooper JB: Equipment-related anesthetic incidents. *Int Anesthesiol Clin* 22:133-147, 1984
2. Miller RD: *Anesthesia*. New York, Churchill Livingstone Inc., 1986, pp 399-408

Anesthesiology
71:291-294, 1989

Esmolol for Perioperative Management of Thyrotoxic Goiter

ALISA C. THORNE, M.D.,* ROBERT F. BEDFORD, M.D.†

Although optimal perioperative management of patients with thyrotoxicosis should include rendering the patient euthyroid prior to surgery, this may not always be possible. In such circumstances, beta-adrenergic blockade with an agent such as propranolol has become standard therapy.¹⁻³ This case report describes the use of the ultra-short acting beta-blocking drug, esmolol, for perioperative management of a patient who required surgical excision of a large toxic goiter that was refractory to both propranolol and high-dose antithyroid medications.

CASE REPORT

A 19-yr-old, 57-kg woman who smoked ½ pack of cigarettes per day presented with a 1-yr history of hyperthyroidism and progressive thyroid enlargement requiring surgical excision due to impending airway compromise. She had been treated with methimazole, 15 mg tid,

3. Dorch JA, Dorch SE: Understanding anesthesia equipment: Construction care and complications. Baltimore, Williams and Wilkins, 1984, pp 125-126
4. Cooper JB, Newbower RS, Long CD, McPeck B: Preventable anesthesia mishaps: A study of human factors. *ANESTHESIOLOGY* 49:399-406, 1978
5. Cooper JB, Newbower RS, Kitz RJ: An analysis of major errors and equipment failures in anesthesia management: Considerations for prevention and detection. *ANESTHESIOLOGY* 60:34-42, 1984
6. Craig J, Wilson ME: A survey of anesthetic misadventures. *Anesthesia* 36:933-936
7. Utting JE, Gray TC, Sheely FC: Human misadventure in anesthesia. *Can Anaesth Soc J* 26:472-478, 1979
8. Kumar V, Hintze MS, Sacob AM: A random survey of anesthesia machines and ancillary monitors in 45 hospitals. *Anesth Analg* 67:644-649, 1988
9. Munshi C, Dhamee S, Bardeen-Henschel A, Dhruva S: Recognition of mixed anesthetic agents by mass spectrometer during anesthesia. *J Clin Monit* 2:121-124, 1986

and propranolol, 80 mg tid, with unsatisfactory control of her hyperthyroidism. After 2 weeks of pretreatment with strong potassium iodide solution (Lugol's), surgery was attempted at an outside hospital. It was reported that during attempted awake tracheal intubation she developed a tachyarrhythmia, with a ventricular rate over 220/min, necessitating cancellation of surgery.

After transfer to our hospital initial thyroid function tests (TFTs) were: serum T4 = 238 ng/ml (normal = 45-120) and serum T3-RAI = 13.8 ng/ml (normal = 0.8-2.0). Methimazole and propranolol were increased to 40 mg and 80 mg, q 6 h, respectively. During the second week of hospitalization, saturated solution potassium iodide (SSKI) was begun, three drops every 6 h. On the day prior to surgery, the serum T4 was 95 ng/ml. Although the T3-RAI had decreased considerably, the values plateaued at twice normal, in the 3.8-4.0 range, and the methimazole was increased to 40 mgs q 3 h.

Since the patient apparently could not be made euthyroid with medical therapy alone, it was decided to proceed with surgery, despite obvious symptoms of thyrotoxicosis.

Preanesthetic physical exam revealed BP = 135/65, and HR = 84-88, despite propranolol therapy. There was ophthalmopathy and proptosis; it was reported that the patient's eyes did not close when she slept. She had a large, tender goiter involving both sides of the neck up to the mandible, making swallowing difficult and painful (fig. 1). She complained of fatigue, generalized weakness, perspiration, nervousness, emotional lability, shortness of breath, and dyspnea on exertion. She was hoarse and could not lie flat in bed without a feeling of suffocation. When lying upright at a 60° angle she displayed a normal respiratory rate, 16-18/min, and a normal pattern of breathing.

Preoperative EKG revealed normal sinus rhythm, left ventricular hypertrophy, and strain. An echocardiogram was normal. A computerized tomographic scan of the neck revealed moderate tracheal narrowing and a chest roentgenogram demonstrated a 4-cm segment of cervical trachea narrowed to a diameter of 1 cm, compared with a

* Assistant Professor of Anesthesiology.

† Professor of Anesthesiology.

Received from the Department of Anesthesiology and Critical Care Medicine, Memorial Sloan-Kettering Cancer Center and Cornell University Medical College, New York, New York.

Address reprint requests to Dr. Thorne: 1275 York Avenue, New York, New York 10021.

Key words: Complications: thyrotoxicosis. Hormones: pretreatment; thyroid. Surgery: thyroidectomy. Sympathetic nervous system, beta adrenergic antagonists: esmolol.

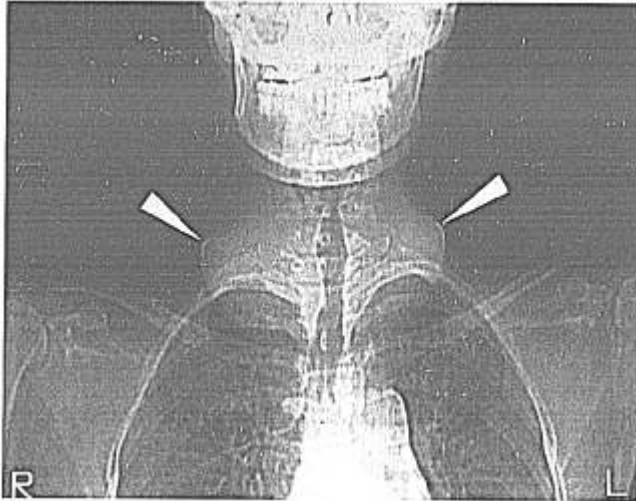


FIG. 1. Chest roentgenogram demonstrating enlarged thyroid (arrows) and airway narrowing.

tracheal diameter of 1.5 cm above and 1.8 cm below the narrowing. Pulmonary function tests: forced vital capacity (FVC)—81% of predicted; forced expiratory volume 1 second (FEV1)—52% of predicted; FEV1/FVC—52%; peak expiratory flow (PEF)—32%; expiratory flow rate (FEF) 25–75%—39% of predicted. A flow-volume loop was consistent with a fixed extrathoracic airway obstruction. Additional preoperative laboratory data included: hematocrit—30.5%; alkaline-phosphatase—281 units/l (normal—30–110); calcium—9.6 mg/dl; phosphorous—5.8 mg/dl (normal = 2.2–4.2).

The patient received meperidine, 75 mg, hydroxyzine, 50 mg and glycopyrrolate, 0.2 mg, im 1 h before coming to the operating room. She was well sedated and was transported to the OR while in the sitting position. Initial BP was 128/70, HR was 75. Immediately after EKG and automatic BP cuff were applied, esmolol iv was infused at a rate of $53 \mu\text{g} \cdot \text{kg}^{-1} \cdot \text{min}^{-1}$. Midazolam, 1 mg iv was given and 4% lidocaine, 160 mg, was administered topically to the upper airway *via* nebulizer and face mask. After preoxygenation, general anesthesia was induced with the patient in the sitting position using thiopental, 75 mg iv, 70% N_2O in O_2 and isoflurane *via* face mask with spontaneous ventilation. Once a deep level of anesthesia was obtained, she received lidocaine,

100 mg iv, and laryngoscopy was performed without the use of neuromuscular blockade. The larynx was difficult to visualize because of the large anterior neck mass which effectively decreased the submental space. However, the epiglottis was visualized using a No. 3 MacIntosh blade and a 6-mm endotracheal tube was inserted on the first attempt. A 4.5 mm diameter fiberoptic bronchoscope also was ready for use in the event that a difficult intubation was encountered. The automatic noninvasive BP device provided satisfactory cardiovascular monitoring both before and during the brief induction period. In order to minimize the patient's pain and anxiety, a radial arterial cannula was inserted after she was unconscious. An intraoperative arterial blood gas obtained 1 h after surgical incision revealed: ($\text{FI}_{\text{O}_2} = 28\%$) $\text{pO}_2 = 137$, $\text{pCO}_2 = 42$, $\text{pH} = 7.40$, $\text{HCO}_3 = 26$, $\text{SAO}_2 = 99\%$. Hemoglobin oxygen saturation as measured by a pulse oximeter was 99–100% throughout the perioperative period.

Anesthesia was maintained with isoflurane and N_2O in O_2 , fentanyl, 250 μg iv, and vecuronium. Esmolol infusion was titrated between 15 and 132 $\mu\text{g} \cdot \text{kg}^{-1} \cdot \text{m}^{-1}$ in an attempt to keep HR = 60–80, and systolic BP = 90–110 mmHg. On emergence from anesthesia, the dose requirement for esmolol increased markedly, from 132 $\mu\text{g} \cdot \text{kg}^{-1} \cdot \text{m}^{-1}$ to 316 $\mu\text{g} \cdot \text{kg}^{-1} \cdot \text{m}^{-1}$ (fig. 2). Prior to extubation, laryngoscopy was considered in order to check for edema or vocal cord paralysis, but because of our concern that the additional stimulation might precipitate cardiac manifestations of thyrotoxicosis, we elected to remove the endotracheal tube without laryngoscopy. Instead, the patient was observed in the operating room for several minutes for signs of airway obstruction after extubation. She was then transferred to the PACU. Pathological examination revealed a 370-g multinodular goiter.

In the PACU, the esmolol dose requirement initially increased to 351 $\mu\text{g} \cdot \text{kg}^{-1} \cdot \text{m}^{-1}$, when the BP and HR reached 170/90 and 100, respectively. Esmolol was then gradually decreased over the next 30 min to 211 $\mu\text{g} \cdot \text{kg}^{-1} \cdot \text{m}^{-1}$. Three hours later, propranolol, 80 mg PO was administered, and esmolol infusion was decreased to 102 $\mu\text{g} \cdot \text{kg}^{-1} \cdot \text{m}^{-1}$ soon thereafter. Ten hours postoperatively, esmolol was discontinued. She remained in the PACU overnight and was discharged to the floor the following morning. The postoperative course was uncomplicated except for mild hypocalcemia (7.4–8.0 mg/dl) which was treated successfully with calcium gluconate and calcium carbonate. No additional thyroid studies were performed. By the time of hospital discharge, her propranolol requirement had been reduced to 20 mg q 6 h.

DISCUSSION

It is relatively unusual to encounter frank thyrotoxicosis in contemporary anesthesia practice, particularly since preoperative beta-adrenergic blockade is usually successful in ameliorating the signs and symptoms not adequately controlled by antithyroid medication. In this case, despite maximal medical therapy, including propranolol, our patient displayed chemical and clinical signs of thyrotoxicosis. The T3-RAI remained double the upper limit of normal and she continued to have symptoms of hyperthyroidism: fatigue, generalized muscle weakness, dyspnea, perspiration, nervousness, and emotional lability. Her resting HR of 84–88 and BP of 135/65 were worrisome because they were higher than would be expected for a patient receiving propranolol, 480 mg/day. In hyperthyroidism, resting heart rate does not give a reliable indication of the degree of β -blockade^{4,5} and perioperative thyroid crises have been reported in propranolol-treated

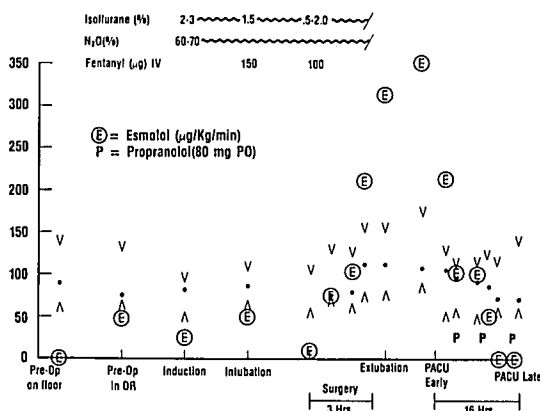


FIG. 2. Systolic and diastolic blood pressure (mmHg), heart rate (beats \cdot min⁻¹) and esmolol infusion rate before, during, and after thyroidectomy.

patients with preoperative pulse rates of 90/min or less.⁶⁻⁸

To our knowledge, use of esmolol for control of perioperative thyrotoxicosis has not been described previously. The rapid onset of action and ultra-short duration of esmolol make it ideally suited for use as a continuous iv infusion in situations where sudden changes in sympathetic tone are expected.⁹ Since we doubted that the degree of preoperative β -blockade was adequate for our patient, it seemed prudent to begin the esmolol infusion as soon as she entered the operating room. It has long been recognized that simply the fear and anxiety of being transported to the operating room can induce thyroid storm.^{10,11} Likewise, we were able to adjust the degree of β -blockade to match the patient's rapidly changing status before, during, and after anesthesia. Thus, it was possible to prevent tachycardia and hypertension that might otherwise have developed during laryngoscopy, intubation, surgical stimulation, and manipulation of the thyroid gland.³ Furthermore, we found the rapid titratability of esmolol to be helpful in treating the hypertension and tachycardia that developed briefly in the immediate postoperative period. Since the most likely time for presentation of thyroid storm is 6-18 h postoperatively,¹² and since the patient required ongoing β -blockade postoperatively, the esmolol infusion was continued for a total of 10 h after surgery was completed.

Propranolol has long been one of the drugs of choice for preoperative preparation and management of thyrotoxicosis, yet there are several reasons why propranolol is not an ideal drug in this setting. Thyrotoxic patients display a wide variability in circulating concentrations of propranolol for any given oral dose.⁴ They require a higher dosage to obtain the same degree of β -blockade as normals,¹³ and plasma propranolol levels are 40-50% lower than normals receiving the same chronic oral dosage. These factors may explain the occasional failure of propranolol when used alone or in combination with antithyroid agents in preventing thyroid storm.⁴ Other factors, including age and smoking, are also known to influence the metabolism of propranolol. Our patient was both young, 19 yr, and a cigarette smoker; two factors associated with subtherapeutic propranolol levels.¹⁴ In fact, two previous reports of thyroid storm developing despite propranolol treatment occurred in patients who were 24 and 30 yr.⁷

In addition to the unpredictable and highly variable plasma levels resulting from a given propranolol dose, further problems with oral administration arise in the perioperative period. Delayed postoperative reinstatement of propranolol because of somnolence, nausea, or vomiting may result in a rapid decline in plasma levels, thus explaining the fact that thyroid storm most commonly

occurs 6-18 h postoperatively.¹² Intravenous propranolol may also be problematic; not only does it have a relatively slow onset, but it has a relatively long duration of action that may mask tachycardia indicative of postoperative hypoxemia or hypovolemia. In summary, in a rapidly fluctuating clinical condition, such as perioperative thyrotoxicosis, propranolol may be too short-acting to be effective when administered orally and too long-acting to be safe when administered intravenously.

To our knowledge, no studies have been performed examining the pharmacokinetics of esmolol in thyrotoxicosis. Esmolol is primarily metabolized by esterases, in blood and liver.⁹ Although the blood esterases appear to be the primary component responsible for esmolol elimination, the liver is also an important factor because blood esterases are synthesized in the liver.⁹ Also, the liver synthesizes plasma proteins which can bind esmolol and its metabolites.⁹ We found it necessary to exceed the manufacturer's maximum dosage recommendation ($300 \mu\text{g} \cdot \text{kg}^{-1} \cdot \text{m}^{-1}$) for at least a short period of time in the postoperative period, and we suspect that higher-than-normal doses of esmolol may be necessary to control thyrotoxicosis, perhaps as a consequence of a generalized accelerated metabolic rate. The risk of high-dose esmolol is excessive myocardial depression. Recent work, both in patients with coronary artery disease and in normal humans, has shown that high doses of esmolol, $>400 \mu\text{g} \cdot \text{kg}^{-1} \cdot \text{m}^{-1}$, cause impairment of left ventricular function.^{21,22} This was not evident, however, when our patient was being treated for hypertension and increased heart rate postoperatively.

A final advantage of esmolol is the fact that it is a selective agent for beta-1-adrenoreceptor blockade. Thus, a number of reports have described the superiority of esmolol over propranolol when administered to patients at risk for bronchospasm due to beta-2-adrenoreceptor blockade.¹⁵⁻¹⁷ ‡ In addition, esmolol has been shown to specifically block the β -1 receptor effects of a generalized increase in sympathetic activity,¹⁷ whereas propranolol produces nonspecific β -adrenergic blockade involving both cardiac and peripheral vascular beta adrenergic receptors.¹⁸⁻²⁰

In conclusion, we found esmolol to be ideally suited for use in thyrotoxicosis, a clinical setting that requires rapid titration of β -blockade to control potentially life-threatening perioperative autonomic and hemodynamic fluctuations. When a thyrotoxic patient must undergo surgery, we recommend esmolol as an important adjunct to their anesthetic management.

‡ Morganroth J: Esmolol: An ultrashort-acting B-blocker for the ICU. Hospital Physician, May 1987, pp 22-32.

REFERENCES

- Hamilton WF, Forrest AL, Gunn A, Peden NR, Feely J: Beta-adrenoceptor blockade and anesthesia for thyroidectomy. *Anaesthesia* 39:335-342, 1984
- Strube PJ: Thyroid storm during beta-blockade. *Anaesthesia* 39: 343-346, 1984
- Trench AJ, Buckley FP, Drummond GB, Arthur GR, Scott DB: Propranolol in thyrotoxicosis. Cardiovascular changes during thyroidectomy in patients pre-treated with propranolol. *Anaesthesia* 33:535-535, 1978
- Feely J, Forrest A, Gunn A, Hamilton W, Stevenson I, Crooks J: Propranolol dosage in thyrotoxicosis. *J Clin Endocrinol Metab* 51:658-661, 1980
- Carruthers SG, Ghosal A, McDevitt DG, Nelson JK, Shanks RG: The assessment of B-adrenoceptor blocking drugs in hyperthyroidism. *Br J Clin Pharmacol* 1:93-98, 1974
- Ljunggren JG, Persson B: Pre-operative treatment of thyrotoxicosis with a beta-adrenergic blocking agent. *Acta Chir Scand* 141: 715-718, 1975
- Eriksson M, Rubinfeld S, Garber AJ, Kohler PO: Propranolol does not prevent thyroid storm. *N Engl J Med* 296:263-264, 1977
- Feely J, Crooks J, Forrest AL, Hamilton WF, Gunn A: Propranolol in the surgical treatment of hyperthyroidism, including severely thyrotoxic patients. *Br J Surg* 68:865-869, 1981
- Sum CY, Yacobi A, Kartzinel R, Stampfli H, Davis CS, Lai CM: Kinetics of esmolol, an ultra-short-acting beta blocker, and of its major metabolite. *Clin Pharmacol Ther* 34:427-434, 1983
- Artusio F Jr: Thyrotoxicosis: Anesthesiology. Problem Oriented Patient Management. Edited by Yao FSF, Artusio F Jr. Philadelphia, JB Lippincott Co., 1983, pp 223-233
- Ingbar SH: Management of emergencies IX. Thyrotoxic storm. *N Engl J Med* 274:22:1252-1254, 1966
- Tasch MD: Endocrine Diseases. Anesthesia and Co-existing Disease. Edited by Stoelting RK, Dierdorf SF. New York, Churchill Livingstone Inc., 1983, pp 437-483
- Feely J, Stevenson IH, Crooks J: Increased clearance of propranolol in thyrotoxicosis. *Ann Intern Med* 94:472-474, 1981
- Vestal RE, Wood AJJ, Branch RA, Shand DG, Wilkinson GR: Effects of age and cigarette smoking on propranolol disposition. *Clin Pharmacol Ther* 26:8-15, 1979
- Lowenthal DT, Porter RS, Saris SD, Bies CM, Slegowski MB, Staudacher A: Clinical pharmacology, pharmacodynamics and interactions with esmolol. *Am J Cardiol* 56:14F-17F, 1985
- Sheppard D, DiStefano S, Byrd RC, Eschenbacher WL, Bell V, Steck J, Laddu A: Effects of esmolol on airway function in patients with asthma. *J Clin Pharmacol* 26:169-174, 1986
- Menkhaus PG, Reves JG, Kissin I, Alvis JM, Govier AV, Samuelson PN, Lell WA, Henling CE, Bradley E: Cardiovascular effects of esmolol in anesthetized humans. *Anesth Analg* 64:327-334, 1985
- Safwat AM, Reitan JA, Misle G, Hurley EJ: Use of propranolol to control rate-pressure product during cardiac anesthesia. *Anesth Analg* 60:732-735, 1981
- Achong MR, Piafsky KM, Ogilvie RI: The effects of timolol (MK950) and propranolol on peripheral vessels in man. *Clin Pharmacol Ther* 17:228, 1975
- Sill JC, Nugent M, Moyer TP, Torres LE, Schaff HV, Tinker JH: Influence of propranolol plasma levels on hemodynamics during coronary artery bypass surgery. *ANESTHESIOLOGY* 60:455-463, 1984
- Reves JG, Croughwell N, Hawkins E, Jacobs JR: Esmolol for treatment of intraoperative tachycardia and/or hypertension—Bolus loading technique. *ANESTHESIOLOGY* 67:3A, 1987
- Edmondson RH, DelValle OE, Shah N, Dwyer D, Matarazzo D, Thorne A: Hemodynamic impact of esmolol during nitropruside-induced hypotension. *Anesth Analg* 68:S77, 1989

Anesthesiology
71:294-295, 1989

Severe Increase of Intracranial Pressure after Deflation of a Pneumatic Tourniquet

LCDR KELLY R. CONATY, M.C., U.S.N.,* LCDR MICHAEL S. KLEMM, M.C., U.S.N.R.†

The pneumatic tourniquet as first described by Cushing¹ in 1904 to obtain a bloodless field is frequently used in orthopedic surgical procedures. Anesthesia for multiply injured patients is also a common occurrence.

We report a case of an acute severe increase in intracranial pressure after release of a pneumatic tourniquet for lower extremity surgery in a patient with multiple trauma including closed head injury.

REPORT OF A CASE

A 27-yr-old man involved in a motor vehicle accident was found unresponsive at the scene of the accident with dilated and unresponsive pupils, but with stable vital signs. The patient was transported to a nearby local hospital where his Glasgow Coma Score was 8 upon admission to the emergency room. His trachea was intubated, and hyperventilation instituted. After stabilization, which included iv administration of mannitol, he was transferred to our hospital. Injuries on admission included closed head injury, multiple lacerations and abrasions, right scapular fracture, right clavicular fracture, right second and third rib fractures, left humerus fracture, right tibia and fibular fractures, right hemo-pneumothorax, and hemo-peritoneum. On admission, the patient localized to pain, opened his eyes in response to

* Resident Anesthesiologist, Naval Hospital, Oakland.

† Attending Staff Anesthesiologist, Naval Hospital, Oakland.

Received from the Department of Anesthesiology, Naval Hospital, Oakland, California. Accepted for publication March 13, 1989.

The Commander, Naval Medical Command, Washington, D.C., sponsored this Clinical Investigation Program case report 89-48-1970-96. The opinions or assertions expressed herein are those of the authors and are not to be construed as official or as necessarily reflecting the views of the Department of the Navy or of the Naval service at large.

Address reprint requests to LT Conaty: Naval Hospital, Oakland, California 94627-5000.

Key words: Brain: cerebral perfusion pressure; intracranial pressure. Carbon dioxide: intracranial pressure. Surgery, orthopedic: pneumatic tourniquet.