

Anesthesiology  
71:305-308, 1989

## Continuous Epidural Lidocaine Infusion in the Parturient with Paroxysmal Ventricular Tachycardia

MUSHTAQUE M. JUNEJA, M.D., F.F.A.R.C.S., WILLIAM E. ACKERMAN, M.D., DAVID M. KACZOROWSKI, D.O.,  
DAVID G. SOLLO, M.D., LESLIE F. GUNZENHAUSER, M.D.

Paroxysmal ventricular tachycardia (PVT) is usually associated with organic heart disease but can occur in patients with structurally normal hearts.<sup>1-3</sup> PVT is defined as a rapid succession of three or more ectopic ventricular beats occurring at rates greater than 100/min and originating from a focus below the bundle of His.<sup>4-5</sup> PVT during pregnancy has been previously described.<sup>6-8</sup> However, we are not aware of any case reports of PVT with reference to its anesthetic management during labor and cesarean delivery. We are reporting this single case of PVT in a patient in labor because of several interesting factors: 1) the presence of PVT during labor in two successive pregnancies; 2) increase in the frequency of PVT with uterine contractions; and 3) the disappearance of PVT and premature ventricular contractions after a continuous epidural lidocaine infusion.

### CASE REPORT

A 20-yr-old black female at 38 weeks gestation in active labor was transferred to our institution because of the presence of multiple premature ventricular contractions on her EKG. Her regular prenatal clinic examinations were unremarkable. Prior to this admission she had had a negative cardiac history. She was a nonsmoker with no history of palpitations, hypertension, chest pain, or syncope. There was no family history of cardiac problems. The only medications that she received during pregnancy were iron and multivitamins. A prenatal cardiology consultation was done with subsequent Holter monitoring. The 24 h Holter ambulatory EKG revealed a sinus rhythm of 73-144 beats/min. Frequent bigeminy, trigeminy, couplets, and triplets were noticed, as well as brief episodes of paroxysmal ventricular tachycardia.

On arrival her pulse was irregularly irregular at 85 beats/min with a blood pressure of 110/60 mmHg and a respiratory rate of 19-20 min. The patient's hematocrit and blood chemistry values were as follows: hematocrit 39, chloride 103 meq/l, sodium 139 meq/l, potassium 3.6 meq/l BUN 10 mg/100 ml, and creatinine 1 mg/100 ml. Her arterial blood gases while breathing oxygen (3 liters/min through a nasal canula) revealed the following: pH 7.39, pO<sub>2</sub> 128 mmHg and pCO<sub>2</sub> 33 mmHg. A 12 lead EKG showed the presence of short episodes of ventricular tachycardia with a rate of 140 beats/min. Retrograde ventricular atrial conduction was present. The available sinus beats

had no abnormal findings (fig. 1). After a cardiology consultation, it was decided not to treat her PVT because she was asymptomatic and hemodynamically stable. After adequate hydration, an epidural catheter was inserted *via* the L2-3 interspace and sensory analgesia was achieved to a bilateral T8 level with 0.25% bupivacaine. The patient's pulse, blood pressure, temperature, EKG, pulse percent oxyhemoglobin (SpO<sub>2</sub>), uterine contractions, and fetal heart rate were monitored during labor. With each uterine contraction, the patient had runs of PVCs and PVT, which were less frequent but nevertheless present even after satisfactory epidural analgesia was achieved (fig. 2).

A 2290 gm male child was delivered vaginally with Apgar scores of 8 and 9 at 1 and 5 min, respectively. In the post delivery period, the patient continued to have runs of PVT and PVCs but were less frequent than those observed during active labor. The patient's 2-D echocardiogram was normal with her left ventricular wall motion and ejection fraction within normal limits. Cardiac chamber dimensions as measured by M mode echocardiogram, were normal. Systolic motion of the interventricular septum and left ventricular posterior wall were also normal. Aortic and mitral valve motion were furthermore noted to be within normal limits. A 24-h Holter ambulatory EKG revealed a sinus rhythm with a rate varying from 46 to 129 beats/min. There were 179 unifocal PVCs, most occurring in a bigeminy pattern. One week postpartum, the EKG, echocardiogram, and Holter ambulatory EKG were within normal limits with no PVCs or PVT.

Nine weeks following her first delivery, she was readmitted for severe nausea and vomiting. Her pregnancy test was positive and she was treated with conservative medical management. She was followed regularly, and during her prenatal visits, she had expressed no cardiac symptoms. Her EKG and cardiac exam were consistently within normal limits.

At 40 weeks gestation, she was admitted to labor and delivery with the spontaneous onset of labor and a history of frequent palpitations. Her EKG showed frequent runs of PVT (fig. 3), which was more pronounced during her uterine contractions. The fetal heart rate revealed a rate of 120-130 beats/min with good variability.

The EKG was continuously monitored and she received 800 ml of lactated Ringer's solution prior to the insertion of an epidural catheter. Following insertion of the lumbar epidural catheter, bilateral T9 dermatome analgesia to pinprick was achieved with 0.25% bupivacaine. She had complete pain relief, but paroxysms of PVT persisted. Eighty minutes later, she was given 4 ml of 1.5% lidocaine without epinephrine through her epidural catheter, followed by 4 ml and 2 ml. Ten minutes after injection, both the PVT and PVCs became less frequent and, after 20 min, the EKG revealed normal sinus rhythm (fig. 4). Because of her electrocardiographic response to epidural lidocaine, a continuous epidural infusion of 0.375% lidocaine without epinephrine was started. Arterial plasma lidocaine concentrations were measured at 30, 60, 120, and 180 min after initiating the infusion. The plasma lidocaine concentrations were 2, 2, 3, and 1.2 µg/ml, respectively.

Normal sinus rhythm continued during the continuous epidural lidocaine infusion. Subsequently, the fetal heart rate pattern began to reveal late decelerations. Because labor was not progressing and the cervical dilatation was 4-5 cm an intravenous oxytocin infusion was

---

Received from the Department of Anesthesia, University of Cincinnati College of Medicine, Cincinnati, Ohio 45267-0531. Accepted for publication March 20, 1989.

Address reprint requests to Dr. Juneja.

Key words: Anesthesia, obstetric. Anesthetics, local: lidocaine. Anesthetic techniques: epidural. Heart, arrhythmia: ventricular tachycardia.

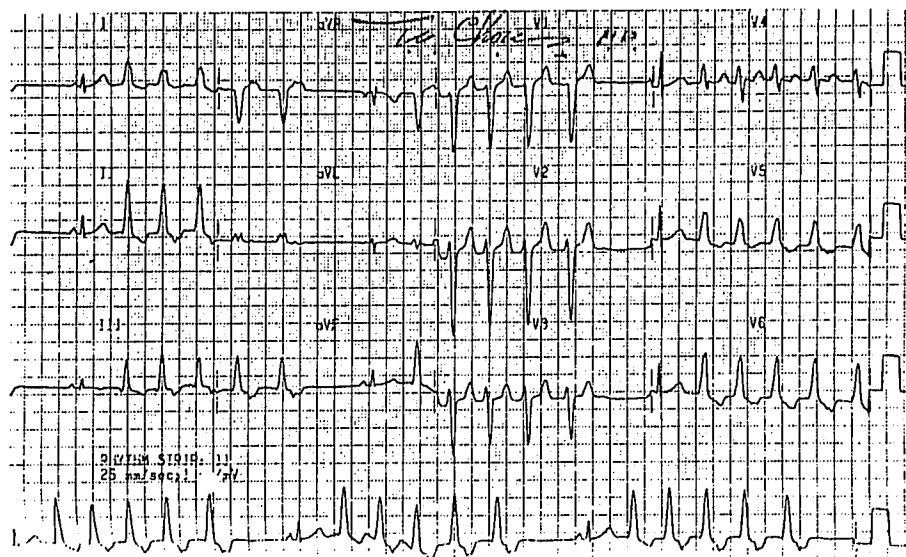


FIG. 1. Twelve lead EKG taken during the first stage of active labor (first pregnancy). There are short episodes of ventricular tachycardia with a rate of 140 beats/min. Retrograde VA conduction is present. The available sinus beats show no abnormal findings.

begun. The scalp blood pH was 7.27; a repeat scalp pH at 30 min was 7.23. The late decelerations persisted and, because labor was not progressing, a decision was made to do a cesarean delivery. Prior to the onset of late decelerations, there were no changes in the fetal heart rate or beat-to-beat variability. A T4 sensory level of anesthesia was achieved with 12 ml of 2% lidocaine administered in 4 ml increments. During exteriorization of the uterus, the patient had 3–4 unifocal PVCs/min. Because the patient was experiencing discomfort, 5 ml of 2% lidocaine were administered, which subsequently eliminated the patient's discomfort as well as her PVCs.

A 3,680 gm male child was delivered with an Apgar score of 8 and 9 at 1 and 5 min, respectively. Postpartum, the patient's cardiac rhythm remained in a normal sinus rhythm.

#### DISCUSSION

Paroxysmal ventricular tachycardia (PVT) is generally considered a manifestation of severe underlying organic heart disease. PVT is an uncommon arrhythmia caused by the generation of rapid ectopic impulses in the ven-

tricles. The rhythm is usually regular. Patients may be asymptomatic or may report symptoms of syncope or angina. On auscultation, the first heart sound can vary in intensity with each beat. PVT can occur with myocardial infarction, cardiomyopathy, or mitral valve prolapse; however, in approximately 10–12% of patients with this arrhythmia, no underlying organic heart disease can be found.<sup>8</sup> The PVT reported previously in pregnant patients further documented no underlying cardiac pathology.<sup>6,7</sup>

Froment *et al.*<sup>9</sup> have described a classification of two types of paroxysmal ventricular tachycardia that occur with no underlying organic heart disease. Type I is clinically marked by: 1) the presence of unifocal premature ventricular contractions in the resting electrocardiogram, 2) runs of bigeminy with the ectopic beat having the same configuration as the unifocal premature ventricular contraction, 3) runs of PVT that would start with an ectopic

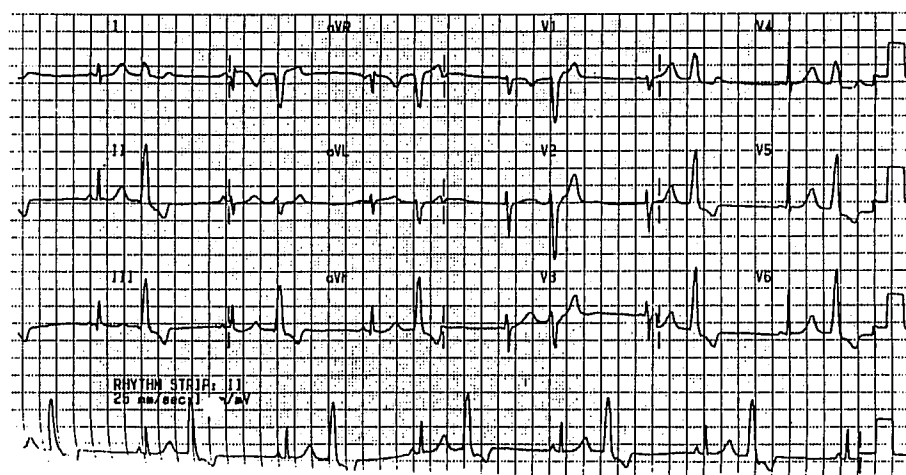
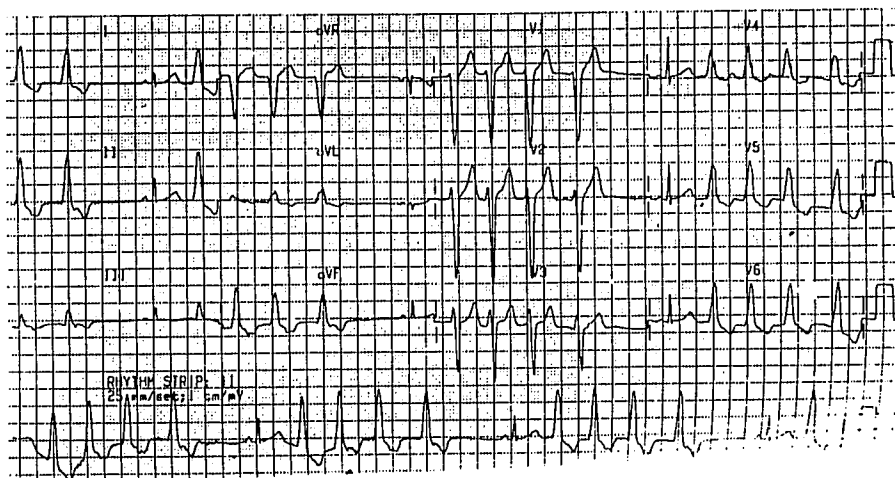


FIG. 2. EKG tracing taken during first stage of active labor (first pregnancy) after establishing epidural block with bupivacaine. EKG shows premature ventricular contraction with bigeminy. The sinus beats show borderline accelerated AV conduction. PVT is not present.

FIG. 3. EKG tracing taken during first stage of active labor (second pregnancy). It shows recurrent short episodes of ventricular tachycardia with rate of 120 beats/min. The sinus beats show no abnormality.



beat and maintain the same configuration as the ectopic beat, and 4) runs of PVT that were short-lived and would usually end spontaneously. Type II is marked by: 1) the absence of premature ventricular contractions and bigeminy in the resting electrocardiogram, 2) sustained runs of PVT lasting on the order of days, and 3) paroxysms of PVT that usually did not revert spontaneously to normal sinus rhythm.

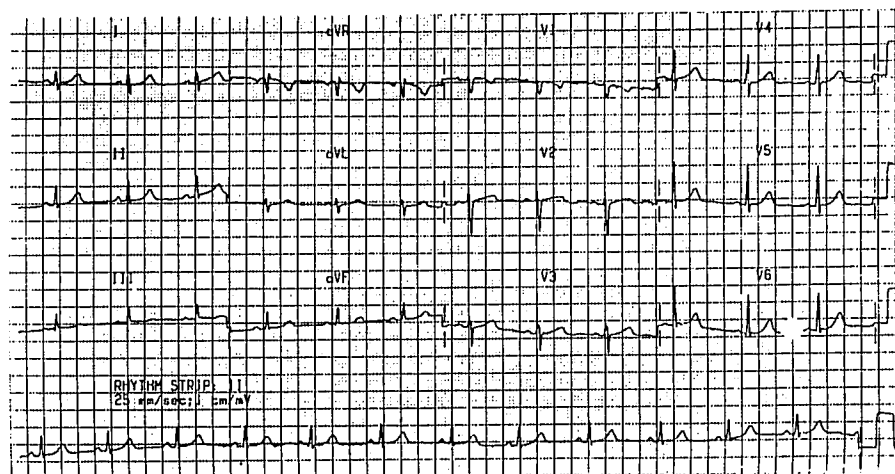
As previously mentioned, there have also been several reports in the literature of pregnant patients with PVT with normal cardiovascular evaluations.<sup>6,7</sup> The first case of PVT with pregnancy was described by McMillan and Bellet.<sup>6</sup> A 16-yr-old woman in her seventh month of gestation presented with PVT. The arrhythmia was precipitated by exercise or emotional upset. Quinidine controlled the arrhythmia but was discontinued because of concern about the effect of this drug on fetal development.

Adams<sup>7</sup> described three patients who had PVT during pregnancy who were successfully treated by quinidine without adverse effects.

Rally and Walters<sup>8</sup> reported a 19-yr-old woman at 24 weeks gestation with PVT induced by exercise during pregnancy which responded to procainamide. Three weeks later, however, she died from sudden cardiac arrest. A post mortem examination revealed a normal cardiac structure. This report demonstrated that the usually benign nature of this arrhythmia might be associated with a fatal outcome. Fortunately, death associated with PVT is rare. Reed *et al.*<sup>10</sup> reported that propranolol was effective therapy for PVT in a 32-yr-old pregnant female in which the dysrhythmia was previously resistant to lidocaine, procainamide, and phenytoin, while Menon *et al.* reported that intravenous lidocaine was effective in treating a 15-yr-old pregnant patient with PVT.<sup>11</sup>

The case that we reported is in the Type I category because of the patient's rhythm characteristics. She was not treated with intravenous lidocaine. As the frequency of PVT increased with each uterine contraction, the arrhythmias might have been caused by catecholamine release induced by physical stress and pain. Once epidural

FIG. 4. Twelve lead EKG taken 1 h after starting continuous epidural infusion of lidocaine. No PVCs or PVTs are present. The EKG is within normal limits.



analgesia was established, however, the PVT continued, suggesting another etiology in this patient. Emotional stress may also cause PVT, which may have been the reason PVT continued in this patient.<sup>7</sup> The arrhythmias that occurred during her first labor were considerably reduced after adequate epidural analgesia was established with 0.25% bupivacaine, but the arrhythmias were never completely abolished. During her second pregnancy, her arrhythmias were completely abolished with the continuous epidural lidocaine infusion.

Intravenous lidocaine by bolus and infusion is often the preferred treatment for terminating ventricular arrhythmia of many causes, including digitalis toxicity.<sup>12</sup> For the effective control of PVT, the maternal plasma concentration should be in a therapeutic range, which is 2–4 µg/ml.<sup>13</sup> The plasma lidocaine concentrations in our patient after the continuous infusion of epidural lidocaine was in the therapeutic range.

Even though lidocaine easily crosses the placenta, a previous study has shown that epidural lidocaine and its metabolites are effectively metabolized by the fetus.<sup>14</sup> At therapeutic blood levels, there is no evidence in experimental animals showing any adverse effects on uterine contractility, the uteroplacental circulation,<sup>15</sup> or on the fetal heart rate.<sup>16</sup>

Thus, we suggest that when a parturient has an arrhythmia of ventricular origin, and if epidural anesthesia is to be administered, lidocaine is the most rational choice as the local anesthetic because, after systemic absorption from the epidural space, it may act as both an antiarrhythmic agent as well as a local anesthetic agent for epidural blockade. Plain solutions of 0.375% lidocaine during continuous epidural infusion do not consistently provide effective analgesia in all patients. In these instances one may wish to supplement with an epidural bolus of 1–1.5% lidocaine. Because of the potential for lidocaine toxicity, if intravenous lidocaine administration is a consideration during epidural lidocaine infusions, we recommend that periodic plasma lidocaine concentrations be measured to avoid the development of toxic levels.

In conclusion, we describe the clinical management of a young parturient with paroxysmal ventricular tachycardia in two successive pregnancies. She had no other evidence of heart disease or systemic illness. Her PVT was not treated because she was asymptomatic and he-

modynamically stable; however, continuous epidural lidocaine infusion, which was started to alleviate the pain of uterine contraction, completely abolished the PVT.

#### REFERENCES

1. Chapman JH, Schrank JP, Crampton RS: Idiopathic ventricular tachycardia: An intracardiac electrical, hemodynamic and angiographic assessment of six patients. *Am J Med* 59:470–480, 1975
2. Wu D, Kou HC, Hung JS: Exercise triggered paroxysmal ventricular tachycardia. A repetitive rhythmic activity possibly related to afterdepolarization. *Ann Intern Med* 95:410–414, 1981
3. Brodsky MA, Satu DA, Oster PD, Schmidt PL, Chesnie BV, Henry WL: Paroxysmal ventricular tachycardia with syncope during pregnancy. *Am J Cardiol* 58:563–564, 1986
4. Chou TC: *Electrocardiography in Clinical Practice*. New York, Grune & Stratton, 1986, p 448–453
5. Stoelting RK, Dierdorf SI, McCammon RL: *Anesthesia and Co-existing Disease*. New York, Churchill Livingstone, 1988, p 96–97
6. McMillan TM, Bellet S: Ventricular paroxysmal tachycardia; Report of case in pregnant girl of sixteen years with an apparently normal heart. *Am Heart J* 7:70–78, 1931
7. Adams CW: Functional paroxysmal ventricular tachycardia. *Am J Cardiol* 9:215–222, 1962
8. Rally CR, Walton MB: Paroxysmal ventricular tachycardia without evident heart disease. *Can Med Assoc J* 86:268–273, 1962
9. Fromenti R, Gallavardin L, Cahen P: Paroxysmal and ventricular tachycardia. A clinical classification. *Br Heart J* 15:172–178, 1953
10. Reed RL, Cheney CB, Fearon RE, Hook R, Hehre FW: Propranolol therapy throughout pregnancy. A case report. *Anesth Analg* 53:214–218, 1974
11. Menon KPS, Mahapatra RK: Paroxysmal ventricular tachycardia associated with Bell's palsy in a teenager at late pregnancy. *Angiology* 35:534–536, 1984
12. Anderson JL, Harrison DL, Meffin DJ, Winker RA: Antiarrhythmic drugs: Clinical pharmacology and therapeutic uses. *Drugs* 15:271–309, 1978
13. Kotmensch HH, Elkayam U, Frishman W: Antiarrhythmic drug therapy during pregnancy. *Ann Int Med* 98:487–497, 1983
14. Kunert BR, Knapp DR, Kuhnert PM, Drochuska AL: Maternal fetal and neonatal metabolism of lidocaine. *Clin Pharmacol Ther* 26:213–220, 1979
15. Biehl D, Shnider SM, Levinson G, Callender K: The direct effects of circulatory lidocaine on uterine blood flow and fetal well being in the pregnant ewe. *Can Anaesth Soc J* 24:445–451, 1977
16. Teramo K, Benowitz NL, Heymann NA, Kahanpaa K, Siemes A, Rudolph AM: Effect of lidocaine on heart rate, blood pressure and electrocardiogram in fetal sheep. *Am J Obstet Gynecol* 118: 935–949, 1974