

Anesthesiology
71:312-315, 1989

Repair of Coarctation of the Aorta in a Child after a Modified Fontan's Operation: Anesthetic Implications and Management

MICHAEL P. HOSKING, M.D.,* FROUKJE BEYNEN, M.D.†

Since the initial report of a right ventricular exclusion procedure for tricuspid atresia by Fontan and Baudet,¹ modifications of this procedure have been applied successfully to an increasingly complex spectrum of congenital heart defects.²⁻⁹ The modified Fontan operation has gained wide acceptance as a functional corrective procedure for tricuspid atresia and single ventricle because of excellent long-term survival and palliation of symptoms.¹⁰ Anastomosis of the right atrium to the pulmonary artery with closure of atrial septal defect, patch closure of the right atrioventricular valve, and discontinuation of the ventriculo-pulmonary artery connection effectively separates the systemic and pulmonary circulations. The ventricle is taken out of the systemic venous-pulmonary circulation, which changes the active propulsion of systemic venous blood through the pulmonary vessel bed to a passive flow-dependent circuit regulated by the difference between right and left atrial pressures. There has been a single report of the anesthetic management for these types of procedures.¹¹ There have been no reports of the anesthetic management of patients after a modified Fontan's repair undergoing other surgical procedures. We report the anesthetic management of coarctation of the aorta repair in a child with univentricular heart that had previously undergone Fontan's procedure.

REPORT OF A CASE

At birth, the patient was a 3,200 g, full-term male. At 3 months of age, the patient presented with pneumonia and a cardiac murmur. Cardiac catheterization at that time revealed situs solitus of atria and viscera, double inlet left ventricle with a hypoplastic subaortic ventricle and the aorta anterior and to the left (type A-III single ventricle). The presence of a mild (12 mmHg) juxta-ductal coarctation of the aorta immediately distal to the left subclavian artery was documented. A large patent ductus arteriosus and patent foramen ovale were present. Pulmonary artery banding and ligation of the patent ductus arteriosus were carried out at 6 months of age. The patient did well until age 10

yr when increasing cyanosis and dyspnea were noted. Cardiac catheterization at that time revealed severe dynamic muscular subaortic obstruction and stenosis of the outlet foramen with a gradient of 69 mmHg, severe stenosis at the pulmonary artery band site with a gradient of 135 mmHg, a large pulmonary blood flow with a pulmonary vascular resistance of 0.7 U m^2 , normal size and distribution of the pulmonary arteries, and a ventricular ejection fraction of 54%. The resting maximal instantaneous gradient of the coarctation was 20 mmHg. Resection of the outlet chamber obstruction with outlet foramen enlargement and widening by patch angioplasty of the severely stenosed main pulmonary artery was then performed. At age 11 yr, a modified Fontan procedure with suture closure of the main pulmonary artery at the level of the previous banding, anastomosis of the right atrial appendage to right pulmonary artery, closure of atrial septal defect, and patch exclusion of the right atrioventricular valve from caval return was performed for a functional corrective procedure. After successful completion of the modified Fontan procedure, repair of the coarctation (34 mmHg gradient) was scheduled. There was virtually no collateral circulation.

On admission, the child was 12 yr old and weighed 29.0 kg. Arterial blood pressure was in the right arm: 120/64; left arm: 124/62; and in the right and left leg: 92/66 and 90/68, respectively. A normal S_1 and a single S_2 were present with a grade 2/6 short systolic murmur present over the left sternal border. The lungs were clear to auscultation. No peripheral edema was noted, and pulses were palpable in both lower extremities. Chest roentgenogram revealed a cardiothoracic ratio of 0.57. An electrocardiogram demonstrated normal sinus rhythm, rate of 88 with a right ventricular conduction delay. Preoperative laboratory values were normal with a hemoglobin of $13.7 \text{ g} \cdot \text{dl}^{-1}$. The exercise test was characterized by a reduced exercise tolerance (62% of predicted for patient age and size) and a cardiac output which was below the lower limit of normal at rest ($2.9 \text{ l} \cdot \text{min}^{-1}$) and at all levels of exercise. Medications include digoxin 0.07 mg twice daily and captopril 25 mg three times daily.

Upon arrival in the operating room, a blood pressure cuff, ECG leads, precordial stethoscope, and pulse oximeter sensor were placed. A 14-G intravenous cannula was inserted in the right hand. Anesthesia was induced with thiopental 150 mg and fentanyl $20 \mu\text{g} \cdot \text{kg}^{-1}$. After adequate muscle relaxation was obtained with pancuronium 5.0 mg, the trachea was intubated with a 6-mm cuffed endotracheal tube. A 4-inch, 20-G right femoral arterial catheter and a 2-inch, 20-G right radial arterial catheter were inserted. An additional 14-G intravenous cannula was inserted in the right arm. A 5-French introducer was inserted in the right internal jugular vein and a 4-French Oximetrix \ddagger catheter was inserted through the introducer, its tip located in the distal superior vena cava. The introducer tubing was primed with dopamine. Initial central venous pressure was 11 mmHg and distal superior vena cava saturation was 81%. Arterial blood gas analysis revealed PaO_2 443 mmHg, Pco_2 34 mmHg, and pH 7.42. Anesthesia was maintained with an additional $10 \mu\text{g}/\text{kg}$ fentanyl and isoflurane 0.5-1.25% in oxygen. The patient's core temperature was decreased by control of ambient air temperature to 34°C .

* Fellow in Cardiovascular Anesthesiology, Mayo Graduate School of Medicine.

† Assistant Professor of Anesthesiology, Mayo Medical School.

Received from the Department of Anesthesiology, Mayo Clinic, Rochester, Minnesota. Accepted for publication March 29, 1989.

Address reprint requests to Dr. Beynen: Department of Anesthesiology, Mayo Clinic, 200 First Street SW, Rochester, Minnesota 55905.

Key words: Anesthesia; pediatric. Monitoring: central venous pressure; mixed venous oxygen saturation. Surgery, cardiac: coarctation; modified fontan.

\ddagger Model No. U425C, Oximetrix Inc., Mountain View, California 94043.

The patient was placed in the right lateral decubitus position and appropriate padding was applied. Methylprednisolone $30 \text{ mg} \cdot \text{kg}^{-1}$ and mannitol $.25 \text{ g} \cdot \text{kg}^{-1}$ were administered at the time of incision. The aorta was approached from a left thoracotomy incision through the third intercostal space. A hypoplastic 1-cm segment of the aorta was present immediately distal to the left subclavian artery with marked poststenotic dilatation. Arterial pressure was 110/51 mmHg in the proximal aorta and 73/55 mmHg in the distal aorta. Mannitol 0.5 g/kg was administered prior to aortic occlusion. With the coarctation clamped, mean femoral arterial pressure fell to 33 mmHg with a radial artery pressure of 160/65 mmHg. With both the distal aorta and left subclavian artery clamped, mean femoral arterial pressure was also 33 mmHg. Clamping of the aorta resulted in a precipitous decline in the superior vena cava saturation to 44% (fig. 1) and an elevation of central venous pressure to 20 mmHg. Dopamine $6 \mu\text{g} \cdot \text{kg}^{-1} \cdot \text{h}^{-1}$ was initiated, superior vena cava saturation stabilized at 44%, while the right radial arterial pressure remained 160/65 mmHg. The saturation measured by pulse oximetry remained unchanged at 97–100%. On application of the crossclamp, severe (4–5 mm) ST segment changes developed, which gradually decreased to 1 mm over approximately 3 min and returned to baseline with release of the aortic clamp.

Dense adhesions and limited exposure prevented placement of a bypass shunt. As a result, resection of the coarctation diaphragm and angioplasty using a Goretex patch was performed. Aortic crossclamp time was 16 min. With release of the crossclamp, superior vena cava saturation improved dramatically, accompanied by a decline in central venous pressure from 20 to 15 mmHg. A gradient of 4 mmHg was present across the coarctation repair after release of the crossclamp. Arterial blood gas analysis revealed PaO_2 320 mmHg, Pco_2 37 mmHg, and pH 7.35. Intercostal nerve blocks with bupivacaine 0.5% with epinephrine 1/200,000 were placed by the surgeon under direct vision. After adequate hemostasis was achieved (estimated blood loss for the whole procedure was approximately 100 ml), the chest was closed. Isoflurane was discontinued and neuromuscular blockade reversed with neostigmine $0.05 \text{ mg} \cdot \text{kg}^{-1}$ and glycopyrrolate $0.01 \text{ mg} \cdot \text{kg}^{-1}$. The patient was able to move both lower extremities on command. Fentanyl $20 \mu\text{g/kg}$ was then administered and the patient transferred to the intensive care unit. As is our routine after a Fontan procedure, the trachea was extubated the next morning. The patient was discharged on postoperative day 6. Blood pressures in the right and left arm and left leg were 124/68, 120/70, and 114/74, respectively.

DISCUSSION

The concept of bypassing the right ventricle was first proposed in 1949.¹² In 1958, Glenn reported the first clinical application of this principle when he successfully performed an anastomosis between the superior vena cava and the right pulmonary artery in a patient with tricuspid atresia.¹³ Fontan advanced this concept by performing a direct anastomosis of the right atrium to the pulmonary artery, confirming the ability to perfuse the pulmonary circulation by right atrial pressure.¹ This offered a physiologic correction for tricuspid atresia or single ventricle by separating the systemic and pulmonary circulations. The modified Fontan operation results in improved arterial oxygenation by effectively preventing mixing of systemic and pulmonary venous return.^{4–6} Elimination of intracardiac shunting reduces the possibility of paradoxical embolization and the consequent neurologic sequelae. In addition, the modified Fontan operation decreases the

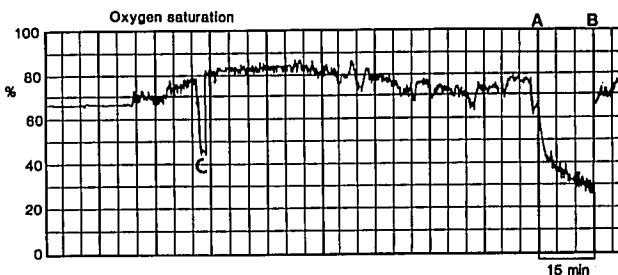


FIG. 1. Intraoperative record of superior vena cava oxygen saturation. A. Placement of aortic clamp. B. Release of aortic clamp. C. Sampling artifact for calibration of mixed venous oxygen saturation.

volume load imposed on the single ventricle and results in preservation of myocardial function.¹⁰ Because of these potential benefits, the modified Fontan procedure has gained wide acceptance as a functional corrective procedure for tricuspid atresia and univentricular heart. Over 500 such operations have been performed at the Mayo Clinic. The increasing application of right ventricular bypass dictates that some of these patients will undergo surgical procedures after Fontan's operation.

After elimination of the contractile pulmonary ventricle, the pulmonary perfusion depends mainly on a pressure-flow relationship and as such requires elevated right atrial pressure. Pulmonary arterial flow is biphasic; the first phase occurring with atrial systole and the second phase during ventricular systole as the left atrium relaxes and blood flows from the central pulmonary artery into the emptying pulmonary venous capacitance bed.¹⁴ In the immediate postoperative period, right atrial pressure of 14–20 mmHg is generally required to maintain adequate pulmonary flow.^{10,11,15} A gradient of approximately 7 mmHg (which is needed to overcome the resistance presented by the pulmonary vascular bed) normally exists between the right and left atrium after the modified Fontan procedure, and it is this pressure gradient that maintains pulmonary flow.¹⁵

Monitoring of the central venous pressure is extremely useful in these patients, not only for assessment of volume status, but also for detection of sudden impairment of left ventricular function, as well as increases in pulmonary vascular resistance. In a four-chamber heart, the right ventricle is able to compensate for a sudden increase in pulmonary vascular resistance or decrease in left ventricular function such that little or no change is detected in the central venous pressure. However, the right ventricle is eliminated from the pulmonary circulation in the patient with a modified Fontan repair. As FI_{O_2} , ventilation, and fluid management remained unchanged, the increase in central venous pressure, as recorded during aortic cross-clamping, most likely reflected the elevated ventricular end diastolic pressure of the systemic ventricle unable to maintain its previous stroke volume.

Continuous monitoring of superior vena cava saturations indirectly provides an estimation of cardiac output (assuming arterial saturation, hemoglobin, and oxygen consumption are stable).^{16,17}

Because the anatomy of the right atrium-right ventricle-pulmonary artery pathway is considerably changed by the modified Fontan operation, measuring oxygen saturation by the "mixed venous" catheter in the right atrium or even in the pulmonary artery may not represent properly mixed venous blood (in the normal heart proper mixing occurs in the right ventricle, which is missing in the patient with a modified Fontan repair).¹⁸ Oxygen saturation of superior vena cava blood bears a constant relationship to that of mixed venous blood,¹⁹ and therefore changes in mixed venous oxygen saturation can be detected by monitoring the oxygen saturation in the superior vena cava. Changes in cardiac output are reflected by changes in mixed venous saturation,^{16,17} and continuous monitoring of the oxygen saturation in the superior vena cava should instantaneously reflect sudden changes in cardiac output. Distal superior vena cava saturation dropped precipitously with clamping of the aorta and almost certainly reflected a large decrease in cardiac output of the single ventricle caused by a large increase in impedance to ejection, as hemoglobin, arterial saturation, and oxygen consumption were unchanged.¹⁷

Insertion of a thermodilution pulmonary artery catheter in patients after a modified Fontan repair may be technically difficult secondary to the unusual anatomical arrangement. Furthermore, no information is available about the accuracy of thermodilution cardiac output measurements in these patients.

Right atrial pressure (which is equal to pulmonary artery pressure) remains elevated on long-term followup after Fontan's operation. Laks *et al.*³ reported a mean right atrial pressure of 15 ± 1 mmHg (mean \pm SEM) in 16 patients catheterized from 1 to 42 months post-Fontan procedure. A difference of 4 or 5 mmHg in right atrial pressure has significant implications for long-term survival.¹⁵ These results indicate that although absence of a contractile pulmonary ventricle is compatible with long-term survival, the adaptability of the circulatory system is restricted. This reduced capacity of the single ventricle to respond to an increased workload may have significant impact on the anesthetic management of patients after Fontan's repair. Clamping of the aorta resulted in severe ST segment changes on the ECG, probably indicative of ventricular strain caused by the sudden increase in afterload. The increased right atrial pressure and the decrease in central venous oxygen saturation represent an increase in left ventricular end diastolic pressure and a decrease in cardiac output. Administration of an inotropic agent was therefore initiated because a univentricular heart after a modified Fontan repair may have a suboptimal response

to stress.⁴ The single ventricle must supply the cardiac output for both the systemic and pulmonary circulations and support with inotropic agents should be readily available, particularly if sudden changes in impedance to ejection are anticipated as in this case. Hyperventilation, a high inspired FI_{O_2} , alkalosis, and maintenance of low mean airway pressures, all reduce pulmonary vascular resistance and improve cardiac output. The use of a vasodilator in this patient with a cardiac index of $2.5 \text{ l} \cdot \text{min}^{-1} \cdot \text{m}^2^{-1}$ and reduced exercise tolerance was considered. However, further reductions of the perfusion pressure distal to the aortic crossclamp might have increased the risk of spinal cord ischemia. Arterial pressure proximal to the aortic crossclamp never exceeded 160/65 mmHg and vasodilators were not used.

The incidence of paraplegia after coarctation repair in 12,532 cases was 0.41%.²⁰ Blood flow to the anterior spinal artery is augmented by radicular branches of the intercostal arteries and may be compromised during crossclamping of the aorta. Hyperthermia may potentiate the effects of ischemia on the spinal cord, and conversely, a reduction of core temperature by only 3° C doubles the duration of reversible ischemia in an animal model.²¹ Somatosensory evoked potentials may be used to monitor spinal cord function during surgery on the descending thoracic aorta. However, case reports of paraplegia with normal somatosensory evoked potentials^{22,23} indicate that monitoring of posterior cord function does not insure adequacy of blood flow to the anterior portion of the spinal cord.

The risk of spinal cord damage in a patient with a modified Fontan repair compared to the risk in a patient with a normal heart undergoing coarctation repair may be increased as the right atrial pressure, and thus the CSF pressure, are elevated. In an unknown percentage of the population, the anterior spinal artery is not continuous from its upper to its lower regions or the artery shows significant narrowing in the middorsal area such that perfusion of the distal spinal cord is dependent on the distal radicular arteries. If this anatomical variation is present in a patient with a modified Fontan repair, the same decrease (after crossclamping of the aorta) in distal mean arterial pressure results in a greater decrease in perfusion pressure (mean arterial pressure—CSF pressure) of the distal spinal cord in the Fontan patient than in a patient with a normal heart.

In conclusion, the anesthetic management of coarctation repair in a patient after Fontan's operation is reported. Absence of a contractile pulmonary ventricle makes monitoring of superior vena cava pressure and saturation extremely valuable in these patients. Elevated right atrial pressure and impaired ability of a single ventricle to adapt to acute increases in afterload may require prompt administration of inotropic agents. Increasing ap-

plication of Fontan's operation for complex congenital surgical repairs will result in more of these patients presenting for other surgical procedures. An understanding of the unusual physiology and anesthetic implications will assist in the safe management of these patients.

REFERENCES

1. Fontan F, Baudet E: Surgical repair of tricuspid atresia. *Thorax* 26:240-248, 1971
2. Marcelletti C, Mazzera E, Olthof H, Sebel PS, Duren Dr, Losekoot TG, Becker AE: Fontan's operation: An expanded horizon. *J Thorac Cardiovasc Surg* 80:764-769, 1980
3. Kawashina Y, Kitamura S, Matsuda H, Shimazaki Y, Nakano S, Hirose H: Total cavopulmonary shunt operation in complex cardiac anomalies: A new operation. *J Thorac Cardiovasc Surg* 87:74-81, 1984
4. Laks H, Milliken JC, Perloff JK, Hellenbrand LOE, George BL, Chin A, DiSessa TG, Williams RG: Experience with the Fontan procedure. *J Thorac Cardiovasc Surg* 88:934-951, 1984
5. DeLeon SY, Ilbawi MN, Idriss FS, Muster AJ, Gidding SS, Berry TE, Paul MH: Fontan type operation for complex lesions: Surgical considerations to improve survival. *J Thorac Cardiovasc Surg* 92:1029-1037, 1986
6. Mayer JE, Helgason H, Jonas RA, Lang P, Vorgas FJ, Cook N, Castaneda AR: Extending the limits for modified Fontan procedures. *J Thorac Cardiovasc Surg* 92:1021-1028, 1986
7. Matsuda H, Kawashima Y, Kishimoto H, Hirose H, Nakano S, Kato H, Taniguchi K, Sano T, Ogawa M: Problems in the modified Fontan operation for univentricular heart of the right ventricular type. *Circulation* 76(SIII):45-52, 1987
8. Coles JG, Kielmanowicz S, Freedom RM, Benson LN, Moes F, Olley PM, Rabinovitch M, Rosenberg H, Sherret H, Rowe RD, McLaughlin PR, Trusler GA, Williams WG: Surgical experience with the modified Fontan procedure. *Circulation* 76(SIII):61-66, 1987
9. Puga FJ, Chiavarelli M, Hagler DJ: Modifications of the Fontan operation applicable to patients with left atrioventricular valve atresia or single atrioventricular valve. *Circulation* 76(SIII):53-60, 1987
10. Humes RA, Porter CJ, Mair DM, Rice MJ, Offord KP, Puga FJ, Schaff HV, Danielson GK: Intermediate follow-up and predicted survival after the modified Fontan procedure for tricuspid atresia and double-inlet ventricle. *Circulation* 76(SIII):67-71, 1987
11. Fryman PN, Goodman K, Casthley PA, Griep RB, Ergin A, Smith P: Anesthetic management of patients undergoing Fontan procedure. *Anesth Analg* 65:516-519, 1986
12. Rodbard S, Wagner D: Bypassing the right ventricle. *Proc Soc Exp Biol Med* 71:69-70, 1949
13. Glenn WWL: Circulatory bypass of the right side of the heart. IV. Shunt between superior vena cava and distal pulmonary artery. Report of clinical application. *N Engl J Med* 259:117-124, 1958
14. DiSessa TG, Child JS, Perloff JK, Wu L, Williams RG, Laks H, Friedman WF: Systemic venous and pulmonary arterial flow patterns after Fontan's procedure for tricuspid atresia or single ventricle. *Circulation* 70:898-902, 1984
15. Kirklin JK, Blackstone EH, Kirklin JW, Pacifico AD, Borgeron LM: The Fontan operation: Ventricular hypertrophy, age, and date of operation as risk factors. *J Thorac Cardiovasc Surg* 92:1049-1064, 1986
16. Waller JL, Kaplan JA, Bauman DI, Craver JM: Clinical evaluation of a new fiberoptic catheter oximeter during cardiac surgery. *Anesth Analg* 61:676-679, 1982
17. Divertie MB, McMichan JC: Continuous monitoring of mixed venous oxygen saturation. *Chest* 85:423-428, 1984
18. Dongre SS, McAslan TC, Shin B: Selection of the source of mixed venous blood samples in severely traumatized patients. *Anesth Analg* 56:527, 1977
19. Miller HC, Brown DJ, Miller GAH: Comparison of formulae used to estimate oxygen saturation of mixed venous blood from caval samples. *Br Heart J* 36:446-451, 1974
20. Brewer LA, Fosburg RG, Mulder GA, Berska JJ: Spinal cord complication following surgery for coarctation of the aorta: A study of 66 cases. *J Thorac Cardiovasc Surg* 64:368-378, 1972
21. Vacanti FX, Ames A III: Mild hypothermia and Mg⁺⁺ protect against reversible damage during CNS ischemia. *Stroke* 15:695-698, 1984
22. Takaki O, Okumura F: Application and limitation of somatosensory evoked potential monitoring during thoracic aortic aneurysm surgery: A case report. *ANESTHESIOLOGY* 63:700-703, 1985
23. Ginsburg HH, Shelter AG, Raudzens PA: Postoperative paraplegia with preserved intraoperative somatosensory evoked potentials. *J Neurosurg* 63:296-300, 1985