

# *Transdermal Scopolamine Decreases Nausea and Vomiting following Cesarean Section in Patients Receiving Epidural Morphine*

Dennis M. Kotelko, M.D. F.R.C.P.(C.), \* Richard L. Rottman, M.D., \* William C. Wright, M.D., \* Joseph J. Stone, M.D., \* Alan Y. Yamashiro, M.D., † Richard M. Rosenblatt, M.D. \*

The authors evaluated the antiemetic properties of transdermal scopolamine (TDS) in healthy patients undergoing elective cesarean section and receiving epidural morphine for postoperative analgesia. Prior to administration of anesthesia, 203 patients had either TDS or a placebo study patch applied behind one ear. All patients were hydrated with lactated Ringer's solution iv and given 2.0% lidocaine with 1:200,000 epinephrine epidurally for surgical anesthesia. Following delivery of the infant, 4 mg of morphine sulphate was injected through the epidural catheter. After the operation patients were evaluated by "blinded" observers at 2, 4, 6, 8, 10, 24, and 48 h for nausea, vomiting, retching, pain relief, itching, and adverse effects. In addition, medications received were noted. No differences were found between the groups in terms of severity or incidence of pain, or requests for analgesic or antipruritic medication. Although there was no difference between the groups in the first 2 h, patients with TDS had significantly less nausea, vomiting, and retching than patients in the placebo group in each time interval between 2 and 10 h. Additionally, the TDS group required less antiemetic medication. There was no difference in the frequency of retching or vomiting between groups. Side effects were minimal and equal in both groups. The authors conclude that TDS results in a decreased incidence of nausea and vomiting in patients who have delivered by cesarean section and received epidural morphine. TDS appears safe for continuous antiemetic administration. (Key words: Analgesics, epidural; morphine. Anesthesia: cesarean section; obstetric. Anesthetic technique: epidural. Parasympathetic nervous system: scopolamine. Vomiting, nausea: postoperative.)

EPIDURAL MORPHINE for postcesarean section analgesia is widely used.<sup>1-3</sup> Despite excellent pain relief, the side effect of postoperative nausea and vomiting following epidural morphine is often distressing. The reported incidence of postoperative nausea and vomiting related to epidural opioids varies from 5% to 56%.<sup>2-5</sup> Transdermal scopolamine (TDS) is widely used and is highly effective for controlling motion-induced nausea and vomiting. In a review of controlled studies of patients experiencing motion sickness,<sup>6-8</sup> the therapeutic efficacy and pharmacodynamic properties of TDS were well demonstrated.

\* Attending Anesthesiologist, Department of Anesthesiology, Cedars-Sinai Medical Center, Los Angeles, California.

† Attending Anesthesiologist, Mission Hospital, Mission Viejo, California.

Received from the Department of Anesthesiology, Cedars-Sinai Medical Center, Los Angeles, California. Accepted for publication June 27, 1989. Supported by Ciba Consumer Pharmaceuticals (Grant No. 84-010-01). Presented in part at the Annual Meeting of the American Society of Anesthesiologists, San Francisco, California, 1988.

Address reprint requests to Dr. Kotelko: Department of Anesthesiology, Cedars-Sinai Medical Center, 8700 Beverly Boulevard, Los Angeles, California 90048-1869.

Based on these reports, this study was designed to assess the effectiveness of TDS in preventing nausea and vomiting associated with epidural morphine analgesia in patients undergoing elective cesarean delivery.

## Materials and Methods

After institutional approval by the Human Subjects Committee and informed consent, 203 ASA physical status 1 or 2 patients, 18-38 yr of age and scheduled for elective cesarean section, agreed to participate in this randomized, double-blinded, placebo-controlled study. These nonmedicated patients had an iv catheter inserted, and 30 ml of sodium citrate po given in the preoperative area. An attending anesthesiologist applied the study patch behind one ear after wiping the skin clean with an alcohol swab. Patches were identical in appearance and size.

In the operating room patients were monitored with ECG, automatic blood pressure cuff (Omega I™) at 1-min intervals, for 10 min, then every 5 min until completion of surgery, and continuous pulse oximetry (Nellcor™). After they received 1,500-2,000 ml of lactated Ringer's solution iv, 2.0% lidocaine with 1:200,000 epinephrine was administered into the epidural space through a catheter inserted via L2-3 or L3-4 interspace. Patients were tilted to the left to displace the uterus, and surgical anesthesia to a dermatome level of T2-4 was documented. Systolic blood pressure was maintained at >100 mmHg by iv fluid administration or by intermittent iv doses of either ephedrine (5 mg) or mephentermine (7.5 mg).

After the neonate was delivered and uterine hemostasis was achieved, 4.0 mg of morphine sulphate in 8 ml (Duramorph®) was injected through the epidural catheter. After the surgery blood loss was estimated and intraoperative nausea and vomiting were recorded. For efficacy evaluation, the point at which the patient arrived in the post-anesthetic recovery room (PAR) was considered time zero. On average, this was 90 min following initial application of the study patch.

Efficacy was assessed at regular intervals after surgery by recording the times and durations of nausea, times and frequency of retching and vomiting, and the times of administration, doses, and routes of supplementary antiemetics. The first efficacy evaluation was made 2 h postoperatively in the PAR.

Subsequent evaluations were made 4, 6, 8, 10, and 24 h after surgery. An additional evaluation was made 24 h

after removal of the patch to document all adverse experiences reported by the patient or recorded in the chart between 24 and 48 h postdelivery. During the final evaluation, the patients were asked if they had a history of motion sickness, nausea during pregnancy, or a tendency to nausea. A hematocrit was measured 24 h following surgery. Newborns were observed and received routine care in the nursery during the first 48 h after delivery.

Prophylactic antiemetics were not used. Supplemental droperidol im was only administered if the patient requested it. Vomiting and/or retching were the primary end point for efficacy analysis. Patients who received antiemetic medication continued to wear their patches for the full 24-h evaluation period. Intravenous administration of naloxone was permitted to control morphine-induced itching. Additional analgesics and other medications were allowed as indicated. The analgesic activity of morphine was monitored by soliciting the patient's assessment of severity of her pain at each time period, using the following rating scale: 0 = no pain, 1 = mild pain, 2 = moderate pain, 3 = severe pain. Severity of itching was also assessed by the patient, using the following rating scale: 0 = none, 1 = mild, localized, 2 = moderate, 3 = severe, generalized.

At each efficacy evaluation period, the patient's chart was reviewed to determine if analgesic, antiemetic or other medications were given. The two groups, TDS and placebo, were compared and analyzed using the Mantel-Hanzel, two-sided *t* tests, two-sided chi-square tests, and two-sided Wilcoxon rank tests. *P* values of 0.05 or less were considered statistically significant.

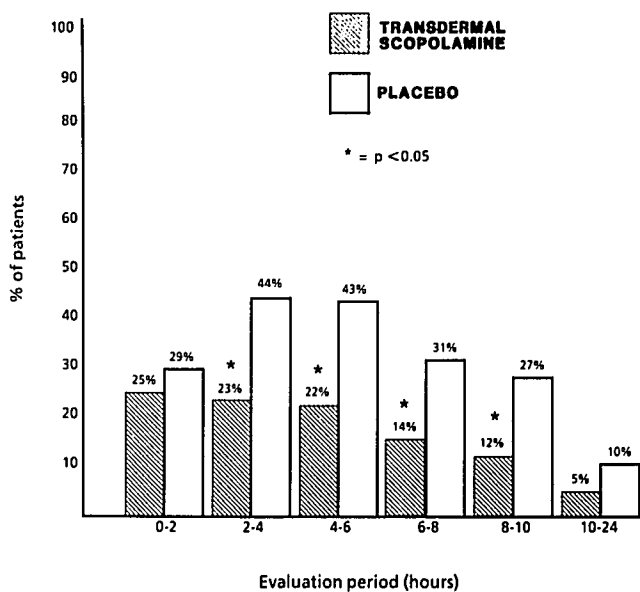


FIG. 1. Percentage of patients experiencing nausea during the observation intervals.

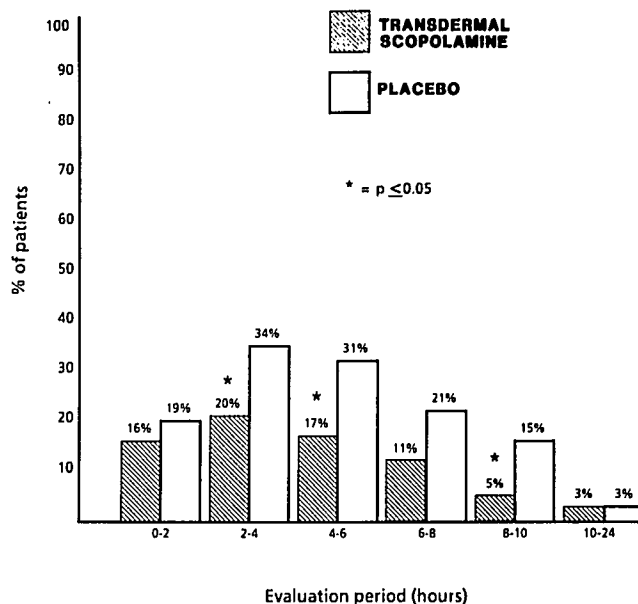


FIG. 2. Percentage of patients experiencing vomiting or retching during the observation intervals.

## Results

Differences between TDS and placebo groups with regard to age, week of gestation, weight, gravidity, neonatal weight, and Apgar scores were not significant. Among the potentially confounding factors for efficacy analysis in this study, the most important were intraoperative administration of additional opioids, postoperative administration of additional opioids, and postoperative administration of naloxone. There was no intergroup imbalance with regard to these variables.

Postoperatively, significantly fewer patients receiving TDS experienced nausea or retching/vomiting compared with those with a placebo patch in the four 2-h observation periods between 2–10 h with the exception of the 6–8 h period (figs. 1 and 2). Overall, during the first 24-h period, significantly fewer patients in the TDS group experienced nausea, vomiting, or retching (fig. 3) or requested additional antiemetic (fig. 4).

Patients in both groups similarly experienced no pain or mild pain postoperatively and requested additional analgesic. Mild to moderate pruritus was experienced by both groups, and requests for naloxone treatment were the same (table 1). Patients in both groups equally reported minor adverse experiences with the test patches (table 2). The occurrence of dry mouth was common, but patients were not specifically requested to indicate its severity. There was no correlation in the presence of nausea or retching/vomiting and intraoperative hypotension; intraoperative nausea or vomiting; surgical blood loss; preoperative and postoperative hematocrits; a history of

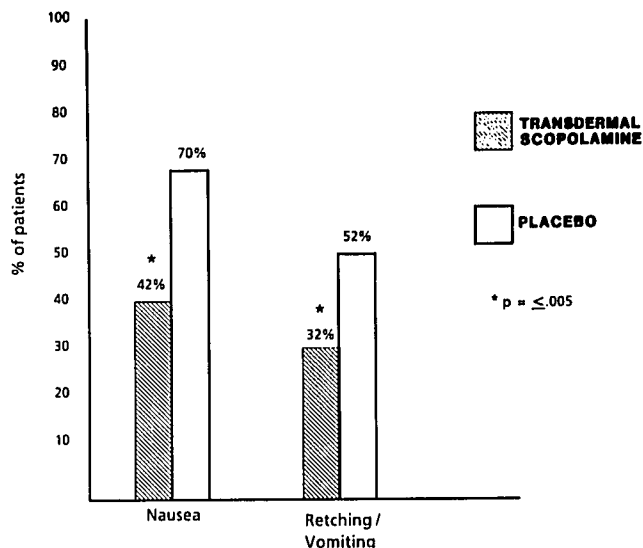


FIG. 3. Overall percentage of patients experiencing nausea and vomiting or retching during the first 24 h postoperatively.

motion sickness; a history of general nausea; or a history of nausea during pregnancy.

### Discussion

In our cumulative clinical experience prior to this study, we observed that women after cesarean delivery often complained of nausea and vertigo interspersed with sporadic vomiting. Despite having either no or mild pain with epidural morphine, it was clear that a more effective antiemetic would allow mothers to spend time comfortably with their newborns. This study reexamines TDS for postoperative nausea and vomiting. Loper *et al.*<sup>9</sup> reported that in patients receiving epidural morphine following major gynecologic surgery, TDS patches significantly reduced the incidence and severity of nausea. The results of other studies have been equivocal.<sup>10</sup> \*†

Most of the patients who experienced nausea and vomiting did so by 10 h postoperatively. Inspection of the rates of symptoms/events (nausea, retching, vomiting, administration of antiemetics) in successive time intervals postoperatively reveals that with the exception of the 0–2-h interval, the differences in incidence rates are in favor of TDS at every postoperative evaluation interval up to 10 h postsurgery. All but one of these differences are statistically significant. We did expect to achieve signifi-

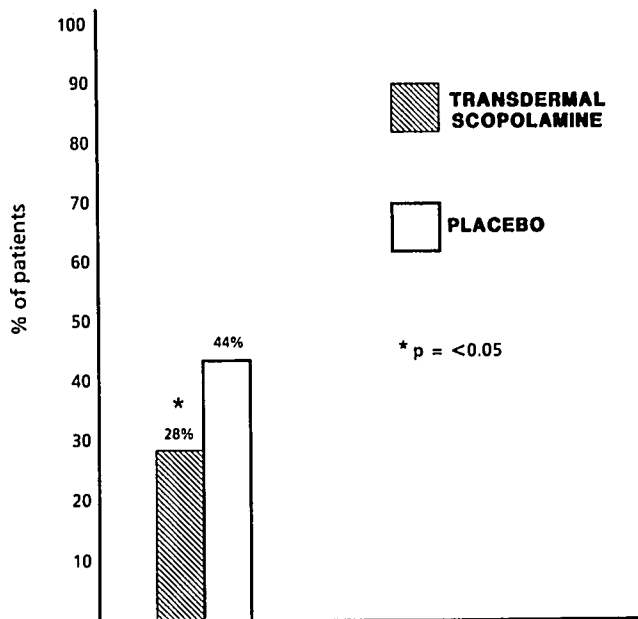


FIG. 4. Overall percentage of patients requesting additional antiemetics during the first 24 h postoperatively.

cance in favor of TDS after the 2-h observation. On average, patches were applied approximately 210 min prior to this evaluation. Generally, it takes 3–4 h to achieve therapeutic blood levels of scopolamine.

Our highest incidence of nausea (44%) and vomiting (34%) was at the 2- to 4-h evaluation period in the placebo group, higher than reported in earlier series.<sup>2,3</sup> Perhaps our incidence was higher because we observed and recorded any symptom episode as an occurrence. In non-obstetric postoperative patients receiving morphine epidurally, the incidence of reported nausea and vomiting is similar to ours. Stenseth *et al.*<sup>4</sup> reported their experience with 1,085 patients who received morphine epidurally for postoperative pain. Their overall incidence of nausea or vomiting was 34% (range 12–56%), had no relationship with morphine dose, and varied with the type of surgery. Interestingly, postoperative nausea or vomiting was more frequent in women than in men (51% vs. 23%;  $P < 0.001$ ). Bromage *et al.*<sup>11</sup> reported that 60% of volunteers expe-

TABLE 1. Percentage of Patients Reporting on Quality of Pain Relief and Incidence and Treatment of Pruritus in the First 24 h

	TDS (n = 102)	Placebo (n = 101)
No pain or mild pain	89	92
Request for analgesics	54	44
Report of pruritus	76	69
Request for naloxone for pruritus	40	43

There were no significant differences.

\* Gibbons PA, Nicholson SC, Betts ER, Rosenberg KR, Jobes DR: Scopolamine does not prevent postoperative emesis after pediatric eye surgery (abstract). ANESTHESIOLOGY 61:A435, 1984

† Tolsdorf W, Baumann S, Heine C, Hettenbach A: Effects and side-effects of transdermal scopolamine in premedication before general anesthesia in elderly patients. Anaesth Intensivther Not Fallmed 21: 301, 1986

TABLE 2. Percentage of Patients Experiencing Adverse Effects While Wearing the Test Patch in the First 24 h

	TDS (n = 102)	Placebo (n = 101)
Dizziness or Light-headedness	8	8
Blurred vision	4	2
Disorientation	1	0

rienced nausea and 50% vomited 4–6 h after administration of 10 mg morphine epidurally.

The TDS patch is 2.5 cm<sup>2</sup> in area and 18 mm in diameter. It contains 1.5 mg of scopolamine and is designed to deliver *in vivo* 0.5 mg of scopolamine over 3 days.<sup>8</sup> An initial priming dose (140 µg) of scopolamine released from the adhesive layer of the system saturates the skin binding sites and rapidly brings the plasma concentration of scopolamine to the required steady state level over 3–4 h. A continuous controlled release of scopolamine (5 µg/h), which flows from the drug reservoir through the rate-controlling membrane, keeps the plasma level constant. The anticholinergic effects of scopolamine may help prevent nausea by inhibiting vestibular input to the CNS and, in turn, the vomiting reflex. In addition, scopolamine may have a direct action on the reticular activating formation of the brain stem.

TDS has been applied for other medical indications that frequently result in severe nausea and vomiting. Results are available from two random blinded studies of TDS for cisplatin-induced emesis in cancer patients. Longo *et al.*<sup>12</sup> reported acceptable side effects but ineffectiveness when used alone. Meyer *et al.*<sup>13</sup> reported that the addition of TDS to a standard antiemetic regimen provides additive benefit in the control of cisplatin-induced emesis.

Common side effects reported when using TDS include dry mouth (67%), drowsiness (18%), and, less frequently, blurred vision. Although not seen in our study patients, a number of rare adverse effects of TDS have been reported. Toxic psychosis<sup>14–16</sup> has been noted, particularly in elderly patients, and limited unilateral cycloplegia<sup>17–20</sup> lasting up to 72 h has been described. One of our patients receiving TDS experienced mild, short-lived disorientation. She required no treatment and had the patch removed. Infants of mothers of both groups showed no adverse effects of the maternally applied transdermal patches.

In conclusion, TDS provides the patient a simple, painless, and continuously administered dose of scopolamine antiemetic. The patch significantly reduced but did not completely eliminate the occurrence of nausea and vomiting or retching. We recommend its use in the postce-

sarean patient and believe that further evaluation is warranted in other postoperative settings.

## References

1. Youngstrom PC, Cowan RI, Sutheimer C, Eastwood DW, Yu JCM: Pain relief and plasma concentrations from epidural and intramuscular morphine in post-cesarean patients. *ANESTHESIOLOGY* 57:404–409, 1982
2. Rosen MA, Hughes SC, Shnider SM, Abboud TK, Norton MD, Dailey PA, Curtis JD: Epidural morphine for the relief of postoperative pain after cesarean delivery. *Anesth Analg* 62:666–672, 1983
3. Kotelko DM, Dailey PA, Shnider SM, Rosen MA, Hughes SC, Brizgys RV: Epidural morphine analgesia after cesarean delivery. *Obstet Gynecol* 63:409–413, 1984
4. Stenseth R, Sellevold O, Breivik H: Epidural morphine for postoperative pain: Experience with 1085 patients. *Acta Anaesthesiol Scand* 29:148–156, 1985
5. Rawal N, Sjöstrand U, Dahlström B: Postoperative pain relief by epidural morphine. *Anesth Analg* 60:726–731, 1981
6. van Marion WF, Bongaerts MCM, Christiaanse JC, Hofkamp HG, van Ouwerkerk W: Influence of transdermal scopolamine on motion sickness during 7 days exposure to heavy seas. *Clin Pharmacol Ther* 38:301–305, 1985
7. Price NM, Schmitt LG, McGuire J, Shaw JE, Trobough G: Transdermal scopolamine in the prevention of motion sickness at sea. *Clin Pharmacol Ther* 29:414–419, 1981
8. Clissold SP, Heel RC: Transdermal hyoscine (scopolamine). A preliminary review of its pharmacodynamic properties and therapeutic efficacy. *Drugs* 29:189–207, 1985
9. Loper KA, Ready LB, Dorman BH: Prophylactic transdermal scopolamine patches reduce nausea in postoperative patients receiving epidural morphine. *Anesth Analg* 68:144–146, 1989
10. Aronson JK, Sear JW: Transdermal hyoscine (scopolamine) and postoperative vomiting. *Anaesthesia* 41:1–3, 1986
11. Bromage PR, Camporesi EM, Durant PAC, Nielsen CH: Non-respiratory side-effects with epidural morphine. *Anesth Analg* 61:490–495, 1982
12. Longo DL, Wesley M, Howser D, Hubbard SM, Anderson T, Young RC: Results of a randomized double-blind crossover trial of scopolamine versus placebo administered by transdermal patch for the control of cisplatin-induced emesis. *Cancer Treat Rep* 66:1975–1976, 1982
13. Meyer BR, O'Mara V, Reidenberg MM: A controlled clinical trial of the addition of transdermal scopolamine to a standard metoclopramide and dexamethasone antiemetic regimen. *J Clin Oncol* 5:1994–1997, 1987
14. MacEwan GW, Remick RA, Noone JA: Psychosis due to transdermally administered scopolamine. *Can Med Assoc J* 133:431–432, 1985
15. Osterholm RK, Camoriano JK: Transdermal scopolamine psychosis (letter). *JAMA* 247:3081, 1982
16. Rodysill KJ, Warren JB: Transdermal scopolamine and toxic psychosis. *Ann Intern Med* 98:561, 1983
17. McCrary JA, Webb NR: Anisocoria from scopolamine patches. *JAMA* 248:353–354, 1982
18. Carlston JA: Unilateral dilated pupil from scopolamine disk (letter). *JAMA* 248:31, 1982
19. Chiamonte JS: Cycloplegia from transdermal scopolamine. *N Engl J Med* 306:174, 1982
20. Rosenberg M: Preoperative anisocoria from a scopolamine patch (letter). *Anesth Analg* 66:693, 1987