

Seizures during Opioid Anesthetic Induction— Are They Opioid-Induced Rigidity?

N. Ty Smith, M.D.,* James L. Benthuisen, M.D.,† Reginald G. Bickford, M.D.,‡ Theodore J. Sanford, M.D.,§
Tom Blasco, M.D.,¶ Peter C. Duke, M.D.,** Norman Head, M.S.,†† Holly Dec-Silver, R.N., R.C.P.‡‡

The tape recorded EEGs of 127 patients anesthetized with large doses of opioids were retrospectively analyzed for evidence of opioid-induced seizures, and in particular, correlated with movements that occurred during induction and could be clinically interpreted as seizures. Bilateral EEG leads in patients receiving fentanyl (20), sufentanil (20), or alfentanil (87) were recorded. Forty-six of these patients from all opioid groups manifested intense rigidity, as assessed both clinically and by EMGs recorded from eight muscles in 69 of the patients receiving alfentanil. This intense rigidity often resembled seizures, in that the phenomenon entailed severe stiffness of both limbs and trunk, with an explosive onset of myoclonic limb movements, and associated vertical nystagmus. Electroencephalographic observations were extensive, entailing 69 h of paper recordings played back from the tapes, at paper speeds of 30 or 60 mm/s, with detailed annotations from the voice track. These paper recordings were examined in detail independently by three of the investigators, who were unaware of the clinical phenomena that had occurred. The only observed EEG activity that could have been interpreted as epileptiform consisted of small sharp waves related to muscle activity or other artifact. The EEG never indicated seizure activity during these drug-induced movements and rigidity. Reports of opioid-induced seizures are reviewed and a set of criteria is offered to help achieve future consistency and credibility in evaluating this phenomenon. The available evidence does not support the existence of opioid-induced seizures in the clinical setting. (Key words: Anesthetics: intravenous. Central nervous system: seizures; rigidity. Opioids: fentanyl; sufentanil; alfentanil.)

SEVERAL REPORTS DESCRIBE alleged seizures during or after induction of anesthesia with fentanyl,¹⁻⁵ sufentanil,^{6,7}

* Professor, Department of Anesthesiology, University of California, San Diego.

† Assistant Professor, Department of Anesthesiology, University of California, San Diego.

‡ Professor Emeritus, Department of Neurology, University of California, San Diego.

§ Associate Clinical Professor and Chief of Anesthesiology, Veterans Administration Medical Center, San Diego, California.

¶ Assistant Professor, Department of Anesthesia, Northwestern University, Chicago, Illinois.

** Professor, Department of Anesthesia, University of Manitoba, Winnipeg, Canada.

†† Research Associate, University of California, San Diego.

‡‡ Supervisor, Department of Clinical Physiology, Pomerado Hospital, Poway, California.

Received from the Departments of Anesthesiology and Neurology, University of California, San Diego, and the Veterans Administration Medical Center, San Diego, California. Accepted for publication July 21, 1989. Supported in part by Janssen Research Foundation, Inc., Piscataway, New Jersey, and the Veterans Administration Medical Center, San Diego, California.

Address reprint requests to Dr. Smith: Department of Anesthesiology, Veterans Administration Medical Center, La Jolla, California 92161.

or alfentanil.⁸ Unfortunately, the EEG was rarely recorded during any of these episodes, and when it was, no electroencephalographic seizure activity was detected. During several studies with fentanyl, sufentanil, or alfentanil, we have observed during induction 46 episodes similar to the ones described in these reports. As a part of these studies, we had recorded on magnetic tape two leads of the EEG. A review of these EEGs revealed no electrical seizure activity. We therefore suggest that the phenomenon reported by others may represent severe opioid-induced rigidity, rather than true grand mal seizures.

Methods

A retrospective analysis of EEG and EMG data obtained during the induction of opioid anesthesia in several studies was undertaken. The results from some of these studies, performed in patients anesthetized prior to cardiac surgical procedures and including comparative opioid hemodynamic responses as well as depth of anesthesia as assessed by computerized analysis of EEG, have been reported elsewhere.⁹⁻¹¹ The remainder of the data originated from a series of studies that were set up to address the phenomenon of muscle rigidity during alfentanil anesthesia as well as a systematic survey of drugs selected to prevent rigidity. The initial phase of these studies describing hemodynamic, metabolic, and electromyographic changes during rigidity, as well as a comparison among the EEGs induced by the three opioids and thiopental¹² plus a description of the effects of muscle movement on the EEG, have been reported.¹³ All of the studies were conducted under guidelines approved by the Human Research Committees of the University of California and VA Medical Center, San Diego; each patient gave written informed consent.

Of the 127 patients studied, 20 received fentanyl and 20 sufentanil for cardiac surgery. These 40 patients received preanesthetic medication consisting of im morphine 0.13 ± 0.03 mg/kg (mean \pm SEM) and scopolamine 4.9 ± 1.5 μ g/kg 90 min before anesthesia. The remaining 87 patients underwent noncardiac surgical procedures and received alfentanil for anesthetic induction, either 150 μ g/kg (n = 18) or 175 μ g/kg (n = 69). Preanesthetic medication in this group consisted of lorazepam (1-3 mg) po and cimetidine (300 mg) po the evening before surgery, and cimetidine (300 mg) po with morphine sulfate (0.1-0.15 mg/kg) im the morning of surgery. Immediately

before anesthetic induction, each patient received lactated Ringer's solution, 7 ml/kg, intravenously over a 5-min period to help prevent alfentanil-induced hypotension ($n = 69$, the second group), followed by 100% O₂ (5 l/min) by mask for at least 5 min or until the tcO₂ was greater than 200 mmHg ($n = 87$).

In all studies, six gold-cup EEG electrodes were placed on each patient before induction of anesthesia; two each in the FP1-01 and FP2-02 positions, and two as indifferent electrodes. After abrasion of the skin with Omniprep[®], Hewlett-Packard electrode jelly was used to achieve a low-contact impedance (7,000 Ω or less), with collodion and gauze serving both as adhesive and seal. Each set of three electrodes was inserted into a shielded ribbon cable connected to an 8811A amplifier in a Hewlett-Packard strip-chart recorder. The high- and low-pass filters were set at 0.5 Hz and 1,000 Hz, respectively. The latter setting helped preserve the higher frequency information; any further filtering was performed as needed before analysis. A 10-Hz sine wave from a function generator was fed into the strip-chart recorder, and the generator adjusted so that the sine-wave amplitude matched that of the 100- μ v calibration signal from the HP recorder. The 100- μ v 10-Hz calibration signal was entered into each patient's analog magnetic tape recording for future reference. The possibility that rigidity is a manifestation of subcortical seizures was addressed in four patients (alfentanil group) monitored with intranasal electrodes in addition to the cortical leads. These were used to monitor a subcortical EEG during anesthetic induction.

The 69 patients receiving the higher dose of alfentanil (175 μ g/kg) also underwent electromyographic monitoring to quantitatively assess rigidity during induction of anesthesia. Following Omniprep[®] skin preparation, triplets of EMG electrodes, placed 8 cm apart, were arranged over each of the following muscle groups: deltoid, right and left biceps, anterior forearm muscles, intercostal (7th, 8th, or 9th interspace), rectus abdominis, vastus medialis, and gastrocnemius. The EMG was recorded using a Hewlett-Packard 9811A amplifier. Again, a 10-Hz 100- μ v signal was entered into the tape recorder for future reference.

In addition to the EMG, a clinical assessment of rigidity was performed by an investigator who observed any patient movement, palpated the abdomen, attempted to flex an upper extremity and a foot, and observed any patient response to that attempt, as well as an anesthesiologist who attempted to ventilate the patient's lungs by mask prior to administering muscle relaxants.

Blood pressure (radial arterial), electrocardiogram (ECG-lead CMV₅), tcO₂, SpO₂, and pulmonary arterial (fentanyl/sufentanil) or central venous (alfentanil) pressure wave forms along with the EEG signals were recorded on a Crown-Vetter[®] Model A tape recorder at 3 $\frac{3}{4}$ ips.

EMG signals (alfentanil patients) were recorded on an Ampex FR-1400A tape recorder at 3 $\frac{3}{4}$ ips. On all tape recordings, detailed voice entry was used to document all events. Tape recordings were continued through the induction period until the time of incision (fentanyl/sufentanil) or for 15 min postinduction (alfentanil).

An awake control EEG was recorded for 5 min from each patient, followed by 5 min of breathing oxygen before anesthetic induction. Patients undergoing cardiac surgery (fentanyl/sufentanil) received 25 μ g/kg of pancuronium before induction of anesthesia. Incremental doses of fentanyl (50 μ g/min for 4 min, 100 μ g/min for 3 min, and 250–500 μ g/min thereafter), or sufentanil (10 μ g/min for 4 min, 20 μ g/min for 3 min, and 50–100 μ g/min thereafter) were administered until these patients were clinically anesthetized as indicated by loss of response to verbal commands. Rigidity was clinically assessed as described above. Muscle relaxants (pancuronium 80 μ g/kg and metocurine 150 μ g/kg) were subsequently used to achieve conditions suitable for tracheal intubation.

In the other set of patients, anesthesia was rapidly induced with alfentanil given as an injection of 150 μ g/kg (18 patients) or 175 μ g/kg (69 patients) over 1 min. With the first group (18 patients) tracheal intubation was facilitated with either succinylcholine 1.5 mg/kg or pancuronium 100 μ g/kg given just after or immediately before the alfentanil, respectively. All patients in the second alfentanil group were observed for up to 5 min at which time they received a combination of pancuronium 50 μ g/kg and metocurine 100 μ g/kg both to abolish rigidity and to facilitate intubation. Isoflurane and N₂O were used to supplement anesthesia following intubation in both groups.

The tapes, both EEG and ECG, were played back into a Beckman EEG chart recorder at speeds of 30 or 60 mm/s, with all annotations transcribed from the voice channel of the tape. These annotations were recorded on separate sheets of paper, with references to the page numbers on the EEG charts. The EEG charts were examined independently by three readers unaware of the clinical states of the patients and who searched particularly for epileptiform activity, including sharp waves, spikes, and spike waves. These three investigators each read a total of 2,227 min (13,360 pages) of EEGs for fentanyl and sufentanil, and 1,943 min (11,658 pages) for alfentanil.

For consistency among studies, the phenomenon that we have called rigidity was divided into three groups: none, mild, and intense. Mild rigidity is defined as increased body muscle tone during which the lungs were relatively easy to ventilate *via* bag and mask. During intense rigidity, the lungs were difficult or impossible to ventilate by bag and mask. Intense rigidity was also associated with characteristic limb movement and/or very

tight abdominal muscles, and/or the inability of an observer to flex an extremity, as determined by palpation (see Results).

Seizures were defined according to the definitions provided by Trauner¹⁵ as "a brief paroxysmal clinical event characterized by an altered state of consciousness, and presence of motor activity or abnormal motor activity. Each of these phenomena may occur alone or in combination with any or all of the others. *During a seizure, the EEG shows abnormal, epileptiform activity*" (emphasis ours).

Serum was collected from nine patients receiving alfentanil 175 $\mu\text{g}/\text{kg}$ and frozen at -20°C until analysis. From these samples alfentanil concentrations were quantified by gas liquid chromatography.^{16,17}

Results

Of the 127 patients, 93 manifested mild to intense muscle activity, as determined clinically and, when recorded, by the EMG. Rigidity occurred in seven of 20 patients receiving fentanyl, seven of 20 receiving sufentanil, and 79 of 87 receiving alfentanil. A further breakdown reveals that 46 episodes of rigidity were classified as "intense" (4, 2, and 40 with fentanyl, sufentanil, and alfentanil, respectively) and associated with movements that might be interpreted as seizures.

Before induction of anesthesia, if the patient was anxious, the EEG demonstrated marked sharp wave activity (fig. 1A) that was accompanied by EMG activity that also

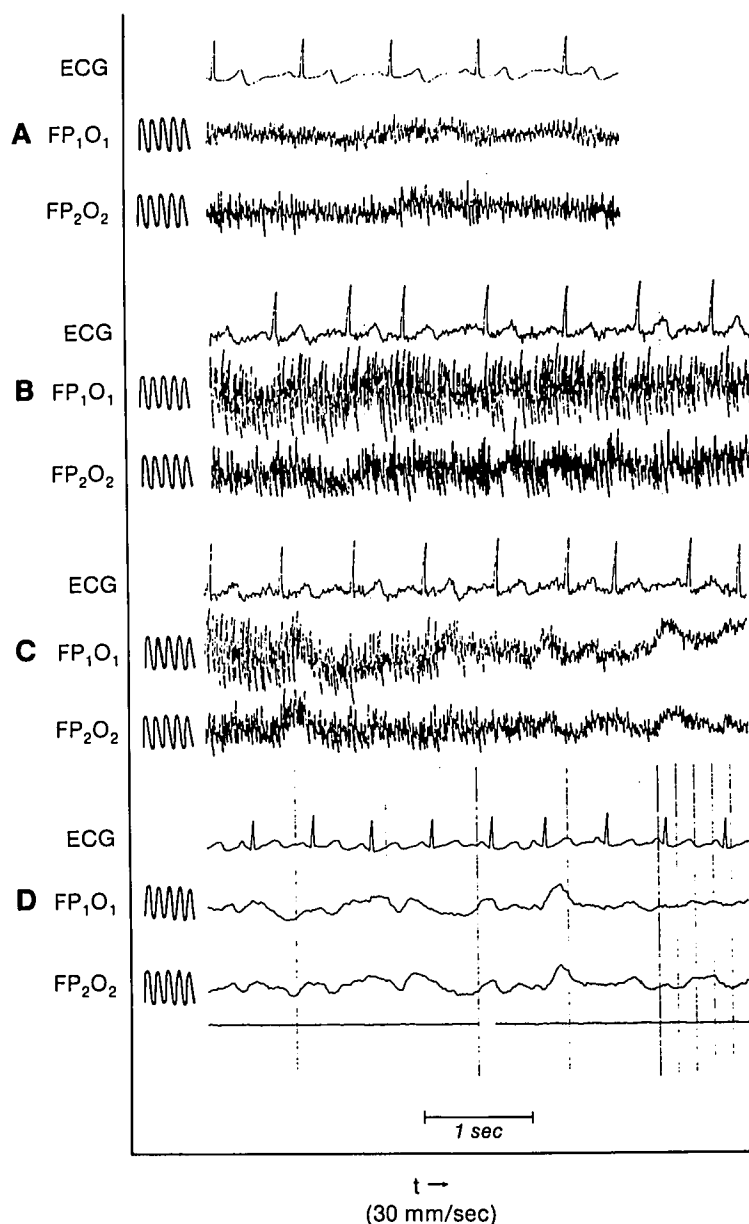


FIG. 1. EEG changes during anesthetic induction with alfentanil. The awake state (A) is followed by loss of consciousness (B) with intense rigidity and sharp waves in the EEG. After muscle relaxants are administered (C), rigidity is rapidly extinguished (C-D), with concomitant loss of sharp wave activity. Reference sine waves are 10 Hz and 10 μV peak-to-peak. Please compare this muscle activity with true seizures (fig. 5). Elapsed time between beginning of A and the end of D was 8 min.

contained abundant sharp wave activity. In both sets of recordings, the sharp wave activity fluctuated with movement or relaxation. After induction, high-amplitude slow waves characteristic of deep opioid anesthesia¹³ appeared. If rigidity occurred, sharp wave activity was superimposed on the slow waves (fig. 1B). These sharp waves disappeared after injection of a neuromuscular blocking drug (figs. 1C, 1D) at a rate consistent with the onset of action of that agent, and with the disappearance of spontaneous EMG activity, if the latter was recorded. This temporally associated similarity between the EMG and EEG muscle noise is summarized in figure 2. The three investigators who read the playback EEGs agreed that, in no instance, with any of the opioids, was epileptiform EEG activity present ("physiologic" sharp waves, spikes, spike waves, or frank seizures) after neuromuscular blockade. All random or periodic sharp waves that occurred after the establishment of the neuromuscular blockade could be related to the ECG, infusion pumps, electrode or cable movement, electrical interference, including pacemakers or nerve stimulators, or head movement. Some examples of artifactual spike waves are shown in figure 3.

Filtering of the signal greatly influenced the appearance of the sharp waves (fig. 4). With a 70-Hz low-pass filter, the sharp waves were obviously artifact (fig. 4A); with a 50-Hz filter, the same waves resembled the sharp waves described in the anesthetic and other literature (fig. 4C); and with a 15-Hz filter, they resembled neither sharp waves nor artifact (fig. 4B). Sharp wave artifacts became more apparent as the opioid took effect and eliminated high-frequency cortical activity while accentuating low-frequency activity.

Clinically, rigidity was often explosive in onset (particularly with alfentanil), and occurred almost simultaneously with the loss of response to voice. This phenomenon appeared as flexion of the upper extremities at the fingers, wrists, and elbows; extension at the toes, ankles, knees, and hips; immobilization of the head and neck with the chin flexed onto the chest; severe rigidity of the abdominal and chest wall musculature frequently with athetoid or myoclonic movements of the extremities, as well as vertical nystagmus. Before the onset of paralysis and relaxation, extension of the neck and insertion of an oral airway were impossible. Following the effect of muscle relaxants, clin-

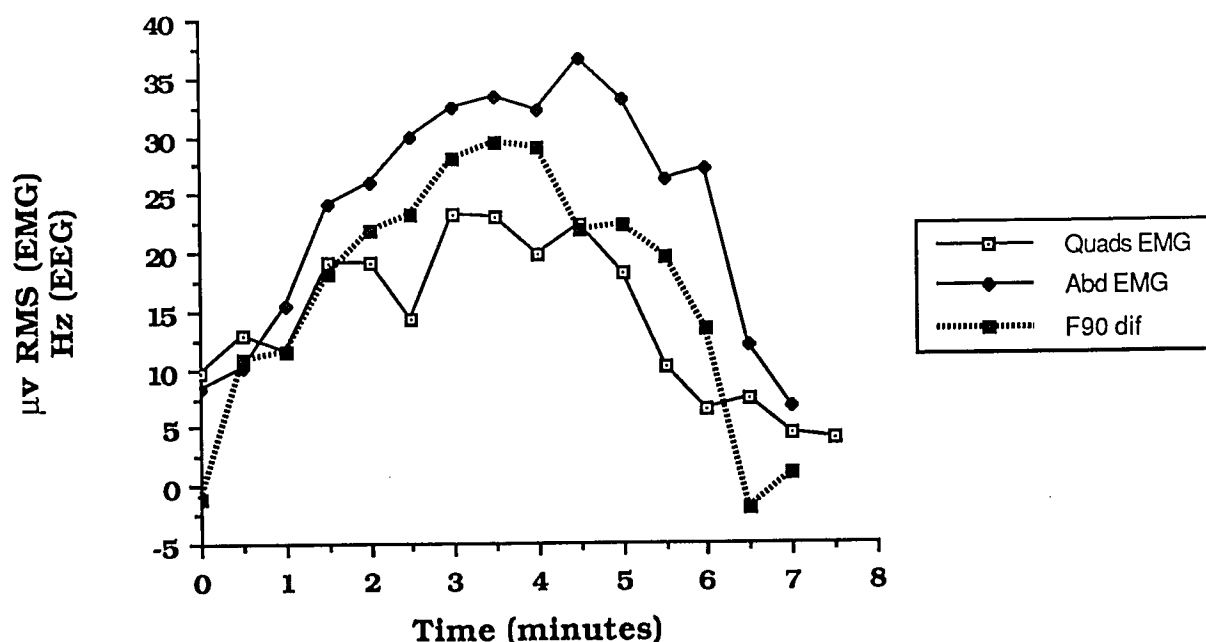


FIG. 2. A comparison between changes in the EMG and that portion of the EEG that may be related to muscle noise, as recorded before, during, and after alfentanil-induced rigidity (F90 dif = F90 difference. F90 is the frequency below which 90% of the EEG activity lies). To compute the F90 difference, we subtracted the mean F90 values obtained in patients who received alfentanil but had no rigidity (n = 18) from the mean EEG values obtained in patients during severe alfentanil-induced rigidity (n = 10). Each mean represented a 30-s period. The difference, we assume, reflects at least qualitatively the influence of EMG activity on the EEG recording, since we have essentially subtracted the EEG from the EEG + muscle noise. We then plotted that difference as a function of time. On the same graph we plotted the EMG from two muscle groups as a function of time. In spite of the fact that the EEG differences and the EMG represent different recordings, different computations, and different units, it is interesting to note that these plots follow each other reasonably closely, including the rapid changes during the onset and resolution of rigidity. Other differences calculated from other variables derived from the EEG showed the same pattern as the F90 difference. The similarity between the EEG difference and the RMS of the EEG suggests that the EMG noise in the EEG closely tracks the EMG recorded from other sources. RMS = root mean square, Quads = quadriceps, Abd = abdominal, F90 dif = F90 difference, as explained above. Alfentanil was administered at time 0 min and the neuromuscular blocking agents between minute 4 and minute 5.

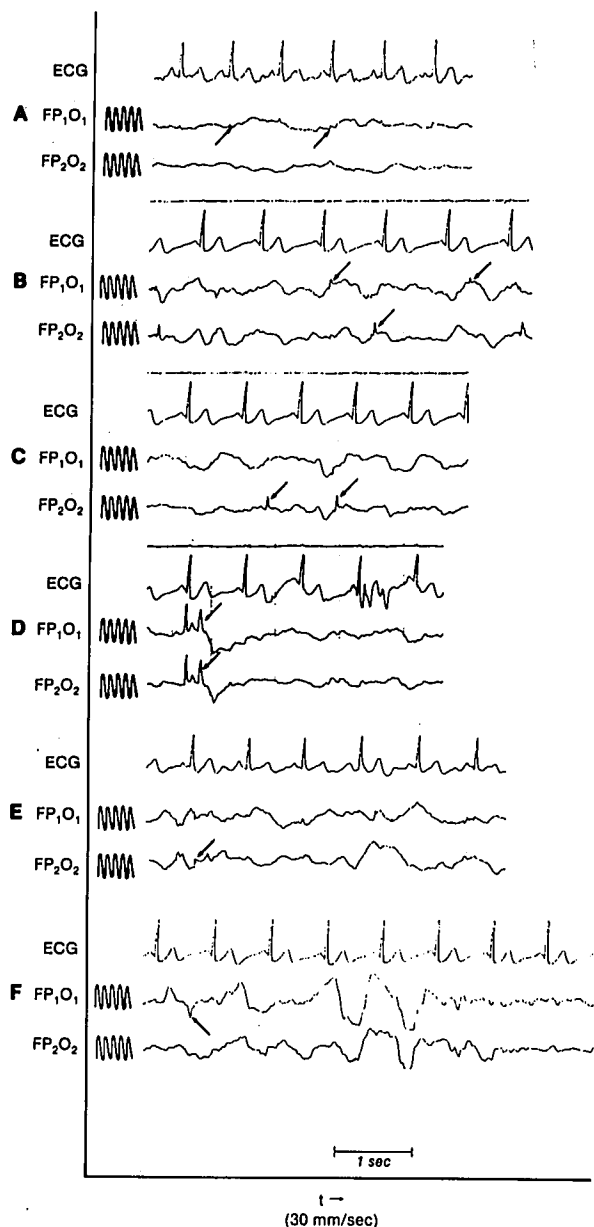


FIG. 3. Examples of small nonphysiologic waves during opioid anesthesia (indicated by arrows). (A) low amplitude, sharp waves of electrocardiographic origin. Sections B-F are examples of sharp waves due to lead or electrode movement, some of which are indicated by arrows. Note wide swings in amplitude with head movement in F. Reference sine waves are 10 Hz and 10 μ V peak-to-peak.

ical and EMG evidence of rigidity was completely eliminated, and no difficulties in ventilation or intubation were subsequently encountered.

On 30 occasions, twitching or clonus occurred in one or more extremities before the injection of neuromuscular blocking agents. In three patients, this was possibly related to sudden flexion of an extremity, which was one of the maneuvers used to assess rigidity. The EEG showed si-

multaneous spiking that disappeared as the relaxants took effect, suggesting that this spiking was motion artifact or that the phenomenon was a feedback clonus.

No epileptiform activity was detected in the four patients who underwent EEG monitoring with intranasal electrodes, although they all manifested severe rigidity following administration of alfentanil.

The hemodynamic changes that accompany rigidity were remarkable only for increases in CVP and PAP values, which returned to control levels following the administration of muscle relaxants. These results, which have been reported in detail elsewhere,¹⁴ do not suggest the sympathetic nervous system activation that is typical of grand mal seizures.

In nine patients after injection of 175 μ g/kg, the mean peak serum concentration of alfentanil was 2,098 ng/ml, with a range of 1,097-4,480 ng/ml and SD of \pm 1,102 ng/ml. Intense rigidity was noted in all of these patients.

Discussion

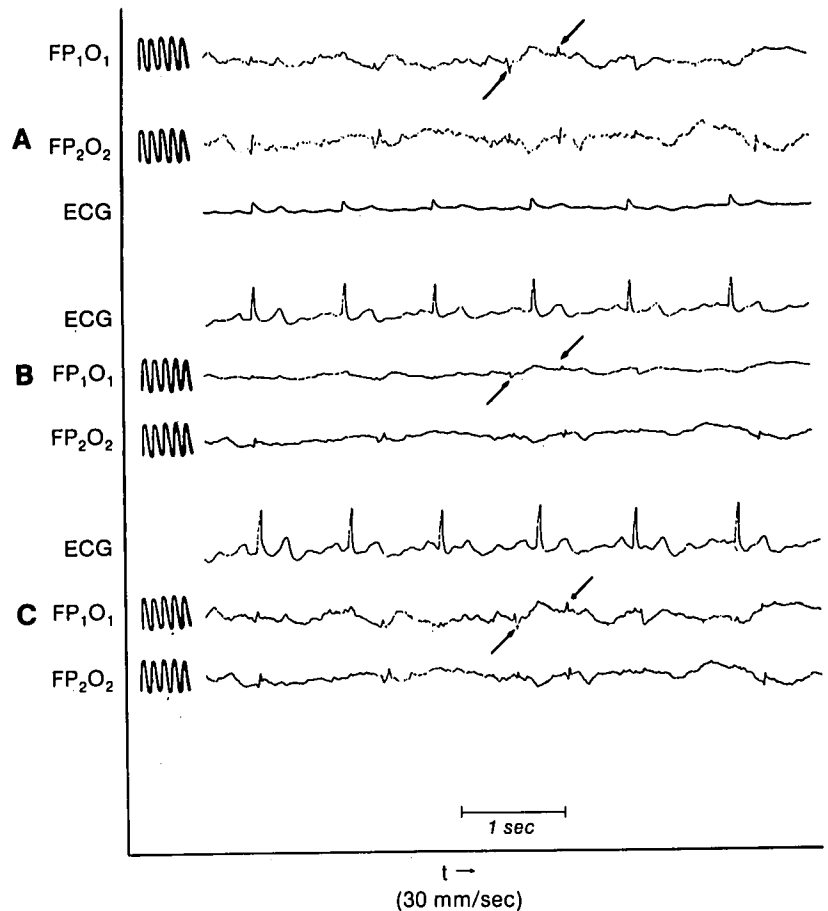
Opioids do produce seizures in animals under certain circumstances. Electroencephalographic seizures in response to morphine and other opioids are well described in animal studies. Morphine has both pro- and anticonvulsant effects in the rat,¹⁸ and opioid actions are species specific, both qualitatively and quantitatively. De Castro¹⁹ reported that fentanyl and fentanyl analogs induce morphine-like EEG seizures in dogs. The more potent the analog, the greater the ratio of the dose inducing convulsions to that producing surgical anesthesia, however.

Nonetheless, our data, and those of others, do not support the clinical occurrence of these seizures in humans. The EEG changes associated with high-dose opioid anesthesia in humans are well characterized^{10,12,20-22} and seizures were not observed in these or in the present studies. Why, then, have others suggested that fentanyl can induce seizures in large, as well as relatively small, doses? Let us first examine these case reports that suggest that seizures do occur.

The first report¹ describes seizures in five patients receiving large and rapid iv injections of fentanyl. Details are provided for two of these episodes in which the patients' movements reportedly resembled grand mal seizures. One patient was noted to have a hypertensive response during the seizure. The total number of patients undergoing this type of fentanyl induction was not given, and EEG monitoring was not in use when these events occurred. However, in a subsequent letter Rao and El-Etr²³ suggested that fentanyl seizures can be induced consistently by rapid administration of large doses, although again they did not provide supportive EEG evidence.

Safwat and Daniel² described one patient as having seizures that occurred after a total of 200 μ g of fentanyl,

FIG. 4. The influence of filtering on the appearance of artifact activity. Each section is from the same section of tape, but filtered differently before being recorded on the strip chart. The head and the electrodes were being moved during this interval. (A) 70-Hz filter. The sharp waves appear to be what they really are: artifact. This is the highest low-pass setting for the Beckman Accutrace®. (B) 15-Hz low-pass filter. The artifact now more nearly resembles real EEG. (C) 50-Hz low-pass filter, the same setting as that used by many investigators.^{21,22} Now the artifact appears more like sharp waves. Note the resemblance of the sharp waves in this panel to those in the figures in these papers. The arrows point to two representative sharp waves in each section. Reference sine waves are 10 Hz and 10 μ V peak-to-peak.



given in divided doses over an unspecified time. Diazepam 5 mg iv preceded the fentanyl. Generalized clonic motor activity characterized the patient's movements. Interactions with medications such as preoperative quinidine or glycopyrrolate, given prior to anesthesia, should be considered in assessing this report.

Hoiem³ described a grand mal seizure-like episode in which the patient dislocated both shoulders; this occurred after 100 μ g fentanyl. Preanesthetic medication, the emotional state of the patient on entry into the operating room, and the presence or absence of hyperventilation or fever were not stated.

Baraka and Haroun⁴ observed multiple seizure-like episodes after a bolus of 10 μ g/kg fentanyl given over 2 min followed by 2 mg/kg of lidocaine. They suggested that fentanyl decreased the convulsant threshold for lidocaine. Recently, pretreatment with opioids, including morphine and fentanyl, has been shown to increase plasma levels of lidocaine in mice with resultant increased lidocaine toxicity.²⁴ Thus, a drug interaction involving lidocaine toxicity cannot be discounted if seizures did occur, as suggested by these authors.

A more recent report described a tonic and clonic

grand mal seizure following recovery from anesthesia.⁵ The patient received a total of 150 μ g fentanyl and 35 mg etomidate for a 10-min procedure. The seizure occurred 2 min following the termination of anesthesia at a time when the patient was described as awake and communicating. Diazepam 10 mg terminated the event. To account for the delay in onset of the seizure, the authors postulated that, as the anticonvulsant effect of etomidate receded, the convulsant effect of fentanyl was unmasked. We have observed that etomidate, as well as thiopental and midazolam, does have a relatively brief protective effect against rigidity.§§

A similar report²⁵ to that by Goroszeniuk *et al.*⁵ describes prolonged myoclonic movements after 4 h of anesthetic that included fentanyl 475 μ g and etomidate 350 mg. However, these authors attributed the myoclonus to emergence from etomidate and elected to observe the patient for the next hour. A postoperative EEG was not

§§ Blasco TA, Smith NT, Sanford TJ, Benthuysen J, Dec-Silver H, Head N: A clinical study of the effect of various pretreatment agents on alfentanil-induced rigidity: EMG data. ANESTHESIOLOGY 63:A380, 1985.

performed, and seizures were not discussed as a potential cause.

While there are cerebral protective²⁶ and anticonvulsant^{27,28} effects of etomidate, Ghoneim and Yamada²⁹ advised against its use in patients with epilepsy, due to EEG activation. In a prospective study, etomidate has been shown to activate foci in patients with known epilepsy³⁰ and has been used to activate foci in patients undergoing neurosurgical seizure focus mapping.³¹ Thus, seizures, if they occurred in these two reports, cannot be attributed to fentanyl alone.

Two clinical reports describing seizures associated with sufentanil anesthesia have also recently appeared in the literature.^{6,7} These reports are similar to those associated with fentanyl,¹⁻⁵ with respect to the onset of myoclonic movements and vertical nystagmus during anesthetic induction. In these reports, patient heart rate and blood pressure were noted to be unchanged at the time these movements occurred.

Very recently, Strong and Matson⁸ described movements similar to the ones we have observed after large doses of alfentanil. They administered 25 $\mu\text{g}/\text{kg}$ alfentanil to a patient and observed a tremor in the right arm, and then in the left arm, followed by coarse, jerking movements of both legs. "Then his eyes rolled up and he became unresponsive . . . and he continued to breathe until he lost consciousness (sic)." The movements stopped soon after the patient received thiopental 100 mg. On the first postoperative day the patient was noted to have a new left facial droop, slurred speech, and right-sided weakness. The clinical diagnosis was a left CVA. A CT scan was obtained but an EEG was not. Three days postoperatively the neurologic deficits were "largely resolved." Although the authors did describe the cardiovascular monitoring, they did not mention changes in blood pressure or heart rate. They also did not mention the possibility that the patient could have suffered an unrelated CVA during induction of anesthesia.

There are some similarities within these reports. While preoperative cardiac medications were described in some of the reports, it is unclear as to whether the complete drug history was given. With five of these case reports,^{1-3,6,8} the observed movements terminated after administration of thiopental, while in others^{4,5} diazepam 10 mg preceded cessation of movements. The success of thiopental or diazepam in halting the event could imply that seizures were involved, since both of these agents are used in the therapy of drug-induced seizures, particularly those caused by local anesthetics. However, our results indicate that these agents, given in doses equivalent to or less than the doses mentioned in the reports, could also stop or attenuate rigidity. §§

In all but two reports the patients underwent a postoperative neurological examination, including an EEG.^{4,9}

These examinations indicated no EEG abnormalities. However, no mention was made in any report of the use of hyperventilation or stroboscopic light to bring out a propensity toward seizures.

The above clinical reports¹⁻⁷ implicate seizures induced by fentanyl or sufentanil as a cause for the unexpected movements. Similar patient movements have been described in other investigational settings, but these reports have been more cautious in labeling these movements as seizures.

For example, Bailey *et al.*³² reported tonic-clonic activity in seven of 72 patients receiving fentanyl 30 $\mu\text{g}/\text{kg}$ for anesthetic induction. This phenomenon was felt to differ from rigidity, which was also observed; however, the preanesthetic medication in this subset of patients was not stated, and EEGs were not reported.

There do exist two case reports that provide a detailed description of seizure-like movements during the induction of opioid anesthesia and include simultaneous EEG recordings, and, in one case serum fentanyl concentrations. Scott and Sarnquist³³ reported myoclonic movements during a fentanyl infusion in one patient. The movements were described as unilateral jerking of the upper extremity, becoming bilateral, and then involving the lower extremities. No tonic phase was noted. Subsequently, succinylcholine was given. The EEG, which reflected cortical activity with and without muscle artifact, showed typical opioid slow wave activity. A similar report by Bowdle³⁴ describes severe myoclonus and rigidity during induction with sufentanil. The EEG again revealed simultaneous slow wave (δ) activity during these movements. Hypertension and tachycardia were reported during these events. However, in both of these reports, EEG findings were similar to the EEGs of patients in our study, in that seizure activity was not detected during the observed movements, nor was a postictal phase described.

Seizure-like activity has also been reported in a patient receiving sufentanil and, on a different occasion, fentanyl. In this clinical report, Katz *et al.*³⁵ describe EEG changes during the fentanyl episode (the actual EEG is unpublished) consistent with those of Scott and Sarnquist,³³ Bowdle,³⁴ and ourselves, *i.e.*, the absence of EEG seizure activity during the observed patient movements. However, Katz *et al.* speculate that this could not have been rigidity because of pretreatment with a defasciculating dose of muscle relaxant. In the controlled setting of our earlier studies, we noted that low, defasciculating doses of relaxants alone have minimal effects upon rigidity, as determined by the EMG. §§

An attempt to produce fentanyl seizures was prospectively investigated by Murkin *et al.*³⁶ Their study was designed to reproduce or even exceed the dose and serum fentanyl concentrations reported by Rao and El-Etr²³ to produce seizures. Fentanyl was rapidly administered to

six patients with simultaneous EEG recordings and, subsequently, the EEG reflected high amplitude 1–3 Hz slow waves with occasional small sharp waves, just as recorded in our patients. No clinical or electroencephalographic seizures were noted.

In our study we observed in 46 of 127 patients a clinical phenomenon that might be misinterpreted as convulsions or seizures. Consonant with this hypothesis of misinterpretation are the sudden onset, the apparent involvement of all muscles, the flexion of the arms with occasional myoclonic or athetoid movements, the occasional rapid vertical nystagmus, and the waxing and waning of the rigidity. Provocative stimuli such as loud noises, manipulation of the airway, or extension of a rigidly flexed arm or foot frequently induced sudden, even violent, myoclonic or athetoid movements. True clonic movements of the limbs were seen in 34% of all patients, a phenomenon that could easily be mistaken for seizures.

The relatively high incidence of severe rigidity occurred following injection of alfentanil because we chose a dose that, based on earlier studies, would induce marked rigidity. In a way, alfentanil may be considered a clinical model for this phenomenon, since, because of its kinetics, it is relatively easy to produce severe rigidity with clinical doses of the agent. Although to our knowledge there has been no study correlating plasma concentrations of alfentanil with seizures, those measured in our patients were very high.

Our contention that the phenomenon described in our study is not related to seizures rests mainly upon our analysis of the EEG.

- 1) The EEG at no time showed evidence of frank seizure activity, even during intense muscle activity.
- 2) The artifactual muscle noise present during the preinduction period continued in a similar pattern during rigidity.
- 3) The rate of onset of increased EMG activity and what we are calling EEG muscle artifact proceeded *pari passu* and at a rate consistent with the onset of the actions of the opiate and of the neuromuscular blocking agent(s) under those circumstances (fig. 2).
- 4) The general muscle activity and the EEG muscle activity (sharp wave) were either absent or greatly attenuated in the 18 patients in whom the injection of a neuromuscular blocking agent either preceded (pancuronium) or immediately followed (succinylcholine) the injection of alfentanil. In addition, the EMG activity with associated EEG sharp wave activity markedly increased with the onset of rigidity and disappeared after the delayed administration of the neuromuscular blocking agents (fig. 2).
- 5) In the absence of rigidity, little or no artifactual EEG was present.

- 6) There was no electroencephalographic evidence of a postictal state, as occurs after seizures induced by inhalation³⁷ (fig. 5) or local anesthetics.³⁸

Other evidence indicates that the phenomenon that we witnessed was not seizures. The EEGs of four patients manifesting severe alfentanil-induced rigidity were mon-

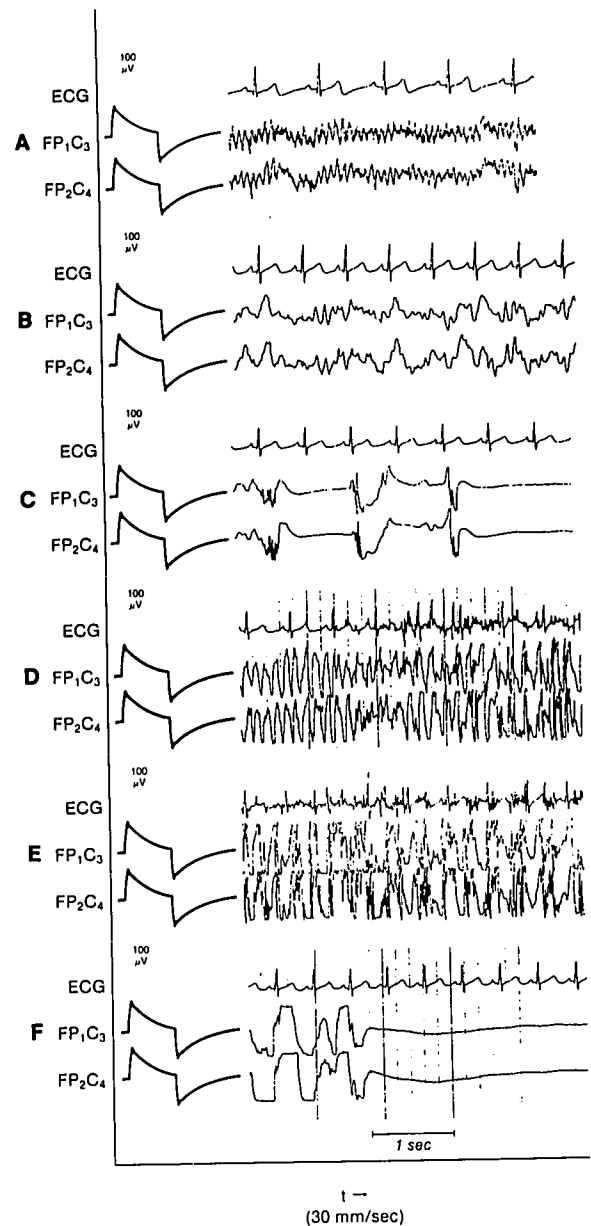


FIG. 5. An example of electroencephalographic seizures during enflurane anesthesia in an unpremedicated volunteer subject. The EEG shows a continuum from the awake (A) to asleep (B) state at 1.08 MAC of enflurane. This is followed by burst suppression at 1.5 MAC (C). Obvious seizure activity (D, E) occurs as the dose of enflurane is increased, with progression to seizure bursts followed by postictal silence (F). 100-μV peak-to-peak calibration signals precede the EEG traces.

itored with intranasal electrodes that can detect hippocampal activity. Epileptiform activity was not detected at any time in this lead. In addition, unlike the EEGs as reported here or by others,^{22,33,34,36} whenever opioid-induced motor seizures have been observed in animals, typical seizure patterns have been present in the cortical EEG. Not only could we not detect EEG manifestations of seizure activity, the occasional isolated sharp spikes that we did observe (fig. 3) were attributable to electrical or mechanical artifact. Our contention that the sharp waves were artifact is based on at least two factors: the events described on the taped annotations, and the setting of the low-pass filter on the EEG. Artifact is much more obvious at higher settings (fig. 4). Even if we had observed physiologic sharp waves, it would not necessarily indicate epileptiform activity, since the small sharp wave is controversial as an indicator of epileptiform activity.³⁹

Finally, pronounced cardiovascular stimulation generally occurs during opioid seizures as described by de Castro *et al.*¹⁹ in the dog. Signs of sympathetic activity were not present in our patients during rigidity.¹² Except for an episode of hypertension noted in the first case report,¹ signs of sympathetic activity were not mentioned in the other reports.

In spite of all the circumstantial evidence described above, we do not have incontrovertible evidence that none of our patients experienced seizures. While no seizure activity was actually observed in the recordings obtained from the surface electrodes, seizure activity could have been present in deeper structures, such as the hippocampus or the amygdala. Lidocaine, for example, can induce epileptiform activity in these areas, without manifesting any cortical activity.⁴⁰ Fentanyl in the rat has been shown to produce hippocampal seizures³⁹ with increased subcortical metabolism and blood flow.³⁹ This is of concern because limbic structures are vulnerable to damage from prolonged seizures or hypoxic/ischemic insults.^{41,42-47} Seizures in these areas would have been detected by the intranasal electrodes, but four patients represent too small a number to draw any negative conclusions.

As the above discussion suggests, multiple factors must be evaluated in the assessment of movements during anesthesia and their possible relationship to seizures. For the future, we suggest some minimal criteria to help assure the credibility of case reports relating to opioid-induced seizures. These criteria are outlined in table 1. Unpredictable, rare idiosyncratic responses to opioids cannot be discounted, nor can the possibility that opioids can induce seizures in patients with a propensity towards seizures. We therefore suggest that to help answer this question and to guide therapy of what seems to be a relatively common event, the EEG be used routinely to monitor patients receiving these drugs. We realize that this would

TABLE 1. Criteria for Reporting Opioid Seizures

-
- A complete description of the patient's medical history, including pertinent negative findings, where appropriate. This would include a propensity toward seizures, as elicited by direct questioning.
 - A complete description of the patient's chronic preoperative medications, including antipsychotic medications.
 - A history of chemical dependency, including alcohol, with a description of the amount consumed, and the date of the last consumption.
 - The patient's emotional state upon entering the operating room, including the presence or absence of hyperventilation.
 - The presence or absence of fever.
 - A description of the alleged seizure phenomenon, including rate of drug administration, time of onset in relation to the injection of the drug(s), speed of onset, parts of the body involved, duration, and any indication of presence or absence of a postictal state.
 - A detailed description of any cardiovascular changes accompanying the "seizures."
 - Technically sound recordings of the EEG, with a permanent record if at all possible, to provide a series of illustrations to help the reader perform an independent interpretation. A recording of the ECG should accompany any illustrations of the EEG to establish that sharp waves on the latter are not electrocardiographic in origin.
 - A postoperative neurological assessment and EEG recordings, including those recorded during hyperventilation and stroboscopic light stimulation.
-

require a significant change in monitoring approach for many anesthetists, but we see no other way to definitively answer the questions posed by our observations.

Although our study was retrospective, in many respects the quality of our data was equivalent to or better than those obtained from most prospective studies. All EEG data were recorded and stored in analog electronic form. This means that no EEG data were lost or discarded as they would have been with paper or digital storage, and that the playback could be tailored to produce records that were optimal for reading and interpretation, for example by varying paper speed during playback. In addition, electronic storage of data allows computer processing of the data (fig. 2). The extensive voice annotations possible with tape recordings allowed us to examine in detail the relationship between EEG activity and such events as intubation, head movement, cable artifact, changing patient position, or the use of infusion devices. In addition, a running account of the various manifestations of opioid rigidity was described. It should be emphasized that voice annotations allow considerably more detail than do written ones. These factors help compensate for the lack of a prospective protocol.

In summary, we have described in 46 out of 127 patients' seizure-like movements that occurred during induction with fentanyl or one of its analogs, sufentanil or alfentanil. On closer inspection, this phenomenon was not typical of seizures, but rather of intense, opioid-induced

rigidity. Most importantly, the EEG did not demonstrate seizures, either during myoclonic motor activity or after motor activity was abolished by neuromuscular blocking agents. Based upon our results and a review of case reports, we suggest that opioid-induced seizures rarely, if ever, occur in the clinical setting. Considerably more detail, along with EEG evidence, needs to be included in future case reports to establish that opioid seizures do occur during clinical anesthesia in humans.

References

1. Rao TLK, Mummaneni N, El-Etr AA: Convulsions: An unusual response to intravenous fentanyl administration (letter). *Anesth Analg* 61:1020-1021, 1982
2. Safwat AM, Daniel D: Grand mal seizure after fentanyl administration (letter). *ANESTHESIOLOGY* 59:78, 1983
3. Hoiem AO: Another case of grand mal seizure after fentanyl administration (letter). *ANESTHESIOLOGY* 60:387-388, 1984
4. Baraka A, Haroun S: Grand mal seizures following fentanyl-lidocaine (letter). *ANESTHESIOLOGY* 62:206, 1985
5. Goroszeniuk T, Albin M, Jones RM: Generalized grand mal seizure after recovery from uncomplicated fentanyl-etomidate anesthesia. *Anesth Analg* 65:979-981, 1986
6. Molbegott LP, Flashburg MH, Karasic HL, Karlin BL: Probable seizures after sufentanil. *Anesth Analg* 66:91-93, 1987
7. Brian JE Jr, Seifen AB: Tonic-clonic activity after sufentanil (letter). *Anesth Analg* 66:481-483, 1987
8. Strong WE, Matson M: Probably seizure after alfentanil. *Anesth Analg* 68:692-693, 1989
9. Sanford TH Jr, Smith NT, Dec-Silver H, Harrison WK: A comparison of morphine, fentanyl, and sufentanil anesthesia for cardiac surgery: Induction, emergence, and extubation. *Anesth Analg* 65:259-266, 1986
10. Smith NT, Dec-Silver H, Sanford TJ Jr, Westover CJ Jr, Quinn ML, Klein F, David DA: EEGs during high-dose fentanyl-, sufentanil-, or morphine-oxygen anesthesia. *Anesth Analg* 63:386-393, 1984
11. Benthuyzen JL, Foltz BD, Smith NT, Sanford TJ, Dec-Silver H, Westover CJ: Prebypass hemodynamic stability of sufentanil-O₂, fentanyl-O₂, and morphine-O₂ anesthesia during cardiac surgery: A comparison of cardiovascular profiles. *J Cardiothorac Anesth* 12:6:749-757, 1988
12. Smith NT, Westover CJ, Quinn ML, Benthuyzen JL, Dec-Silver H, Sanford TJ: The EEG of alfentanil: A comparison with other narcotics and with thiopental. *J Clin Monit* 1:236-243, 1985
13. Smith NT, Westover CJ, Quinn M, Benthuyzen JL, Dec-Silver H, Sanford TJ: The effect of muscle movement on the EEG of alfentanil. *J Clin Monit* 2:15-21, 1986
14. Benthuyzen JL, Smith NT, Sanford TJ, Head N, Dec-Silver H: Physiology of alfentanil-induced rigidity. *ANESTHESIOLOGY* 64: 440-446, 1986
15. Trauner DA: Seizures, Neurology for Non-neurologists. Edited by Wiederholt WC. New York, Academic Press, 1982, p 283
16. Phipps JA, Sabourin MA, Buckingham W, Strunin L: Detection of picogram concentrations of fentanyl in plasma by gas-liquid chromatography. *J Chromatogr* 272:392-395, 1983
17. Gillespie TJ, Gandolfi AJ, Maiorino RM, Vaughan RW: Gas chromatographic determination of fentanyl and its analogues in human plasma. *J Anal Toxicol* 5:133-137, 1981
18. Frenk H: Pro- and anticonvulsant actions of morphine and the endogenous opioids: Involvement and interactions of multiple opiate and non-opiate systems. *Brain Res Rev* 6:197-210, 1983
19. de Castro J, Van De Water A, Wouters L, Xhonneux R, Reneman R, Kay B: Comparative study of cardiovascular, neurological, and metabolic side-effects of eight narcotics in dogs. *Acta Anaesthesiol Belg* 30:5-99, 1979
20. Smith NT, Silver H, Sanford TJ, Westover CJ, Quinn ML: The EEG during high-dose fentanyl, sufentanil, or morphine-oxygen anesthesia. *Anesth Analg* 63:386-393, 1984
21. Bovill JG, Sebel PS, Wauquier A, Rog P, Schuyt HC: Influence of high-dose alfentanil anaesthesia on the electroencephalogram: Correlation with plasma concentrations. *Br J Anaesth* 55:199S-209S, 1983
22. Sebel PS, Bovill JG, Wauquier A, Rog P: Effects of high-dose fentanyl anesthesia on the electroencephalogram. *ANESTHESIOLOGY* 55:203-211, 1981
23. Rao TLK, El-Etr AA: Fentanyl and convulsions (letter). *Anesth Analg* 62:859, 1983
24. Garty M, Ben-Svi Z, Hurwitz A: Opioid effects on lidocaine disposition and toxicity in mice. *J Pharmacol Exp Ther* 234:391-394, 1985
25. Laughlin TP, Newberg LA: Prolonged myoclonus after etomidate anesthesia. *Anesth Analg* 64:80-82, 1985
26. Wauquier A, Ashton D, Clincke G, Niemegeers CJE: Antihypoxic effects of etomidate, thiopental and methohexital. *Arch Int Pharmacodyn Ther* 249:330-334, 1981
27. Ashton D, Wauquier A: Behavioral analysis of 15 anticonvulsants in the amygdaloid kindled rat. *Psychopharmacology (Berlin)* 65:7-13, 1979
28. Hoffman P, Schockenhof P: Etomidat als antikonvulsive substanz. *Anaesthesist* 33:142-144, 1984
29. Ghoneim MM, Yamada T: Etomidate: A clinical and electroencephalographic comparison with thiopental. *Anesth Analg* 56: 479-485, 1977
30. Ebrahim ZY, DeBoer GE, Luders H, Hahn JF, Lesser RP: Effect of etomidate on the electroencephalogram of patients with epilepsy. *Anesth Analg* 65:1004-1006, 1986
31. Gancher S, Laxer KD, Kreiger W: Activation of epileptogenic activity by etomidate. *ANESTHESIOLOGY* 61:616-618, 1984
32. Bailey PL, Wilbrink J, Zwanikken P, Pace NL, Stanley TH: Anesthetic induction with fentanyl. *Anesth Analg* 64:48-53, 1985
33. Scott JC, Sarnquist FH: Seizure-like movements during a fentanyl infusion with absence of seizure activity in a simultaneous EEG recording. *ANESTHESIOLOGY* 62:812-814, 1985
34. Bowdle TA: Myoclonus following sufentanil without EEG seizure activity. *ANESTHESIOLOGY* 67:593-595, 1987
35. Katz RI, Eide TR, Hartman A, Poppers PJ: Two instances of seizure-like activity in the same patient associated with two different narcotics. *Anesth Analg* 67:289-290, 1988
36. Murkin JM, Moldenhauer CC, Hug CC Jr, Epstein CM: Absence of seizures during induction of anesthesia with high-dose fentanyl. *Anesth Analg* 63:489-494, 1984
37. Stockard J, Bickford R: The neurophysiology of anaesthesia, A Basis and Practice of Neuroanaesthesia. Edited by Gord E. Amsterdam/New York, Excerpta Medica, 1985, pp 3-46
38. De Jong RH: Local Anesthetics. Springfield, Charles C Thomas, 1977, pp 84-114
39. Hughes JR: A review of small sharp spikes, EEG and Evoked Potentials in Psychiatry and Behavioral Neurology. Edited by Hughes JR, Wilson WP. Boston, Butterworths, 1983, pp 347-359
40. Tommasino C, Maekawa T, Shapiro HM: Fentanyl-induced sei-

- zures activate subcortical brain metabolism. *ANESTHESIOLOGY* 60:283-290, 1984
41. Maekawa T, Tommasino C, Shapiro HM: Local cerebral blood flow with fentanyl-induced seizures. *J Cerebral Blood Flow Metab* 4:88-95, 1984
 42. Ben-Ari Y, Tremblay E, Riche D, Ghilini G, Naquet R: Electrographic, clinical, and pathological alterations following systemic administration of kainic acid, bicuculline, or pentetrazole: Metabolic mapping using the deoxyglucose method with special reference to the pathology of epilepsy. *Neuroscience* 6:1361-1391, 1981
 43. Lothman EW, Collins RC: Kainic acid-induced limbic seizures: Metabolic, behavioral, electroencephalographic, and neuropathological correlates. *Brain Res* 218:299-318, 1981
 44. Ingvar M, Siesjo BK: Local blood flow and glucose consumption in the rat brain during sustained bicuculline-induced seizures. *Acta Anaesthesiol Scand* 68:129-144, 1983
 45. Siesjo BK: Cell damage in the brain: A speculative synthesis. *J Cereb Blood Flow Metabol* 1:155-186, 1981
 46. Attilio A, Soderfeldt B, Kalimo H, Olsson Y, Siesjo BK: Pathogenesis of brain lesions caused by experimental epilepsy. *Acta Neuropathol* 59:11-14, 1983
 47. Dam AM: Hippocampal neuro loss in epilepsy and after experimental seizures. *Acta Neurol Scand* 66:610-642, 1982