

or lollipop, when, in fact, OTFC is fentanyl base molded in a candy-flavored vehicle that looks more like a lozenge- or suppository-on-a-stick than a traditional sucker or lollipop.^{1,3} The reasons for the flavored vehicle and the stick are clear—to provide a pleasant taste for patients and a safety handle for patients and attendants. The reasons for the repeated use of the terms “candy” and “lollipop” to describe OTFC are not as clear and have sent confusing signals to both the news media and the health consuming public about narcotics in candy form. Even the running title of the Nelson *et al.* article in ANESTHESIOLOGY is “Fentanyl Lollipop Premedication in Children.”¹

OTFC may prove to be a very useful premedicant in children, and its continued development will provide more understanding of transmucosal drug delivery. In addition to OTFC, a number of other new methods for opioid premedication including intranasal sufentanil⁴ and transdermal fentanyl⁵ are now being developed for potential use in children. With so many new preparations of potent opioids now being designed for painless delivery by transmucosal and transcutaneous routes, anesthesiologists should avoid coining misnomers that may give children and their parents mixed messages about preoperative anxiety.

OTFC and transdermal fentanyl are not candy, lollipops, or funny stickers; they are preparations of an ultra-potent opioid designed for pain-free administration to children facing surgery. More appropriate lay terms for OTFC and nasal sufentanil might be “lozenge” and “drops,” terms long-applied to drugs (cough drops, nose drops), including topical anesthetics (throat lozenges) and even volatile anesthetics (ether drops). A more appropriate lay term for the fentanyl sticker may be drug patch, now associated with many commonly prescribed transcutaneous drugs including nitroglycerin, clonidine, and scopolamine.

In any event, anesthesiologists should avoid falling into the same semantic trap radiologists did by initially promoting magnetic resonance imaging (MRI) as nuclear magnetic resonance imaging (NMR).⁶ Both NMR and MRI are accurate, descriptive terms with the former being more needlessly alarming than the latter due to its nuclear preface.⁶ It took years to re-educate the lay public about the safety and effectiveness of NMR, now MRI. Similarly, more carefully chosen lay descriptions for OTFC, intranasal sufentanil, and transdermal fentanyl during early clinical trials will prevent later public confusion and un-

necessary alarm over drugs as premedicants and not as candy, lollipops, suckers, or happy-face stickers.

JAMES H. DIAZ, M.D.
*Director, Pediatric Anesthesia
Ochsner Clinic and
Ochsner Foundation Hospital
New Orleans, Louisiana*

*Clinical Associate Professor of
Anesthesiology
Tulane University School of Medicine
New Orleans, Louisiana*

REFERENCES

1. Nelson PS, Streisand JB, Mulder SM, Pace NL, Stanley TH: Comparison of oral transmucosal fentanyl citrate and an oral solution of meperidine, diazepam, and atropine for premedication in children. ANESTHESIOLOGY 70:616–621, 1989
2. Streisand JB, Hague B, Van Vreeswijk H, Ho GH, Pace NL, Clissold M, Nelson PS, East KA, Stanley TO, Stanley TH: Oral transmucosal fentanyl premedication in children (abstract). Anesth Analg 66:S170, 1987
3. Mock DL, Streisand JB, Hague B, Dzelzkalns R, Bailey PL, Pace NL, Stanley TH: Transmucosal narcotic delivery: An evaluation of fentanyl (Lollipop) premedication in man (abstract). Anesth Analg 65:S102, 1986
4. Henderson JM, Brodsky DA, Fisher DM, Brett CM, Hertzka RE: Preinduction of anesthesia in pediatric patients with nasally administered sufentanil. ANESTHESIOLOGY 68:671–675, 1988
5. Caplan RA, Ready LB, Oden RV, Matsen FA, Nessly ML, Olson GL: Transdermal fentanyl for postoperative pain management. JAMA 261:1036–1039, 1989
6. Council on Scientific Affairs, Panel on Nuclear Magnetic Resonance Imaging: Fundamentals of magnetic resonance imaging. JAMA 258:3417–3423, 1987

(Accepted for publication September 20, 1989.)

Anesthesiology
72:209–210, 1990

In Reply:—We applaud Dr. Diaz’s letter and believe his comments and suggestions are right on target. The initial idea that fentanyl might be absorbed in sufficient quantities and with sufficient speed to produce a useful clinical effect when applied to buccal mucosal surfaces developed after many experiments using a variety of extremely potent opioids in a number of animal models over many years.^{1,2,*} When early experiments with fentanyl crystals in a sweetened base showed that fentanyl plasma concentrations sufficient to provide “anesthesia” were possible if enough of the opioid was incorporated in the OTFC unit, it became popular to call the studies “the lollipop studies.”³ Out of this came the term “the fentanyl lollipop.”

Our interest in this new way of noninvasively administering a potent opioid and our desire to provide an appropriate and simple image of what the unit looked like led us to use the “L” word even after oral transmucosal fentanyl citrate and OTFC were coined. In retrospect,

* Port J, Stanley TH, Steffey EM: Narcotic inhalation anesthesia (abstract). ANESTHESIOLOGY 57:A344, 1982.

this was unwise for it sent the wrong signal to some news media people and one health consumer group. Fortunately, we believe most anesthesiologists, surgeons, nursing personnel, patients, and patients’ families did not get the wrong signal.

Nonetheless, the fact that even a few individuals might believe that OTFC is a lollipop or candy rather than a potent opioid intended for patients under the care of anesthesiologists is a serious issue. I am also concerned that carefully thought-out clinical research studies at medical institutions throughout the United States designed to document the safety and efficacy of OTFC for patients prior to surgery may be erroneously characterized as casual or cute rather than as serious research.

Clearly, we must avoid falling into the same semantic traps our colleagues have in the past with useful devices such as MRI. Now is the time to correct our mistakes before additional studies of OTFC are completed and the inappropriate terminology becomes established. In this regard we have made a conscious decision to use the terms “OTFC” or “OTFC units,” where previously the word “lollipop” was used. Also, the terms “sweetened base” or “sweetened matrix” for “candy” is more appropriate terminology.

Should OTFC continue to prove to be safe, efficacious, and useful in the remaining on-going studies, an appropriate trade name will be carefully chosen before FDA approval to avoid public confusion and unnecessary alarm. Of course, we hope our semantic mistakes of the past do not necessitate a long or difficult re-education process in the future.

THEODORE H. STANLEY, M.D.
*Professor of Anesthesiology
The University of Utah School of Medicine
50 North Medical Drive
Salt Lake City, Utah 84132*

Anesthesiology
72:210-211, 1990

An Increase in Serum Creatine Kinase Concentration due to Variant Creatine Kinase during Preterm Labor

To the Editor:—We report a case in which serum creatine kinase (CK) was abnormally high with the appearance of variant CK, complicating the preoperative evaluation.

A 34-yr-old, 33 week pregnant woman, suffering from hydroamnios and fetal hydrops, was admitted because of impending premature labor. Administration of ritodrine, a β_2 adrenoceptor agonist, was started immediately. Three days after admission, serum examination revealed a serum CK concentration of 1124 IU/l (normal, less than 80). CK electrophoresis showed a broad CK-MM band and an abnormal band of variant CK between CK-MM and CK-MB, which we regarded as macro CK type 1 from its electrophoretic mobility (fig. 1).¹ Although

- #### REFERENCES
1. Meuleman T, Williard K, Port J, Stanley TH, Kimball J: Immobilization of elk and moose with carfentanil. *J Wildl Manag* 48:258-262, 1984
 2. Stanley TH, Leysen TE, Niemegeers CJ, Pace NL: Narcotic dosage and central nervous system opiate receptor binding. *Anesth Analg* 62:705-709, 1983
 3. Stanley TH, Hague BH, Mock DL, Streisand JB, Bubbers S, Dzelzkalns RR, Bailey PL, Pace NL, East KA, Ashburn MA: Oral transmucosal fentanyl citrate (lollipop) premedication in human volunteers. *Anesth Analg* 69:21-27, 1989

(Accepted for publication September 20, 1989.)

muscle disease or myocardial injury were suspected, there was no symptom, sign, or history of such a disorder. We continued to administer ritodrine and the serum CK concentration remained increased. Cesarean section was performed under general anesthesia 7 days after the admission. We did not use halothane or succinylcholine, and there was no problem in anesthetic management. Variant CK disappeared by the following day, and serum CK concentration became normal in 2 days.

Macro CK type 1 is a complex of CK and immunoglobulin, and appears or disappears for unknown reasons in a wide variety of disorders.¹ It has no diagnostic importance, but confusion with myocardial infarction has also been reported in cardiac patients.² Relevance between macro CK type 1 and malignant hyperthermia has also been recently suggested.⁵

The appearance of variant CK during pregnancy has not been reported. Either the hydroamnios or the use of ritodrine may have caused these abnormalities in serum CK. A few years ago, we experienced another case similar to the present one. That patient also suffered from hydroamnios and was given terbutaline, a β_2 stimulant. Fortunately, discontinuance of the drug decreased the CK concentration from 5000 IU/l to 81 IU/l in 10 days, following disappearance of variant CK.

Electrophoresis of CK revealed no increase in CK-MB and CK-BB, which suggested that the myocardium, myometrium, and brain were not injured. Although CK-MM seemed to be increased, its abnormally broad peak indicated distortion by the variant CK. In addition, there was no clinical evidence of muscle disease or myopathy. Thus, the increase in serum CK concentration was due to the appearance of variant CK.

Detailed examination may be necessary when an increased serum CK concentration and variant CK are found preoperatively, although it does not indicate MH susceptibility.

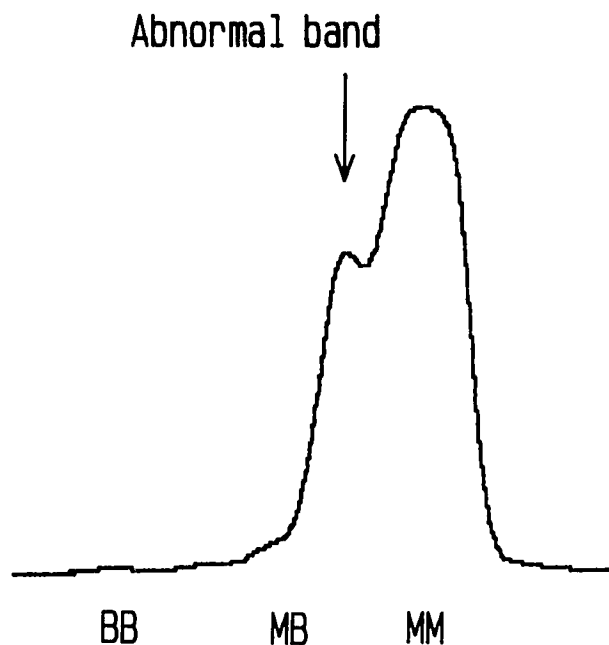


FIG. 1. Isoenzymatic pattern of CK of patient's serum after electrophoresis.

TOKUYA HARIOKA, M.D.
HIROSHI TODA, M.D.
TETSUHIRO SONE, M.D.
CHIYOMI MIYAKE, M.D.
*Department of Anesthesia
Shimada Municipal Hospital
Shimada, Shizuoka 427, Japan*