

matically improved once correct therapy for the dynamic outflow obstruction was instituted. Once the diagnosis is made the appropriate therapy consists of maintaining left ventricular volume by augmenting preload and afterload, and withdrawal of stimulation to contractility.^{7,8} The use of these measures in combination with esmolol to depress contractility corrected the dynamic LVOT obstruction and SAM but resulted in clinically significant right ventricular dysfunction. It was hoped that switching the phenylephrine infusion to the LA catheter would allow us to specifically target the α agonist on the systemic vasculature, with systemic clearance resulting in less drug presented to the pulmonary vascular bed, as has been demonstrated with LA norepinephrine.^{††} The return of the hemodynamic parameters to normal and the repeat echo provided us with confirmation of the efficacy of the treatment by demonstrating a decrease in LVOT gradient, decrease in SAM of the mitral valve, and reduced severity of mitral regurgitation. Although myomectomy at the time of aortic valve replacement has been advocated,⁹ in our case this would have necessitated re-replacement of the aortic prosthesis. The risk of myomectomy was felt to be unwarranted at that time, particularly in light of the response to medical management.

In conclusion, we stress that a high index of suspicion of dynamic LVOT obstruction is warranted when a patient with long-standing severe aortic stenosis has hemodynamic deterioration early after aortic valve replacement

and fails to improve or worsens with inotropic treatment. Echo cardiographic exam performed at the bedside, if the patient's condition allows it, or intraoperatively as in our case, will provide the diagnosis and guide appropriate therapy.

REFERENCES

1. Maron BJ, Gottdiener SS, Roberts WL, Hammer WJ, Epstein SE: Nongenetically transmitted disproportionate ventricular septal thickening associated with left ventricular outflow obstruction. *Br Heart J* 41:345-349, 1979
2. Harrison EE, Sbar SS, Martin H, Pupello DF: Coexisting right and left hypertrophic subvalvular stenosis and fixed left ventricular outflow obstruction due to aortic valve stenosis. *Am J Cardiol* 40:133-136, 1977
3. Stewart S, Nanda N, Dewese J: Simultaneous operative correction of aortic valve stenosis and idiopathic hypertrophic subaortic stenosis. *Circulation* 51-52(S):34-39, 1975
4. Parker DP, Kaplan MA, Connolly SE: Coexistent aortic valvular and functional hypertrophic subaortic stenosis. *Am J Cardiol* 24:307-317, 1969
5. Nanda NC, Gramiak R, Shah PM, Stewart J, DeWeese J: Echocardiography in the diagnosis of idiopathic hypertrophic subaortic stenosis co-existing with aortic valve disease. *Circulation* 50: 752-758, 1974
6. Oh JK, Taliencio CP, Holmes DR, Reeder GS, Bailey KR, Seward JB, Tajik AJ: Prediction of the severity of aortic stenosis by Doppler aortic valve area determination: Prospective Doppler-catheterization correlation in 100 patients. *J Am Coll Cardiol* 11(6):1227-1234, 1988
7. Thompson RC, Liberthson RR, Lowenstein E: Perioperative anesthetic risk of noncardiac surgery in hypertrophic obstructive cardiomyopathy. *JAMA* 254:2419-2421, 1985
8. Lanier W, Prough DS: Intraoperative diagnosis of hypertrophic obstructive cardiomyopathy. *ANESTHESIOLOGY* 60:61-63, 1984
9. Turina M: Asymmetric septal hypertrophy should be resected during aortic valve replacement. *Z Kardiol* 75, (S)2, 198-200, 1986

†† Coyle JP, Carlin HM, Lake CR, Lee CK, Chernow B: Left atrial infusion of norepinephrine in the management of right ventricular failure. *J Cardiothoracic Anesth*, 1990, (in press)

Anesthesiology
72:566-570, 1990

Prolonged Neuromuscular Blockade after Long-Term Administration of Vecuronium in Two Critically Ill Patients

VERONICA SEGREDO, M.D.,* MICHAEL A. MATTHAY, M.D.,† MANOHAR L. SHARMA, Ph.D.,‡ LARRY D. GRUENKE, Ph.D.,§ JAMES E. CALDWELL, F.F.A.R.C.S.,¶ RONALD D. MILLER, M.D.**

In some patients with severe respiratory failure, administration of neuromuscular blocking drugs may im-

prove gas exchange, probably by increasing chest wall compliance and improving ventilation/perfusion match-

* Research Fellow, Department of Anesthesia.

† Associate Professor, Departments of Medicine and Anesthesia.

‡ Associate Research Biochemist, Department of Anesthesia.

§ Assistant Research Chemist, Departments of Epidemiology & International Health, Pharmaceutical Chemistry, and Anesthesia.

¶ Assistant Clinical Professor, Department of Anesthesia.

** Professor and Chairman, Department of Anesthesia, Professor of Pharmacology.

Received from the Department of Anesthesia, University of Cali-

fornia San Francisco, San Francisco, California. Accepted for publication October 24, 1989. Supported in part by NIH grant ROI GM 26403.

Address reprint request to Dr. Miller: Department of Anesthesia, University of California, Box 0648, San Francisco, California 94143-0648.

Key words: Complications: prolonged neuromuscular blockade. Intensive Care. Monitoring: neuromuscular function. Neuromuscular relaxants: 3-desacetylvecuronium; vecuronium.

ing.¹ Although pancuronium is often given, it may cause tachycardia and is primarily dependent on the kidney for its elimination.² Consequently vecuronium is used in critically ill patients because it is not associated with hemodynamic side effects, has an intermediate duration of action, and is not primarily dependent on the kidney for its elimination.³

However, we observed two patients with impaired renal function who had persistent neuromuscular blockade from several hours to several days after a long-term administration of vecuronium had been terminated. In both patients vecuronium disappeared relatively quickly from plasma after its administration was discontinued, but its 3-desacetylmetabolite (3-desacetylvecuronium) remained in high concentrations. Both patients had kidney failure that required hemodialysis.

REPORT OF TWO CASES

Case 1. A 49-yr-old woman was admitted to the intensive care unit (ICU) for acute respiratory failure secondary to pneumocystis carinii pneumonia. During her hospitalization (for 28 days until her death), she had both renal and respiratory failure. Hepatic and cardiac function were normal. She had no history of neuromuscular disease.

In 1988 she had undergone a cadaver renal transplant after 6 yr of chronic hemodialysis for proliferative glomerulonephritis. Her immunosuppressive treatment (*i.e.*, azathioprine, cyclosporine A, and prednisone) was terminated on her current admission to the ICU. She received only prednisone (15 mg per day) plus hydrocortisone (200 mg per day) and subsequently rejected her transplanted kidney. Despite adequate urine output (>40 ml/h) she required chronic hemodialysis from the eighth day of hospitalization. Liver function remained relatively normal (table 1).

Mechanical ventilation for respiratory failure was begun on the second hospital day and the patient was treated with septria (12 days) and then pentamidine. Her course was complicated by barotrauma with pneumomediastinum and bilateral pneumothoraces. During most of her ICU stay, she needed high airway pressures to maintain adequate oxygenation and ventilation with an FI_{O_2} between 0.8 and 1.0, positive end-expiratory pressures (PEEP) of 10–15 cm H_2O , and peak inspiratory airway pressures of 50–70 cm H_2O . On her fourteenth hospital day, she required muscle paralysis to improve mechanical ventilation (despite sedation with midazolam and morphine). Pancuronium (total dose of 22 mg) was given on the 14th and 15th hospital days (*i.e.*, for the first 34 h of paralysis). Because of intermittent problems with tachycardia, vecuronium was started in the form of bolus injections on the 15th hospital day and continued for the following 6 days. The daily dose of vecuronium had to be progressively increased to obtain satisfactory paralysis (from 0.75 mg/h on the 15th hospital day to 8 mg/h on the 20th hospital day). Neuromuscular function was not monitored with a peripheral nerve stimulator. Adequate paralysis was defined as no spontaneous movement and/or no spontaneous respiratory efforts. The total dose given was 337 mg. Any spontaneous movement of the patient was the indication for giving additional vecuronium.

On the 20th hospital day, vecuronium was withheld because of the absence of any movement by the patient. From that time she remained completely motionless with flaccid paralysis, ophthalmoplegia, and areflexia. Pupillary reactions to light were normal. Percutaneous electric stimulation of the ulnar nerve at the wrist using a square-wave stimulus of 0.2-s duration delivered in a train-of-four (TOF) sequence at a frequency of 2 Hz with at least 48 mA showed no muscular response. Electromyography performed on the 28th hospital (8 days after vecuronium was terminated) revealed normal sensory nerve action potentials, but no muscle action potentials after stimulation of the right median and ulnar nerves and no motor response after repetitive stimulation of these nerves (50 Hz for 3 s). Spontaneous muscle activity (fibrillation and positive waves) was observed in at least two muscles of all four limbs. Neostigmine (3 mg plus 1.0 mg of atropine) was administered iv on the 23rd, 24th, and 26th hospital days (*i.e.*, three,

TABLE 1. Laboratory Values during Prolonged Paralysis*

	Patient 1	Patient 2
Duration of prolonged paralysis	7 days (died paralyzed)	40 h (recovered)
Liver function tests†		
Alanine aminotransferase (2–54 U/l)	44	28–49
Alkaline-phosphatase (41–133 U/l)	87–152	486–556
Glutanyl transpeptidase (6–58 U/l)		167
Serum glutamic oxalacetic transaminase (7–39 U/l)	59–72	209–322
Total bilirubin (0.1–1.2 mg/gl)	1.2–3.3	
Direct bilirubin (0.1–0.3 mg/gl)	2.1	8.4
Prothrombin time	Normal	Normal
Renal function tests		
Creatinine clearance (ml/min)	5	3.6
pH _a	7.16–7.45	7.37–7.50
Electrolytes		
Serum potassium (3.5–5 mEq/l)	2.6–3.5 days 1 and 2 3.5–5 days 3–7	3.6–6.6
Serum calcium total (8.5–10.5 mg/dl)	8.6–11.4	7.1–7.6
Serum calcium ionized (3.9–5.4 mg/dl)		4.2–4.6
Serum magnesium (1.6–2.7 mg/dl)	1.6–2.1	2.7–3.2

* These are the range of reported laboratory test values during the period of prolonged paralysis in both patients.

† Numbers in parenthesis represent normal values.

four, and six days after vecuronium discontinuation, respectively). Transient recovery of a single twitch with TOF stimulation of the ulnar nerve followed each administration, but after approximately 1 h, the twitch diminished, then disappeared.

During the week of paralysis following termination of vecuronium administration, the patient required hemodialysis on hospital days 21, 24, 25, 27, and she received the following medications: prednisone, hydrocortisone, pentamidine, tobramycin, erythromycin, ceftazidime, imipenem, amphotericin B, sucralfate, acetaminophen, diphenhydramine, morphine, and midazolam (fig. 1).

During the course of her prolonged paralysis, we intermittently measured plasma concentrations of vecuronium and its 3-desacetyl metabolite by a capillary gas chromatographic technique developed in our laboratory.⁴ The coefficient of variation is $\pm 11.0\%$ at 27 ng/ml and the sensitivity of 2 ng/ml. Three hours after vecuronium administration had been terminated, its plasma concentration was 685 ng/ml. By the fourth hour, the concentration had declined to 460 ng/ml, and after a 4-h hemodialysis course, to 225 ng/ml. Plasma vecuronium concentrations were undetectable 72 h after termination of vecuronium. 3-desacetylvecuronium concentration was 1739 ng/ml 3 h after discontinuation of vecuronium. This concentration declined quickly to 400 ng/ml 48 h after discontinuation of vecuronium and after a 4-h course of hemodialysis, but then remained constant for the remaining 5 days between 244 and 427 ng/ml despite three more courses of hemodialysis (fig. 1).

Case 2. A 35-yr-old female, with a past medical history of acute myelomonocytic leukemia diagnosed in 1988, was admitted to the ICU for treatment of adult respiratory distress syndrome requiring tracheal intubation and mechanical ventilation. Prior to her admission she had received cyclophosphamide as second stage consolidation therapy. Several days prior to admission, she developed progressive cholestatic jaundice despite discontinuation of rifampicin (table 1). On admission she was febrile and had pancytopenia. No pathogen was found and despite broad spectrum antibiotic, antiviral, and antifungal therapy she remained febrile and pancytopenic. She received bactrim (discon-

tinued on admission), amphotericin B, and amikacin (both discontinued on the fifth day in the ICU because of the progressive deterioration of renal function), vancomycin and imipenem (both discontinued on the fifth day in the ICU because of the extension of a toxic epidermal necrolytic rash), rifampicin (discontinued also on the fifth day in the ICU because of deterioration of liver function), ceftazidime (started on ICU day 4), ciprofloxacin (started on ICU day 5), acyclovir, and erythromycin.

Renal insufficiency developed progressively from ICU day 3 despite the discontinuation of amphotericin B and amikacin. She required almost daily hemodialysis from ICU day 7. On hospital day 6 she developed septic shock requiring high doses of dopamine (up to $16 \mu\text{g} \cdot \text{kg}^{-1} \cdot \text{min}^{-1}$) for 48 h to maintain hemodynamic stability.

Because of deteriorating pulmonary function and the need for increasing ventilatory support (PEEP up to 12 cm H₂O, FI_{O₂} up to 1) despite sedation with fentanyl, diphenhydramine, midazolam, and lorazepam she required muscle relaxation to facilitate mechanical ventilation. On the fifth hospital day, atracurium (total dose 75 mg) was given for the first 3 h of muscle relaxation. Vecuronium was arbitrarily chosen for subsequent paralysis. She subsequently received a total dose of 83 mg of vecuronium for the next 48 h.

After 48 h of repeated boluses of vecuronium, no further doses were given because no movement by the patient was observed. Because her paralysis seemed to last longer than usual, we were asked to assess the neuromuscular status of the patient. There was no response to TOF stimulation of the ulnar nerve at the wrist 17 h after the last dose of vecuronium. At this time plasma concentrations of vecuronium and 3-desacetylvecuronium were 81 and 586 ng/ml, respectively. Three of four twitch responses to TOF stimulation were observed at 24 h, at plasma vecuronium, and 3-desacetylvecuronium concentrations of 10 and 295 ng/ml, respectively. Recovery of four twitches at the TOF stimulation did not occur until 40 h at plasma concentrations of 21 and 259 ng/ml, respectively.

During the 40 h of prolonged neuromuscular blockade, the patient underwent two courses of hemodialysis lasting 2 and 3 h, respectively. Arterial blood pH varied from 7.4 to 7.5, due to a metabolic alkalosis caused by the acetate from the total parenteral nutrition. Her electrolyte concentrations during this period are shown in table 1. Also during this period she received vancomycin, ceftazidime, acyclovir, erythromycin, ciprofloxacin, bactrim, solumedrol, ranitidine, metoclopramide, prochlorperazine, dopamine, fentanyl, and diphenhydramine.

DISCUSSION

Persistent muscle paralysis in a critically ill patient may result from several factors. The EMG data obtained in the first patient after 6 days of unexplained paralysis were consistent with a motor neuropathy similar to Guillain Barré, a severe myonecrosis, or a neuromuscular blockade. Motor neuropathy is unlikely because of the observed transient muscle response obtained after electrical stimulation of the ulnar nerve following administration of neostigmine. Myonecrosis would have been implicated had the creatinine phosphokinase (CPK) plasma concentrations been greatly increased, but they were only 1.5 times the normal value. Therefore, paralysis in the first patient likely resulted from residual neuromuscular blockade after receiving vecuronium for 6 days.

In the critically ill patient, many possible coexistent factors may enhance neuromuscular blockade. For example, electrolyte disorders (*i.e.*, acidosis, hypocalcemia,

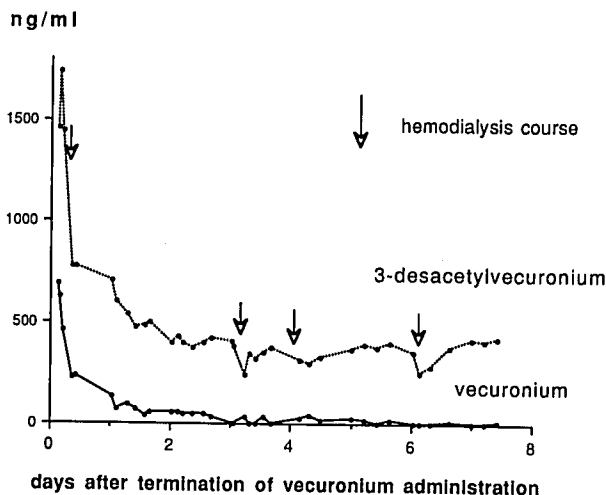


FIG. 1. Plasma concentration of vecuronium (—●—) and 3-desacetylvecuronium (···○···) in the first patient after vecuronium administration had been terminated. This patient also had four hemodialysis treatments as indicated by the arrows. The drugs listed below the figure are those the patient received and the time these drugs were given. Note that the concentration of 3-desacetylvecuronium never did decrease to less than that required for paralysis (*i.e.*, about <180 ng/ml).

hypokalemia, hypermagnesemia), can enhance a vecuronium-induced neuromuscular blockade.⁵⁻¹⁰ The first patient had a combined metabolic and respiratory acidosis. Her pH_a was between 7.3 and 7.4 for her entire ICU stay except the last 2 days during which pH_a was less than 7.3 along with hemodynamic instability. For 2 days after vecuronium was discontinued, she was hypokalemic (serum K^+ was 2.6–3.5 mEq/l) and acidotic (pH_a to 7.31) both of which could have enhanced neuromuscular blockade.¹⁰ However, this electrolyte abnormality occurred only during the first 2 days; thereafter, the serum potassium concentration was normal. The only electrolyte disorder likely to have enhanced neuromuscular blockade in the second patient was a slight hypermagnesemia (table 1). Certain drugs, especially antibiotics, also potentiate neuromuscular blockade induced by muscle relaxants.¹¹⁻¹⁵ Of these, only tobramycin was given to the first patient and none were given to the second patient. Tobramycin was started on the 13th hospital day and was given to the first patient until the day of her death. The antibiotic concentrations were in the therapeutic range.

Marshall *et al.*¹⁶ reported that 3-desacetylvecuronium is 70% as potent as vecuronium as a neuromuscular blocking drug in the cat. Bencini *et al.*¹⁷ suggested a 50% potency rate for both compounds in cats, but found that one dose of vecuronium and twice that dose of 3-desacetylvecuronium produced an 80 and 90% twitch depression, respectively. Their finding suggests that the potency of 3-desacetylvecuronium is about 50% that of vecuronium. Combined, these two studies suggest that 3-desacetylvecuronium is 50–70% of the potency of vecuronium in cats. Both studies also demonstrated consistent and equivalent time courses of neuromuscular blockade (*i.e.*, onset, duration of action, and recovery rate) for both vecuronium and its metabolite in the healthy cat. Although the cat generally is not a good predictive model for the duration of action of neuromuscular blocking drugs, relative potencies of muscle relaxant in cats are consistent with the corresponding relative potencies found in humans. This suggests that the 3-desacetylvecuronium should be only slightly less potent than vecuronium as a neuromuscular blocking agent in humans.

Therefore, to search for an explanation of the prolonged neuromuscular blockade, we measured plasma concentrations of both vecuronium and its putative metabolites during the duration of persistent paralysis following discontinuation of vecuronium. A sensitive and specific gas chromatographic assay providing for the simultaneous and selective measurements of vecuronium and its desacetylmetabolites (3-desacetylvecuronium, 17-desacetylvecuronium, 3,17-desacetylvecuronium) has been recently developed in our laboratory. This assay is sensitive to 5 ng/ml for vecuronium, 3, 17, and 3-17-desacetylvecuronium.⁴ Only vecuronium and 3-desace-

tylvecuronium were found in significant amounts in plasma. We did not detect significant amounts of 17- and 3,17-desacetylvecuronium in the patient's plasma.

Thus, the persistent high level of 3-desacetylvecuronium found in our patients seems to be the etiology of the observed prolonged neuromuscular blockades. The lowest metabolite concentration detected in the first patient (244 ng/ml) is pharmacologically equivalent to a vecuronium concentration of 195 ng/ml (assuming a 70% neuromuscular blocking potency ratio). For the second patient, 3-desacetylvecuronium concentration was 295 ng/ml when three twitches were found at the TOF stimulation of the ulnar nerve of the wrist, which is equivalent to a vecuronium concentration of 235 ng/ml. These concentrations of vecuronium are higher than the steady-state concentration required to produce 90% depression of twitch tension in healthy patients undergoing opioid/nitrous oxide anesthesia (165 ± 48 ng/ml).¹⁸

The persistence of 3-desacetylvecuronium in plasma in the first patient during the last 5 days suggests that 3-desacetylvecuronium elimination is highly dependent on renal function, given her very-low creatinine clearance and normal liver function tests (table 1). Castagnoli *et al.*¹⁹ have reported a very slow decline of 3-desacetylvecuronium plasma concentration in patients with renal failure who were given a single bolus of 100 mg/kg of vecuronium.

Hemodialysis was only partially effective in the removal of the metabolite. During the 7 days of prolonged paralysis in the first patient, we observed a reduction in 3-desacetylvecuronium plasma concentration after dialysis (table 2) (fig. 1) followed by an increase within a few hours to predialysis concentrations. This sequence suggests the existence of a storage compartment, which equilibrates slowly with a central compartment (plasma). The presence of such a compartment would explain the long-term ineffectiveness of hemodialysis in decreasing plasma metabolite levels, even when after each dialysis course 3-desacetylvecuronium's plasma concentration was reduced by approximately 70%. Furthermore, this compartment

TABLE 2. Plasma Concentrations of 3-Desacetylvecuronium in Patient 1 before and after Hemodialysis Course

Hemodialysis Course	Paralysis* Day	3-Desacetylvecuronium Concentration (ng/ml)		
		Before Dialysis	Immediately after Dialysis	Several Hours after Dialysis
1	1	1451	775	
2	4	381	244	373 (+10 h after dialysis)
3	5	†	315	
4	7	354	248	421 (+31 h after dialysis)

* Days following termination of vecuronium administration.
† No blood sample before dialysis.

suggests that prolonged paralysis may also occur in patients without complete renal failure.

In a study of hepatic excretion of vecuronium in the isolated perfused rat liver, Bencini *et al.* found that after portal injection of a single dose of vecuronium, 70% of the administered dose was excreted in the bile within 2 hours and 22% remained in the liver.²⁰ Of the vecuronium excreted into the bile, 57% was unchanged and 42% was present as 3-desacetylvecuronium. Studies in cats¹⁶ suggest that the liver is even more important for the clearance of 3-desacetylvecuronium than it is for the parent compound. Thus, liver uptake and biliary excretion of 3-desacetylvecuronium may be the primary route of excretion in cats. However, we found little evidence of clearance of 3-desacetylvecuronium from plasma in our first patient after the second day even though her liver function tests were normal.

In summary, many factors could have accounted for the prolonged neuromuscular blockade observed after termination of a long-term administration of vecuronium in these two patients. However, we believe the dominant cause is the accumulation of an active metabolite: the 3-desacetylvecuronium. This finding places additional emphasis on carefully monitoring neuromuscular function in critically ill patients with renal failure receiving vecuronium, because of the risk of accumulation of an active metabolite, 3-desacetylvecuronium.

The authors wish to thank Toni Magorian, M.D., for critically reviewing the manuscript, and Winifred von Ehrenburg for editorial assistance.

REFERENCES

1. Matthay MA, Hopewell PC: Critical care for acute respiratory failure, Textbook of Pulmonary Diseases, 4th edition. Edited by Braum G, Wolinsky E. In press, 1989
2. Buzello W, Agoston S: Pharmacokinetics of pancuronium in patients with normal and impaired renal function. *Anaesthesiol* 27:291-297, 1978
3. Miller RD, Savarese JJ: Pharmacology of muscle relaxants and their antagonists, *Anesthesia*, 2nd edition. Edited by Miller RD. New York, Churchill-Livingstone, 1985, pp 889-935
4. Furuta T, Canfell PC, Castagnoli KP, Sharma ML, Miller RD: Quantitation of pancuronium, 3-desacetylpancuronium, vecuronium, 3-desacetylvecuronium, pipecuronium, and 3-desacetylpipecuronium in biological fluids by capillary gas chromatography using nitrogen-sensitive detection. *J Chromatogr Sci* 427:41-53, 1988
5. Funk DI, Crul JF, Pol FM: Effects of changes in acid-base balance on neuromuscular blockade produced by ORG-NC 45. *Acta Anaesthesiol Scand* 24:119-124, 1980
6. Gencarelli PJ, Swen J, Koot HW, Miller RD: The effects of hypercarbia and hypocarbia on pancuronium and vecuronium neuromuscular blockades in anesthetized humans. *ANESTHESIOLOGY* 59:376-380, 1983
7. Ono K, Ohta Y, Morita K, Kosaka F: The influence of respiratory induced acid-base changes on the action of nondepolarizing muscle relaxants in rats. *ANESTHESIOLOGY* 68:357-362, 1988
8. Feldman S: Effects of changes in electrolytes, hydration, and pH upon the reactions to muscle relaxants. *Br J Anaesth* 35:546-555, 1963
9. Miller RD, Roderick LL: Diuretic-induced hypokalaemia, pancuronium neuromuscular blockade, and its antagonism by neostigmine. *Brit J Anaesth* 50:541-544, 1978
10. Lee C, Nguyen NB, Tran BK, Katz R: Quantification of magnesium-pancuronium interaction in the diaphragm and the tibialis anterior (abstract). *ANESTHESIOLOGY* 57:A392, 1989
11. Viby-Mogensen J: Interaction of other drugs with muscle relaxants, *Muscle Relaxants. Basic and Clinical aspects*. Edited by Katz RL. Orlando, FL, Grune & Stratton, Inc., pp 233-256, 1985
12. Koch-Weser J, Argov Z, Mastaglia FL: Disorders of neuromuscular transmission caused by drugs. *N Engl J Med* 301:409-413, 1979
13. Durant NN, Briscoe JR, Lee C, Katz RL: The acute effects of hydrocortisone on neuromuscular transmission (abstract). *ANESTHESIOLOGY* 57:A266, 1989
14. Singh YN, Marshall IG, Harvey AL: Pre and postjunctional blocking effects of aminoglycoside, polymyxin, tetracycline, and lincosamide antibiotics. *Br J Anaesth* 54:1295-1305, 1982
15. McIndewar IC, Marshall RJ: Interactions between the neuromuscular blocking drug ORG NC45 and some anesthetic, analgesic and antimicrobial agents. *Br J Anaesth* 53:785-791, 1981
16. Marshall IG, Gibb AJ, Durant NN: Neuromuscular and vagal blocking actions of pancuronium bromide, its metabolites, and vecuronium bromide (ORG NC45) and its potential metabolites in the anesthetized cat. *Br J Anaesth* 55:703-714, 1983
17. Bencini AF, Houwertjes MC, Agoston S: Effects of hepatic uptake of vecuronium bromide and its putative metabolites on their neuromuscular blocking actions in the cat. *Br J Anaesth* 57:789-795, 1985
18. Cannon J, Fahey M, Castagnoli K, Furuta T, Canfell C, Sharma M, Miller R: Continuous infusion of vecuronium: The effect of anesthetic agents. *ANESTHESIOLOGY* 67:503-506, 1987
19. Castagnoli KP, Caldwell JE, Canfell PC, Lynam DP, Arden JR, Miller RD: Does the independent measurement of 3-desacetyl vecuronium influence the pharmacokinetics of vecuronium? (abstract). *ANESTHESIOLOGY* 69:A479, 1988
20. Bencini AF, Mol WE, Scaf AH, Kersten UW, Wolters KT, Agoston S, Meijer DK: Uptake and excretion of vecuronium bromide and pancuronium bromide in the isolated perfused rat liver. *ANESTHESIOLOGY* 69:487-492, 1988