

## Percutaneous Extracorporeal CO<sub>2</sub> Removal in a Patient with Bullous Emphysema with Recurrent Bilateral Pneumothoraces and Respiratory Failure

ANTONIO PESENTI, M.D.,\* GIAN PIERA ROSSI, M.D.,† PAOLO PELOSI, M.D.,‡  
LUCA BRAZZI,§ LUCIANO GATTINONI, M.D.¶

Extracorporeal CO<sub>2</sub> removal has been, up to now, almost exclusively applied in patients with severe acute respiratory diseases.<sup>1,2</sup> As originally reported, the extracorporeal removal of the patient's entire CO<sub>2</sub> production allows decrease of the natural lung ventilation to close to apnea.<sup>3</sup> More recently, the concept of partial extracorporeal CO<sub>2</sub> removal<sup>4</sup> was introduced as a way of permitting the maintenance of otherwise inadequate spontaneous breathing in patients with less-severe respiratory insufficiency and/or respiratory failure of a different origin. In this case the extracorporeal membrane lung will need to remove only a portion of the CO<sub>2</sub> production. We believe that this approach, although still largely experimental, has been useful in solving the ventilatory problems of the patient who is the subject of this report.

### REPORT OF A CASE

A 19-yr-old woman was referred to our intensive care unit (ICU) from another hospital ICU. The admission diagnosis was bilateral bullous emphysema with recurrent pneumothoraces, bilateral air leaks, and pulmonary infection. The patient's lungs had been mechanically ventilated for 28 days, and various attempts to separate her from the ventilator had been unsuccessful. At the time of admission she was conscious, and her lungs were being mechanically ventilated at FI<sub>O<sub>2</sub></sub>: 0.4; TV: 400 ml; respiration: 20 breaths per min; PEEP: 0 cm H<sub>2</sub>O. Arterial pH was 7.331, PaO<sub>2</sub> 97 mmHg, and PaCO<sub>2</sub> 55 mmHg. Temperature was 37.9° C, heart rate 140, BP 90/45 mmHg, CVP 8 mmHg, PAP 48/14 (mean 29) mmHg, PAWP 12 mmHg, and cardiac output 6.5 l/min. WBC were 11000 mm<sup>3</sup>, PRCV 32%.

Five months before, the patient had been admitted to another hos-

pital because of a spontaneous right pneumothorax that was evacuated without complications. A diagnosis of congenital bullous emphysema was made. Recurrent spontaneous pneumothoraces led to a left subtotal and right subtotal pleurectomies, respectively, 50 and 30 days before admission to our institution. Four days following the right pleurectomy, respiratory insufficiency developed, the patient was transferred to the ICU, and mechanical ventilation was instituted.

At this time bilateral air leaks were present. Pneumomediastinum and subcutaneous emphysema appeared. A chest CT scan (fig. 1 a and b) revealed the presence of hyperinflated multiple bullae of various sizes, occupying bilaterally most of the pleural cavity. Bronchial cultures were positive for *Pseudomonas aeruginosa* and a Candida urinary infection was demonstrated. The patient was moderately febrile (<39° C) and appropriate antibacterial treatment was instituted. Recurrent pneumothoraces required various repositioning of the thoracostomy tubes. Several attempts to reduce the mechanical ventilatory support and the airways pressure were unsuccessful. The 28th day of her stay in the ICU, controlled mechanical ventilation was being maintained with FI<sub>O<sub>2</sub></sub>: 0.4, respiration: 20 breaths per min, TV: 450 ml, PEEP 0 cm H<sub>2</sub>O. PaO<sub>2</sub> was 68 mmHg, PaCO<sub>2</sub> 48 mmHg, and pH 7.39.

The patient was transferred to our institution. We decided that the best therapeutic strategy, to reduce the risk of new pneumothoraces and to stop the air leak, would be to dispense with mechanical ventilation or any form of positive airway pressure. Spontaneous breathing could be maintained by supplementing the spontaneous CO<sub>2</sub> clearance with partial extracorporeal CO<sub>2</sub> removal.

### CANNULATION AND EXTRACORPOREAL CIRCUIT

Specially designed 12-F percutaneous catheters were positioned under local anesthesia by a modified Seldinger technique. We chose thin-walled spring wire reinforced polyurethane catheters to increase blood flow and avoid kinking due to patient's movements.

Blood was drained from the right internal jugular vein to a 150 ml collapsible silicon rubber reservoir (SCI MED Life System, Minneapolis, Minnesota), pumped through a 2.5-m<sup>2</sup> Sci Med Kolobow membrane lung, and returned to the right femoral vein. We ventilated the membrane lung with a humidified gas mixture, adjusting its flow (range 8-14 l/min) to achieve the desired extracorporeal CO<sub>2</sub> removal. The extracorporeal system was provided by Kontron (Milan, Italy). Blood was pumped at a rate between 0.4-0.6 l/min: extracorporeal CO<sub>2</sub> removal (as measured by the difference in CO<sub>2</sub> content of the blood before and after the membrane lung) ranged between 33.2-71.5 ml/min. Representative CO<sub>2</sub> removal values during the procedure varied from 22-40% of the patient's CO<sub>2</sub> production.

\* Research Fellow, University of Milan.

† Senior Staff, Department of Anesthesiology and Intensive Care, Ospedale di Monza.

‡ Research Fellow in Anesthesia, IRCCS Policlinico, Milano.

§ Medical Student, University of Milan.

¶ Associate Professor of Intensive Care, University of Milan; Chairman, Department of Anesthesia and Intensive Care, Ospedale di Monza.

Received from the Institute of Anesthesia and Intensive Care, University of Milan; and the Intensive Care Unit Ospedale Maggiore Policlinico, Milan, Italy. Accepted for publication October 25, 1989. Supported in part by CNR grant 87.00750.57 and CT IRCCS grant 186 cod. 533/03.

Address reprint requests to Dr Pesenti: I Servizio di Anestesia e Rianimazione, Ospedale S. Gerardo, Via Donizetti 20052 Monza (MI), Italy.

Key words: Extracorporeal circulation; carbon dioxide removal; respiratory support. Lung: respiratory failure.

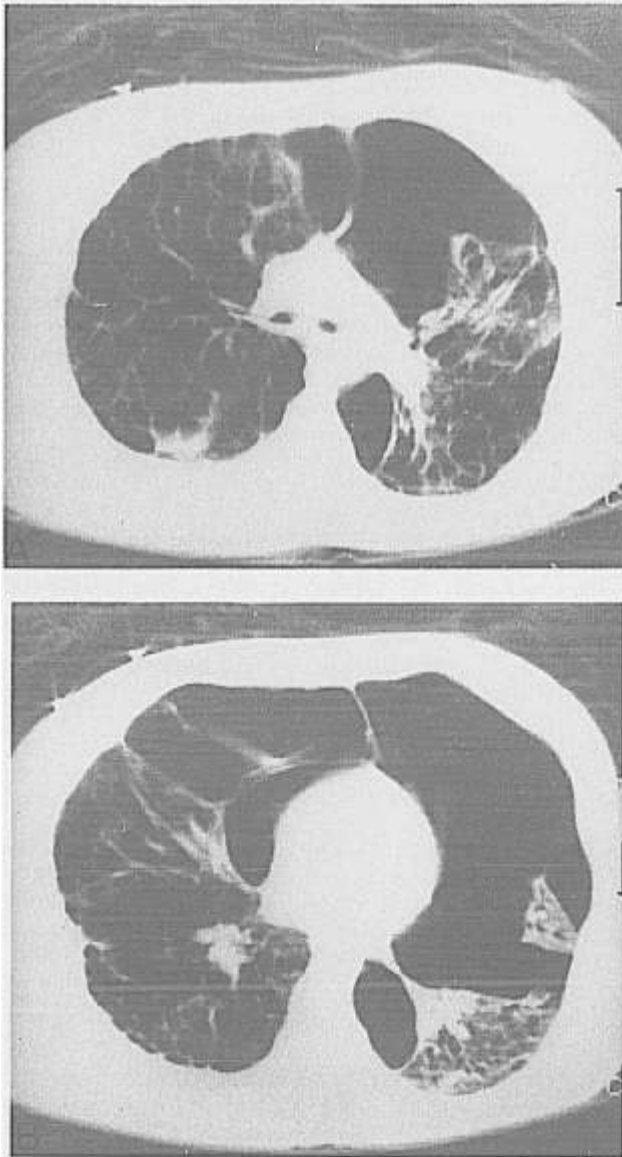


FIG. 1. Chest CT scan taken before connection to bypass (at PEEP 0 cm H<sub>2</sub>O). Presence of bilateral pneumothoraces and hyperinflation of the bullae, hilum (A), and base (B).

Heparin was continuously infused to achieve activated clotting times 80–120% greater than normal. There was an absence of bleeding except for some blood in the tracheal aspirate. The amount of blood transfused during the entire procedure (7 days) was 3.6 l (including the blood transfused to substitute for blood samples: ~300 ml/day).

During the first 24 h of bypass, ventilatory assistance was changed from pressure support to continuous positive airway pressure (CPAP), after which she breathed through a T tube. The time course of selected parameters during the procedure is summarized in figure 2.

By the end of the fourth day of bypass, the air leaks

had both stopped. On the fifth day, because some clots had appeared on the upper side of the membrane lung, we substituted a smaller size (1.5 m<sup>2</sup>) tube. The patient was separated from the extracorporeal circuit on the eighth day. From then on the patient alternated between periods of CPAP (3 cm H<sub>2</sub>O) and pressure support (+10 to +15 cm H<sub>2</sub>O), progressively increasing the time spent with CPAP.

The patient was then separated from any form of respiratory support and finally discharged home 7 weeks after separation from bypass. A chest CT scan, taken 2 months after discharge from the hospital, showed an obvious decrease in the size of the bullae, with good expansion of the residual parenchyma.

### DISCUSSION

We describe here the clinical use of partial extracorporeal CO<sub>2</sub> removal for the management of ventilatory insufficiency. The invasiveness of this simplified technique is similar to continuous arteriovenous hemofiltration or continuous hemodialysis.

Long-term extracorporeal respiratory assistance with a membrane lung<sup>2,5,6</sup> has been, up to now, almost exclusively applied as a last-resort life-support technique in the terminally ill. In these patients a device able to provide total gas exchange is needed,<sup>7</sup> and requires the surgical cannulation of major veins and/or arteries with large-bore cannulas, to achieve blood flows of at least 2 l/min. Thus, the likelihood of side effects has severely limited the clinical use of the technique.

The patient we report here was not yet in a moribund state. However, 28 days of conventional treatment had clearly shown that the very fragile lung parenchyma could not withstand positive pressure ventilation and that progressive barotrauma and deterioration of gas exchange

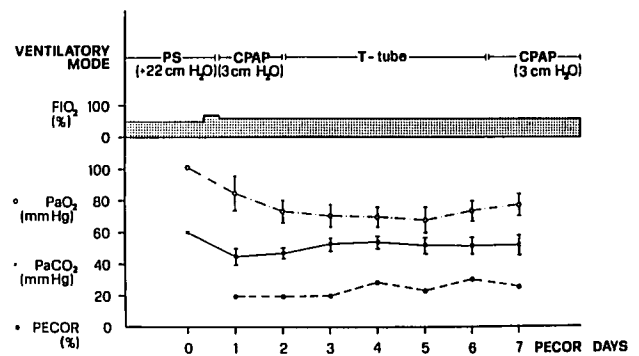


FIG. 2. Time course of relevant parameters during bypass: PS = pressure support; CPAP = continuous airway pressure breathing; FiO<sub>2</sub> = inspired oxygen fraction; PaO<sub>2</sub> = arterial oxygen pressure; PaCO<sub>2</sub> = arterial CO<sub>2</sub> tension; PECOR = partial extracorporeal CO<sub>2</sub> removal (% of the metabolic production rate).

would occur. We considered the possible application of high frequency ventilation as a mean to manage this patient. This technique,<sup>8</sup> however, is best indicated in cases of unilateral lung diseases.<sup>9</sup> When the lung disease is bilateral, the maintenance of gas exchange requires mean airway pressures comparable to those provided during conventional ventilation, while leak flow may even increase.<sup>10</sup>

Indeed, the ideal ventilatory management of such a case would be the one that could permit spontaneous breathing at atmospheric pressure while maintaining satisfactory blood gases. Spontaneous breathing, made possible in this patient by partial extracorporeal CO<sub>2</sub> removal, prevented new pneumothoraces and stopped the air leak: the required blood flow was in the range attainable by small-bore percutaneous cannulae.

In conclusion we felt that in this particular patient partial extracorporeal CO<sub>2</sub> approach was justified as one that could reasonably offer the best risk/benefit ratio. A low-flow CO<sub>2</sub> removal system was applied as the possible solution to solve a specific ventilatory problem since conventional mechanical ventilation appeared contraindicated. Further investigation and development are required, as to allow a broader application of the principle illustrated here.

The authors wish to thank Sergio Vesconi M.D., Ospedale S. Paolo, Milan, and Pier Giuseppe Sironi M.D., Ospedale Fatebenefratelli, Oltalmico, Milan.

#### REFERENCES

1. Gattinoni L, Kolobow T, Agostoni A, Damia G, Pelizzola A, Rossi GP, Langer M, Solca M, Citterio R, Pesenti A, Fox U, Uziel L:

- Clinical application of low frequency positive pressure ventilation with extracorporeal CO<sub>2</sub> removal (LFPPV-ECCO<sub>2</sub>R) in the treatment of adult respiratory distress syndrome (ARDS). *Int J Artif Organs* 2:282-283, 1979
2. Gattinoni L, Pesenti A, Mascheroni D, Marcolin R, Fumagalli R, Rossi F, Iapichino G, Romagnoli G, Uziel L, Agostoni A, Kolobow T, Damia G: Low frequency positive pressure ventilation with extracorporeal CO<sub>2</sub> removal in severe acute respiratory failure. *JAMA* 256:881-886, 1986
3. Gattinoni L, Pesenti A, Kolobow T, Damia G: A new look at therapy of the adult respiratory distress syndrome: Motionless lung. *Int Anesthesiol Clin* 21:97-117, 1983
4. Marcolin R, Mascheroni D, Pesenti A, Bombino M, Gattinoni L: Ventilatory impact of partial extracorporeal CO<sub>2</sub> removal (PE-COR) in ARF patients. *Trans Am Soc Artif Intern Organs* 32: 508-510, 1986
5. Zapol WM, Snider MT, Hill JD, Fallat RJ, Bartlett RH, Edmunds LH, Morris AH, Peirce EC, Thomas AN, Proctor HJ, Drinker PA, Drinker PA, Pratt PC, Bagniewski A, Miller RG: Extracorporeal Membrane oxygenation in severe acute respiratory failure. A randomized prospective study. *JAMA* 242:2193-2196, 1979
6. Knoch M, Muller EE, Holtermann W, Konder H, Lennartz H: Erfahrungen mit der extrakorporalen CO<sub>2</sub>-elimination. *Anaesthesist* 36:210-216, 1987
7. Pesenti A, Pelizzola A, Mascheroni D, Uziel L, Pirovano E, Fox U, Gattinoni L, Kolobow T: Low frequency positive pressure ventilation with extracorporeal CO<sub>2</sub> removal in acute respiratory failure (ARF): Technique. *Trans Am Soc Artif Intern Organs* 27:263-266, 1981
8. Carlon GC, Ray C, Klain M, Mc Cormack PM: High frequency positive pressure ventilation in management of a patient with bronchopleural fistula. *ANESTHESIOLOGY* 52:160-162, 1980
9. Feeley TW, Keating D, Nishimura T: Independent lung ventilation using high frequency ventilation in the management of a bronchopleural fistula. *ANESTHESIOLOGY* 69:420-422, 1988
10. Bishop MJ, Benson MS, Sato P, Pierson DJ: Comparison of high frequency jet ventilation with conventional mechanical ventilation for bronchopleural fistula. *Anesth Analg* 66:833-838, 1987

Anesthesiology  
72:573-575, 1990

## Caudal Anesthesia and Intravenous Sedation for Repair of Giant Bilateral Inguinal Hernias in a Ventilator-Dependent Premature Infant

JOSEPH R. FURMAN, M.D.,\* MELVIN D. SMITH, M.D.†

Preterm infants who develop respiratory distress syndrome with respiratory failure require positive pressure mechanical ventilation for survival, and may develop severe barotrauma as a complication. Pulmonary interstitial emphysema, pneumatoceles, and pneumothoraces occur most often in infants who require high peak and mean

airway pressures as well as high inspired oxygen concentrations to achieve adequate gas exchange. The reported incidence of barotrauma in these patients varies from 9-40%, with the highest incidence occurring in infants under 1500 g.<sup>1</sup> When such patients present with an urgent problem requiring operative intervention, their anesthetic

\* Clinical Assistant Professor of Anesthesiology.

† Clinical Associate Professor of Surgery.

Received from the University of Texas Health Science Center at San Antonio, Santa Rosa Children's Hospital, San Antonio, Texas.

Accepted for publication October 26, 1989.

Address reprint requests to Dr. Furman: 2829 Babcock Road, Suite 345, San Antonio, Texas 78229.

Key words: Anesthesia: pediatric. Anesthetic techniques: caudal.