

would occur. We considered the possible application of high frequency ventilation as a mean to manage this patient. This technique,<sup>8</sup> however, is best indicated in cases of unilateral lung diseases.<sup>9</sup> When the lung disease is bilateral, the maintenance of gas exchange requires mean airway pressures comparable to those provided during conventional ventilation, while leak flow may even increase.<sup>10</sup>

Indeed, the ideal ventilatory management of such a case would be the one that could permit spontaneous breathing at atmospheric pressure while maintaining satisfactory blood gases. Spontaneous breathing, made possible in this patient by partial extracorporeal CO<sub>2</sub> removal, prevented new pneumothoraces and stopped the air leak: the required blood flow was in the range attainable by small-bore percutaneous cannulae.

In conclusion we felt that in this particular patient partial extracorporeal CO<sub>2</sub> approach was justified as one that could reasonably offer the best risk/benefit ratio. A low-flow CO<sub>2</sub> removal system was applied as the possible solution to solve a specific ventilatory problem since conventional mechanical ventilation appeared contraindicated. Further investigation and development are required, as to allow a broader application of the principle illustrated here.

The authors wish to thank Sergio Vesconi M.D., Ospedale S. Paolo, Milan, and Pier Giuseppe Sironi M.D., Ospedale Fatebenefratelli, Oftalmico, Milan.

#### REFERENCES

1. Gattinoni L, Kolobow T, Agostoni A, Damia G, Pelizzola A, Rossi GP, Langer M, Solca M, Citterio R, Pesenti A, Fox U, Uziel L:

- Clinical application of low frequency positive pressure ventilation with extracorporeal CO<sub>2</sub> removal (LFPPV-ECCO<sub>2</sub>R) in the treatment of adult respiratory distress syndrome (ARDS). *Int J Artif Organs* 2:282-283, 1979
2. Gattinoni L, Pesenti A, Mascheroni D, Marcolin R, Fumagalli R, Rossi F, Iapichino G, Romagnoli G, Uziel L, Agostoni A, Kolobow T, Damia G: Low frequency positive pressure ventilation with extracorporeal CO<sub>2</sub> removal in severe acute respiratory failure. *JAMA* 256:881-886, 1986
3. Gattinoni L, Pesenti A, Kolobow T, Damia G: A new look at therapy of the adult respiratory distress syndrome: Motionless lung. *Int Anesthesiol Clin* 21:97-117, 1983
4. Marcolin R, Mascheroni D, Pesenti A, Bombino M, Gattinoni L: Ventilatory impact of partial extracorporeal CO<sub>2</sub> removal (PE-COR) in ARF patients. *Trans Am Soc Artif Intern Organs* 32: 508-510, 1986
5. Zapol WM, Snider MT, Hill JD, Fallat RJ, Bartlett RH, Edmunds LH, Morris AH, Peirce EC, Thomas AN, Proctor HJ, Drinker PA, Drinker PA, Pratt PC, Bagniewski A, Miller RG: Extracorporeal Membrane oxygenation in severe acute respiratory failure. A randomized prospective study. *JAMA* 242:2193-2196, 1979
6. Knoch M, Muller EE, Holtermann W, Konder H, Lennartz H: Erfahrungen mit der extrakorporalen CO<sub>2</sub>-elimination. *Anaesthesist* 36:210-216, 1987
7. Pesenti A, Pelizzola A, Mascheroni D, Uziel L, Pirovano E, Fox U, Gattinoni L, Kolobow T: Low frequency positive pressure ventilation with extracorporeal CO<sub>2</sub> removal in acute respiratory failure (ARF): Technique. *Trans Am Soc Artif Intern Organs* 27:263-266, 1981
8. Carlon GC, Ray C, Klain M, Mc Cormack PM: High frequency positive pressure ventilation in management of a patient with bronchopleural fistula. *ANESTHESIOLOGY* 52:160-162, 1980
9. Feeley TW, Keating D, Nishimura T: Independent lung ventilation using high frequency ventilation in the management of a bronchopleural fistula. *ANESTHESIOLOGY* 69:420-422, 1988
10. Bishop MJ, Benson MS, Sato P, Pierson DJ: Comparison of high frequency jet ventilation with conventional mechanical ventilation for bronchopleural fistula. *Anesth Analg* 66:833-838, 1987

Anesthesiology  
72:573-575, 1990

## Caudal Anesthesia and Intravenous Sedation for Repair of Giant Bilateral Inguinal Hernias in a Ventilator-Dependent Premature Infant

JOSEPH R. FURMAN, M.D.,\* MELVIN D. SMITH, M.D.†

Preterm infants who develop respiratory distress syndrome with respiratory failure require positive pressure mechanical ventilation for survival, and may develop severe barotrauma as a complication. Pulmonary interstitial emphysema, pneumatoceles, and pneumothoraces occur most often in infants who require high peak and mean

airway pressures as well as high inspired oxygen concentrations to achieve adequate gas exchange. The reported incidence of barotrauma in these patients varies from 9-40%, with the highest incidence occurring in infants under 1500 g.<sup>1</sup> When such patients present with an urgent problem requiring operative intervention, their anesthetic

\* Clinical Assistant Professor of Anesthesiology.

† Clinical Associate Professor of Surgery.

Received from the University of Texas Health Science Center at San Antonio, Santa Rosa Children's Hospital, San Antonio, Texas.

Accepted for publication October 26, 1989.

Address reprint requests to Dr. Furman: 2829 Babcock Road, Suite 345, San Antonio, Texas 78229.

Key words: Anesthesia: pediatric. Anesthetic techniques: caudal.

management should be based on a technique that does not aggravate their underlying lung disease. The authors report here an experience with a 7-week-old preterm (gestational age 32 weeks) infant with chronic respiratory failure requiring mechanical ventilation of the lungs. This infant suffered severe pulmonary interstitial emphysema as a consequence of his original disease and its treatment, and subsequently developed bilateral inguinal hernias. The authors conducted the anesthetic for repair of the hernias with regional anesthesia and iv sedation.

### CASE REPORT

A preterm infant (gestational age 25 weeks, birth weight 840 g) presented at a postnatal age of 7 weeks for urgent repair of giant bilateral inguinal hernias. The neonatal course was complicated by severe infant respiratory distress syndrome (IRDS) and pulmonary interstitial emphysema. Although he was free of pneumothoraces at the time of his preoperative evaluation, he had required insertion of 13 chest tubes over the 7 weeks of life.

Physical examination showed a 1400-g infant whose trachea was orally intubated. He was in no apparent distress if left undisturbed, but he became easily agitated when examined. Vital signs were heart rate of 157 beats per min, blood pressure of 63/35 mmHg, and respiratory rate of 52 breaths per minute. Breath sounds were diminished bilaterally. Cardiac examination was normal. Abdominal examination was remarkable for the presence of giant unreducible bilateral inguinal hernias.

Respirations were being assisted with an infant pressure-cycled ventilator set at 19/4 cm H<sub>2</sub>O (pressure), 36 breaths per min (rate), and FI<sub>O<sub>2</sub></sub> of 0.35. Arterialized capillary blood gases showed a pH of 7.42, P<sub>CO<sub>2</sub></sub> of 50 mmHg P<sub>O<sub>2</sub></sub> of 41 mmHg, and base excess of +7.2 meq/l. His transcutaneous P<sub>O<sub>2</sub></sub> varied from 38 mmHg when he was agitated to 54 mmHg at rest. His transcutaneous P<sub>CO<sub>2</sub></sub> varied from 88 mmHg when he was agitated to 48 mmHg at rest. The chest radiograph showed severe bilateral pulmonary interstitial emphysema.

Additional laboratory data including hemoglobin, electrolytes, and

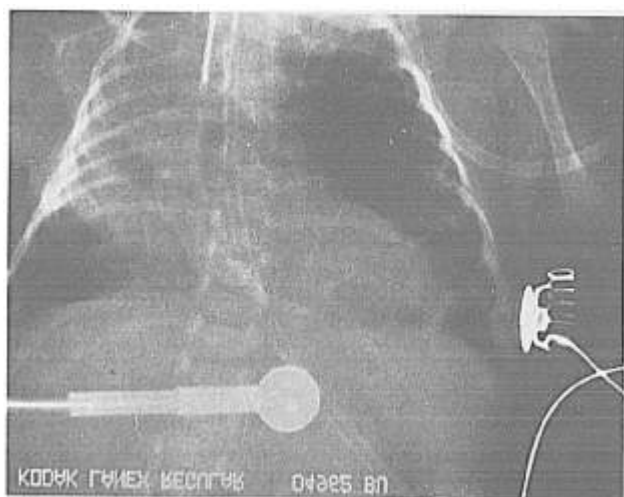


FIG. 1. Patient's preoperative chest radiograph demonstrating severe bilateral pulmonary interstitial emphysema. The hyperaerated left lung extends across the midline into the right chest. An endotracheal tube is in place, as is an orogastric tube.

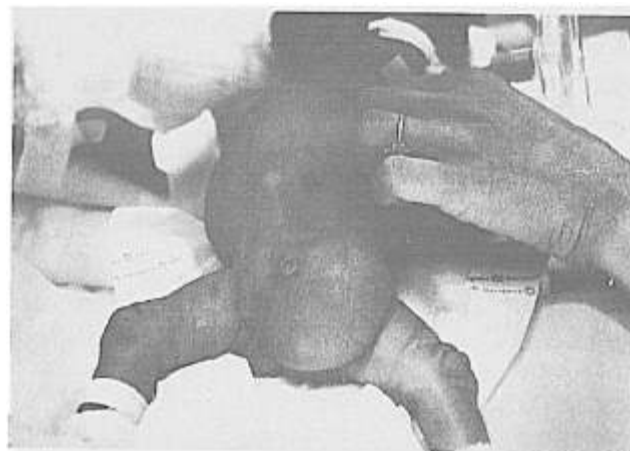


FIG. 2. Giant nonreducible bilateral inguinal hernias in this patient requiring urgent repair.

calcium were normal. Medications included aminophylline, furosemide, and dexamethasone. The patient received fentanyl 3  $\mu$ g and diazepam 0.5 mg every 4–6 h as needed for control of agitation.

Prior to transport from the neonatal intensive care unit, the patient was sedated with 5 mg of ketamine and 0.2 mg of midazolam intravenously. During transport, respirations were assisted manually with 100% oxygen through a Jackson-Rees modification of the Ayre's T piece connected to a manometer. Monitors consisted of an ECG and precordial stethoscope.

In the operating room, assisted ventilation was resumed with the infant pressure cycled ventilator using the preoperative settings. Monitors included an ECG, precordial stethoscope, Dinamap<sup>®</sup> oscillometric blood pressure monitor, and a pulse oximeter. The initial pulse oximeter reading (Sp<sub>O<sub>2</sub></sub>) was 92% saturation.

A caudal block was performed with the patient in the right lateral decubitus position. The presacral area was cleaned and draped in a sterile fashion. A 20-G needle was used to perforate the skin, and a 24-G Angiocath<sup>®</sup> was advanced through the sacrococcygeal ligament and threaded into the caudal canal. No blood or CSF was aspirated from the catheter.

Because surgical repair of giant inguinal hernias entails extensive peritoneal traction, a total dose of 1.5 ml 0.25% bupivacaine containing epinephrine 5  $\mu$ g/ml was used according to the formula of Takasaki *et al.* to produce a block to the level of T<sub>4</sub> (0.056 ml  $\times$  1.4 kg  $\times$  19 spinal segments).<sup>2</sup> The total dose was administered over 2 min in increments of 0.2–0.3 ml. As each incremental dose was given, the heart rate was carefully monitored. There was minimal variation in the baseline heart rate, suggesting that the injection was not intravascular. The absence of resistance to injection also suggested proper catheter placement. A length of microbore tubing was filled with the same local anesthetic solution and connected to the caudal catheter. The catheter was secured and the patient was positioned for surgery. To further prevent agitation (and therefore hypoxemia) in response to peritoneal traction, an additional 5 mg of ketamine was infused intravenously prior to the incision.

The left hernia was repaired first and required 2 h for completion. Surgical anesthesia was excellent with good relaxation and no bowel extrusion. After the hernia sac was removed, the remaining defect had to be closed with Dexon mesh. The patient exhibited some movement just as the skin closure on the left side was completed. The caudal catheter was carefully reinjected with 1.5 ml 0.25% bupivacaine containing epinephrine 5  $\mu$ g/ml. The total dose was again administered in increments of 0.3 ml and there was minimal variation in the heart

rate during reinjection. An additional 5 mg of iv ketamine and 0.2 mg of iv midazolam were infused prior to the second incision. The right herniorrhaphy took 1 h and proceeded uneventfully.

On termination of the procedure, the patient was transported to the neonatal intensive care unit. Postoperatively his condition has been stable without any deterioration in his respiratory status.

#### DISCUSSION

By using caudal anesthesia and iv sedation for this patient, we were able to continue ventilating his lungs in the operating room exactly as had been the case in the neonatal intensive care unit. We considered using subarachnoid block with tetracaine containing epinephrine as has been described by Abajian *et al.*<sup>3</sup> However, in this age group, the maximum duration of surgical anesthesia has been found to be only 2 h with this technique.<sup>3</sup> There is no practical method of re-establishing the block once it has worn off, and general anesthesia may be required to complete the case.

There is a lack of data in the literature concerning appropriate doses of local anesthetics for caudal block in patients under 1500 g. Also, the issue of local anesthetic toxicity has not been addressed in this group of patients. Although we based the volume of our dose of local anesthetic on the formula of Takasaki *et al.*,<sup>2</sup> we recognize that that study did not include any low birth weight premature infants. We suggest the need for further studies of caudal anesthesia in this group of patients. We also

stress the importance of slow incremental injections of the total dose of local anesthetic and of the addition of epinephrine 5 µg/ml to the solution to rule out accidental intravascular injection.

In summary, with caudal anesthesia and iv sedation, we avoided the use of halogenated agents with their attendant cardiovascular depression and impairment of spontaneous ventilation.<sup>4</sup> Avoiding halogenated agents, high-dose opioids and muscle relaxants prevented the need for controlled ventilation intraoperatively and allowed rapid resumption of preoperative respiratory management in the postoperative period. No increases in mechanical ventilation were necessary and the patient was therefore not put at increased risk for another pneumothorax.

#### REFERENCES

1. Madansky DL, Lawson EE, Chernick V, Taeusch HW, Jr: Pneumothorax and other forms of pulmonary air leak in newborns. *Am Rev Respir Dis* 120:729-737, 1979
2. Takasaki M, Dohi S, Kawabata Y, Takahashi T: Dosage of lidocaine for caudal anesthesia in infants and children. *ANESTHESIOLOGY* 47:527-529, 1977
3. Abajian JC, Mellish RWP, Browne AF, Perkins FM, Lambert DH, Mazuzan JE, Jr: Spinal anesthesia for surgery in the high-risk infant. *Anesth Analg* 63:359-362, 1984
4. Gregory GA: Anesthesia for premature infants, *Pediatric Anesthesia*. Edited by Gregory GA. New York, Churchill Livingstone, 1983, pp 579-606