

A Comparison Between Bupivacaine Instillation Versus Ilioinguinal/Iliohypogastric Nerve Block for Postoperative Analgesia Following Inguinal Herniorrhaphy in Children

William F. Casey, M.B., F.F.A.R.C.S.I.,* Linda Jo Rice, M.D.,* Raafat S. Hannallah, M.D.,†
Lynn Broadman, M.D.,‡ Janet M. Norden, R.N., M.S.,§ Philip Guzzetta, M.D.¶

This study compared the postoperative pain relief provided by simple instillation of bupivacaine into a hernia wound with that provided by ilioinguinal/iliohypogastric (IG/IH) nerve block. Sixty children undergoing inguinal hernia repair under general anesthesia were randomized to receive 0.25 ml/kg of 0.25% bupivacaine for either IG/IH nerve block or up to 0.5 ml/kg of the same solution for instillation nerve blocks. In the postanesthesia care unit (PACU), a trained blinded observer evaluated the patient's level of postoperative pain using a standardized 10-point objective pain scale. Fentanyl 1–2 µg/kg was administered intravenously to any child scoring 6 or more points on the pain scale. The difference in pain scores among the two groups were compared. The two groups were not significantly different in age, duration of surgery, or anesthesia. There was no significant difference between patients who received the two treatment modalities in their pain scores, analgesic requirements in the PACU, recovery times, and discharge times. These results demonstrate that the simple instillation of local anesthetics into a wound provides postoperative pain relief following hernia repair, which is as effective as that provided by intraoperative IG/IH nerve block. (Key words: Anesthesia; pediatric. Anesthetics, local; bupivacaine. Pain, postoperative. Surgery; inguinal herniorrhaphy.)

INGUINAL HERNIA REPAIR is frequently performed in pediatric outpatients. Postoperative pain may delay the return to a normal level of activity and thus delay discharge.

Various regional anesthetic techniques have been employed to provide postoperative analgesia in children following inguinal hernia repair.^{1–4} Recent studies suggest that the instillation of local anesthetic solution into the wound at the time of operation can produce profound postoperative analgesia.^{5–8} This study compared the postoperative pain relief produced by instillation of bupivacaine into the wound at the completion of the operation with that produced by an ilioinguinal/iliohypogastric (IG/IH) nerve block.

* Assistant Professor of Anesthesia and Pediatrics.

† Professor of Anesthesia and Pediatrics.

‡ Associate Professor of Anesthesia and Pediatrics.

§ Research Associate.

¶ Assistant Professor of Surgery and Pediatrics.

Received from the Departments of Anesthesiology, Pediatrics, and Surgery, Children's National Medical Center and George Washington University, Washington, DC. Accepted for publication December 7, 1989. Presented in part at the Annual Meeting of the American Society of Anesthesiologists, New Orleans, Louisiana, October 1989.

Address reprint requests to William F. Casey, M.B.: Department of Anesthesiology, 111 Michigan Avenue, NW, Washington, DC 20010.

Materials and Methods

Sixty ASA Physical Status 1 or 2 children (ages 2–10 yr) undergoing inguinal hernia repair on an ambulatory basis served as subjects in this single-blind study. The study was approved by the hospital Institutional Review Committee and written informed parental consent was obtained in every case. None of the children received pre-anesthetic medication. Anesthesia was induced and maintained with 70% nitrous oxide, 30% oxygen, and halothane administered *via* a face mask and a circle breathing system in all patients. The inspired concentration of halothane was adjusted to maintain systolic blood pressure within 20% of baseline value. No intraoperative sedatives or opioids were administered. Following ligation of hernia sac, patients were randomized to one of two groups by opening a sealed envelope. Group 1 patients received an instillation block and group 2 patients received an IG/IH nerve block. All blocks were performed with bupivacaine 0.25% without epinephrine. The instillation block (group 1) was performed by irrigating the wound with 0.25 ml/kg of 0.25% bupivacaine and allowing this solution to remain in the wound for 2 min. The remainder of the fluid was then suctioned from the wound. A needle was not used in the performance of this instillation block. The muscle layers were then closed. This instillation technique was repeated immediately prior to skin closure. The IG/IH nerve block (group 2) was performed by injecting 0.25 ml/kg of 0.25% bupivacaine into the oblique muscles through the lateral edge of the skin incision in the area just medial to the anterior superior iliac spine using a 23-G needle.⁹ The general anesthetic was discontinued at the end of the operation, and patients were transferred to the postanesthesia care unit (PACU). Upon arrival in the PACU, objective pain assessments were performed every 5 min by a research associate blinded to the type of regional anesthetic technique employed, using a standardized 10-point objective pain scale (table 1).⁹ Intravenous (iv) fentanyl 1–2 µg/kg was administered to any patient who achieved a pain score of 6 or more points on two successive 5-min observations. Patient recovery was assessed and recorded using a modified Aldrete and Kroulik scoring criteria (table 2).¹⁰ The time when all discharge criteria were met was also recorded.

Demographic data between the groups were compared

TABLE 1. Pediatric Objective Pain Scale⁹

	0	1	2
Blood pressure Crying	BP \pm 10% preoperative Not crying	BP > 20% preoperative Crying but responding to TLC	BP > 30% preoperative Crying but not responding to TLC
Movement Anxiety Posture	None Patient asleep or calm No special posture	Restless Mild Flexing leg and thigh	Thrashing Hysterical Holding groin

TLC = tender loving care. Children who were old enough to complain of pain were credited with 1 point if pain could not be localized

or 2 points if they could localize pain.

using Student's *t* test. Differences between the times to reach a score of 10 and the differences in pain and recovery scores between the two groups were compared using the Mann-Whitney test. Measurements are expressed as mean \pm SD, and the scores are presented by median and range. *P* < 0.05 was considered statistically significant.

Results

Thirty children received an instillation block (group 1) and 30 children had an IG/IH nerve block (group 2). Patients in both groups were comparable with regards to age, weight, and the duration of both surgery and anesthesia (table 3). There were no statistically significant differences between the two groups with regards to postoperative pain scores (fig. 1) or the need for iv administration of fentanyl in the PACU. Although the time required to reach a recovery score of 10 was longer in the instillation group, the time required to meet hospital discharge criteria was not significantly longer (table 4). There were no adverse effects observed with any of these blocks.

Discussion

Common approaches to the treatment of postoperative pain following inguinal hernia repair in children include the use of nonopioid analgesics, iv opioids, and peripheral nerve block techniques. Opioid analgesics are associated with an increased incidence of emesis and somnolence, both of which may delay a return to normal activity and

hence delay discharge from the hospital.¹¹ Regional techniques for postoperative analgesia, either caudal or IG/IH nerve block, have proven effective in controlling postoperative pain following inguinal herniorrhaphy in children.¹⁻⁴ Caudal techniques can, however, be time-consuming, require larger volumes of local anesthetic, achieve higher plasma levels of local anesthetic than infiltration techniques, and pose the risk of inadvertent subarachnoid or intravascular injection of local anesthetic. IG/IH nerve blocks have been associated with transient quadriceps paresis or hematomas and the risk of inadvertent bowel perforation.¹² Both methods can require the anesthesiologist to control the airway while a second person performs the block. Therefore, by definition, both procedures may be labor-intensive.

Wound infiltration, perfusion, or instillation with a local anesthetic solution has produced effective analgesia in previous studies.⁸ Prior to closure of the skin wound in patients undergoing cholecystectomy, Levack *et al.* placed a catheter through which they continually perfused the wound with either bupivacaine or saline.¹³ Those patients who had their wound perfused with bupivacaine had significantly less postoperative pain than did control patients. In addition, a similar study by Thomas *et al.* not only showed that bupivacaine instillation provided effective analgesia following cholecystectomy but also that the technique reduced opioid analgesic requirements and respiratory complications in the postoperative period when compared with controls.⁸ A previously published study by Hannallah *et al.* showed that an IG/IH nerve block performed with bupivacaine provided postoperative an-

TABLE 2. Modified Aldrete and Kroulik¹⁰ Recovery Room Scoring System

	0	1	2
Motor activity Respiration	No motion Airway needs maintenance	Weak motion Good airway	Active motion Crying or coughing on command
Systolic blood pressure	\pm 50% or more preanesthetic level	\pm 20-50%	\pm 20%
Consciousness Color	Absence of protective reflexes Cyanotic	Responding to stimuli Pale, dusky or blotchy	Easily arousable Pink

TABLE 3. Patient Demographic Data

	IG/IH	Instillation	Significance
No. of patients	30	30	
Age (mo)	69 ± 35	68 ± 31	NS
Weight (kg)	22 ± 10	21 ± 7	NS
Duration of operation (min)	27 ± 8	26 ± 10	NS
Duration of anesthesia (min)	55 ± 12	53 ± 12	NS

Values are mean ± SD.

algnesia that was just as effective as that produced by a caudal block in children following orchidopexy surgery.⁹ Other studies have shown that the application of topical lidocaine aerosol to the wounds of patients undergoing inguinal repair provided lower pain scores and decreased analgesic requirements in the first 24 h postoperatively when compared with placebo aerosol or control groups.⁶ However, unlike caudal or IG/IH nerve blocks, the instillation block cannot provide adjunct operative anesthesia. Instillation requires no special training and is not labor-intensive.

In summary, this study demonstrates that the instillation of bupivacaine into a wound provides postoperative

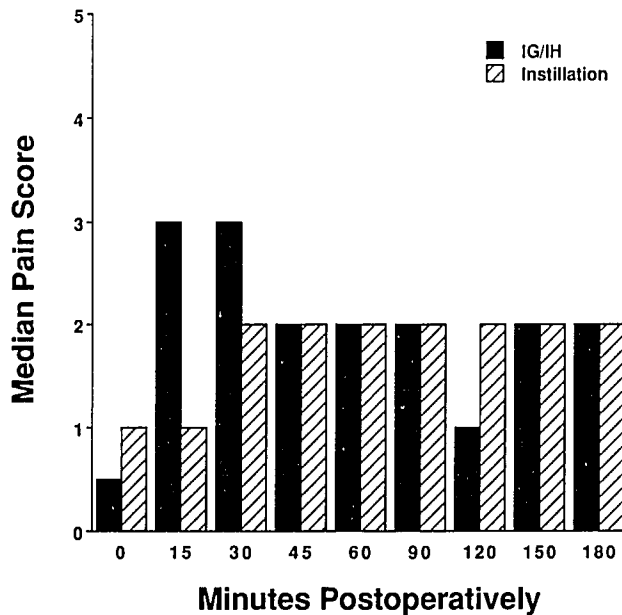


FIG. 1. Postoperative pain assessment utilizing an objective pain scale (0-10). The results on the graph are presented by median. The minimal/maximal scores for the IG/IH group are 0/9, 0/10, 0/4, 0/7, 0/4, 0/4, 0/5, 0/4, and 0/4 at 0, 15, 30, 45, 60, 90, 120, 150, and 180 min, respectively. The corresponding values for the instillation group are 0/10, 0/10, 1/6, 0/6, 0/4, 0/3, 0/6, 0/2, and 0/2.

TABLE 4. Postoperative Observations

	IG/IH	Instillation	Significance
Time to reach recovery score of 10 in PARR (min)	18 ± 7	22 ± 9	<i>P</i> < 0.05*
Time to discharge (min)	144 ± 56	131 ± 49	NS
No. of patients requiring fentanyl	1	1	NS

Values are mean ± SD.

* Mann-Whitney test.

pain relief following inguinal hernia repair, which is equal to that provided by IG/IH nerve blocks. Further studies are required to determine bupivacaine plasma concentration following this technique and the duration of analgesia following discharge from the hospital.

References

- Cross GD, Barrett RF: Comparison of two regional techniques for postoperative analgesia in children following herniotomy and orchidopexy. *Anaesthesia* 42:845-849, 1987
- Hinkle AJ: Percutaneous inguinal block for the outpatient management of post-herniorrhaphy pain in children. *ANESTHESIOLOGY* 67:411-413, 1987
- Langer JC, Shandling B, Rosenberg M: Intraoperative bupivacaine during outpatient hernia repair. *J Pediatr Surg* 22:267-270, 1987
- Markham SJ, Tomlinson J, Hain WR: Ilioinguinal nerve block in children. *Anaesthesia* 41:1098-1103, 1986
- Reid MF, Harris R, Phillips PD, Barker I, Pereira NH, Bennett NR: Day case herniotomy in children: A comparison of ilioinguinal nerve block and wound infiltration for postoperative analgesia. *Anaesthesia* 42:658-661, 1987
- Sinclair R, Cassuto J, Hogstrom S, Lindén I, Faxén A, Hedner T, Ekman R: Topical anesthesia with lidocaine aerosol in control of postoperative pain. *ANESTHESIOLOGY* 68:895-901, 1988
- Moss G, Regal ME, Lichig L: Reducing postoperative pain, narcotics and length of hospitalization. *Surgery* 90:206-210, 1986
- Thomas DFM, Lambert WG, Lloyd Williams K: The direct perfusion of surgical wounds with local anaesthetic solution: An approach to postoperative pain. *J R Coll Surg Eng* 65:226-229, 1983
- Hannallah RS, Broadman LM, Belman BA, Abramowitz MD, Epstein BS: Comparison of caudal and ilioinguinal/iliohypogastric nerve blocks for control of postorchidopexy pain in pediatric ambulatory surgery. *ANESTHESIOLOGY* 66:832-834, 1987
- Aldrete JA, Kroulik D: Postanesthetic recovery score. *Anesth Analg* 49:924-933, 1970
- Shafer A, White PF, Urquhart ML, Doze VA: Outpatient premedication: Use of midazolam and opioid analgesics. *ANESTHESIOLOGY* 71:495-501, 1989
- Roy-Shapira A, Amoury RA, Ashcraft KW, Holder TM, Sharp RJ: Transient quadriceps paresis following local inguinal block for postoperative pain control. *J Pediatr Surg* 20:554-555, 1985
- Levack ID, Holmes JD, Robertson GS: Abdominal wound perfusion for the relief of postoperative pain. *Br J Anaesth* 58: 615-619, 1986