

Special tubing is now manufactured with colored stripes bonded in the tubing walls that can be used to differentiate epidural infusions from iv infusions. Alternatively, "stripes" of tape can be added to clear tubing to distinguish it as epidural infusion tubing. It also has been recommended that if intermittent bolus injections of opioids are used instead of infusions, it is best to delineate clearly this injection port by covering it with a brightly colored cap, preferably in combination with a discriminating label.<sup>14</sup>

Descriptions of accidental drug administrations into the epidural space have been rare. The explosive growth in anesthesiologist-directed postoperative pain management services and the use of epidural opioid analgesia will increase the potential for these errors. We describe a case in which no neurologic sequelae resulted from the mistaken epidural infusion of cephazolin. Treatment consisted of changing the infusion tubing, flushing the epidural space with saline, and continuing the epidural fentanyl infusion. We further describe the measures we have taken to safeguard postoperative epidural infusions of fentanyl for patient-controlled epidural analgesia.

#### REFERENCES

1. Gambling DR, Yu P, Cole C, McMorland GH, Palmer L: A comparative study of patient controlled epidural analgesia (PCEA) and continuous infusion epidural analgesia (CIEA) during labor. *Can J Anaesth* 35:249-254, 1988
2. Chamberlain DP, Bodily MN, Olssen GL, Ramsey DH: Comparison of lumbar versus thoracic epidural fentanyl for post-thoracotomy

- analgesia using patient-controlled dosage. *Reg Anaesth* 14(2S): 26, 1989
3. Shanker KB, Palkar NV, Nishkala R: Paraplegia following epidural potassium chloride. *Anaesthesia* 40:45-47, 1985
4. Tessler MJ, White I, Naugler-Colville M, Biehl DR: Inadvertent epidural administration of potassium chloride. *Can J Anaesth* 35:631-633, 1988
5. Lin D, Becker K, Shapiro HM: Neurologic changes following epidural injection of potassium chloride and diazepam: A case report with laboratory correlations. *ANESTHESIOLOGY* 65:210-212, 1986
6. Forestner JE, Raj PP: Inadvertent epidural injection of thiopental. *Anesth Analg* 54:406-407, 1975
7. Wells D, Davies G, Wagner D: Accidental injection of epidural methohexital. *ANESTHESIOLOGY* 67:846-848, 1987
8. Dror A, Henriksen E: Accidental epidural magnesium sulfate injection. *Anesth Analg* 66:1020-1021, 1987
9. Patel PC, Sharif AMY, Farnando PUE: Accidental infusion of total parenteral nutrition solution through an epidural catheter. *Anaesthesia* 39:383-384, 1984
10. Usubiaga JE: Neurological complications following epidural analgesia. *Int Anesthesiol Clin* 13:19,50, 1975
11. Covino BG, Marx GF, Finster M, Zsigmond EK: Prolonged sensory/motor deficits following inadvertent spinal anesthesia. *Anesth Analg* 59:399-400, 1980
12. Birnbach DJ, Johnson MD, Arcario T, Datta S, Naulty JS, Osheimer GW: Effect of diluent volume on anaesthesia produced by epidural fentanyl. *Anesth Analg* 68:808-810, 1989
13. Cooper JB, Newbower RS, Kitz RJ: An analysis of major errors and equipment failure in anesthesia management: Considerations for prevention and detection. *ANESTHESIOLOGY* 60:34-42, 1984
14. Ready LB, Oden R, Chadwick HS, Benedetti C, Rooke GA, Caplan R, Wild LM: Development of an anesthesiology-based postoperative pain management service. *ANESTHESIOLOGY* 68:100-106, 1988

Anesthesiology  
72:947-950, 1990

## Spinal Epidural Hematoma Associated with Epidural Anesthesia: Complications of Systemic Heparinization in Patients Receiving Peripheral Vascular Thrombolytic Therapy

CURTIS A. DICKMAN, M.D.,\* STEVEN A. SHEDD, M.D.,† ROBERT F. SPETZLER, M.D.,‡  
ANDREW G. SHETTER, M.D.,§ VOLKER K. H. SONNTAG, M.D., F.A.C.S.¶

Spinal epidural hematomas have been reported as rare complications of spinal and epidural anesthesia. They most

commonly occur in patients who require intraoperative or postoperative anticoagulant administration<sup>1-6</sup> but may also develop in the absence of anticoagulant therapy.<sup>7</sup> Uncorrected coagulopathies or continuous anticoagula-

\* Resident, Division of Neurological Surgery, Barrow Neurological Institute.

† Attending Anesthesiologist, Director of Education, Department of Neuroanesthesiology, Barrow Neurological Institute.

‡ Attending Neurosurgeon, Director, Barrow Neurological Institute. J. N. Harber Chairman of Neurological Surgery, Professor and Chairman, Division of Neurological Surgery, University of Arizona College of Medicine.

§ Attending Neurosurgeon, Chairman, Section of Functional and Stereotactic Neurosurgery, Director, Pain Research Laboratory, Clinical Professor of Surgery (Neurosurgery), University of Arizona, College of Medicine.

¶ Attending Neurosurgeon, Vice Chairman, Division of Neurological

Surgery, Chairman, BNI Spinal Cord Injury Committee. Clinical Professor of Surgery (Neurosurgery), University of Arizona College of Medicine.

Received from the Barrow Neurological Institute, Phoenix, Arizona, and the University of Arizona College of Medicine, Tucson, Arizona. Accepted for publication January 16, 1990.

Address reprint requests to Dr. Spetzler: Barrow Neurological Institute, Editorial Office, 350 West Thomas Road, Phoenix, Arizona 85013-4496.

Key words: Anesthetic techniques: epidural; spinal. Complications: epidural hematoma. Heparin.

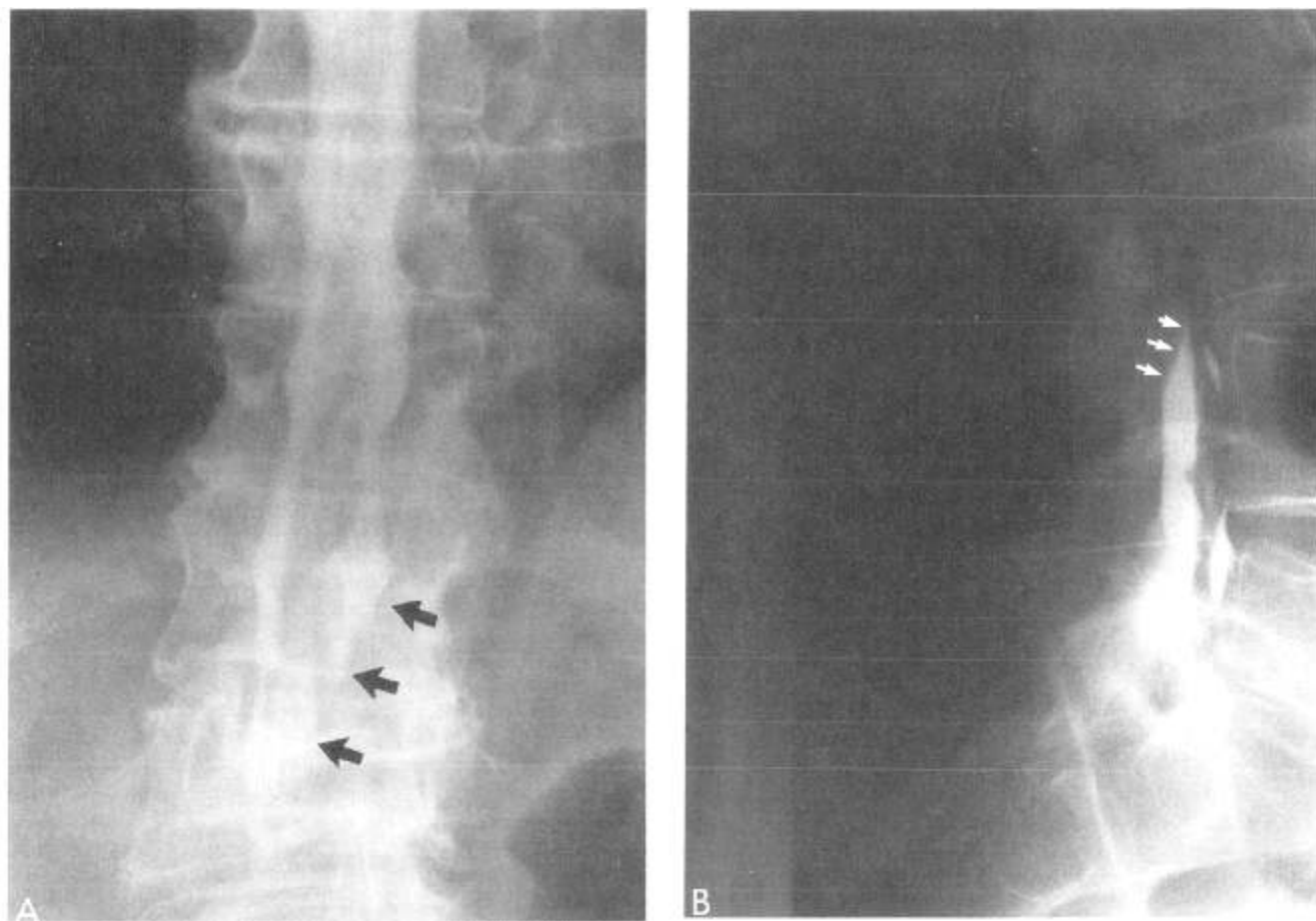


FIG. 1 A. An anteroposterior myelogram delineates the upper extent of an epidural hematoma (black arrows). B. The lateral view demonstrates a characteristic concave impression upon the thecal sac completely blocking the passage of contrast (white arrows) at the inferior border of the epidural hematoma.

tion are considered absolute contraindications to the insertion of epidural catheters; however, the risks of developing spinal epidural hematomas in patients receiving epidural anesthetics who require subsequent continuous anticoagulation are less defined.

### CASE REPORTS

*Case 1.* A 67-yr-old man presented with a 1-week history of recurrent occlusion of the left superficial femoral artery. After an extensive diagnostic evaluation that included arteriography, the patient had an intra-arterial catheter surgically inserted for urokinase infusion. A lumbar epidural catheter was inserted without difficulty and lidocaine 1.5% was used for anesthesia. A general anesthetic (nitrous oxide, oxygen, and isoflurane) was then administered. Following insertion of the intra-arterial catheter into the left femoral artery, the patient was returned to the intensive care unit for recovery and initiation of urokinase infusions. Three hours postoperatively the patient developed a large hematoma in the left groin and complained of back pain. He was taken to the operating room for removal of the femoral arterial catheter. The epidural catheter was removed before the removal of the arterial catheter. Anesthesia for evacuation of the groin hematoma consisted of local infiltration with lidocaine and supplemental inhalation of nitrous oxide and oxygen.

Postoperatively, the back pain persisted and paraplegia developed. Neurosurgical consultation was then obtained. Myelography (fig. 1) revealed a dorsal extradural mass, from the T12 to the L4 level, completely blocking the passage of subarachnoid contrast.

An emergency decompressive laminectomy was performed. A large, solidified hematoma beneath the ligamentum flavum was compressing the thecal sac. Evacuation was complete and the patient recovered full neurologic function within 3 days.

*Case 2.* A 74-yr-old man presented with a history of vascular claudication due to femoral artery occlusion. Preoperatively, a lumbar epidural catheter was inserted and lidocaine was administered to attain a T10-level sensory level. Laser thromboendarterectomy of the left femoral artery was performed.

Intraoperatively, heparin 2500 U was administered with a resultant activated clotting time of 309 s. After the procedure, the patient was admitted to the intensive care unit with the epidural catheter in place. Ten hours postoperatively a heparin infusion of 800 U/h was begun. On the morning of the first postoperative day the patient began to complain of back pain, his only complaint until an acute paraplegia developed 18 h later. An epidural hematoma was suspected and attempts at aspiration with the catheter and a second epidural needle were unsuccessful. The heparin infusion was discontinued and anticoagulation reversed with protamine, and the patient was then transferred to our institution.

Neurologic examination revealed a complete loss of motor function in the lower extremities and minimal sensory preservation. Myelog-

raphy demonstrated a spinal epidural hematoma from the upper thoracic spine to the fifth lumbar level. Immediate surgical decompression revealed an epidural hematoma extending from T2 to L5, compressing and displacing the spinal cord anteriorly. Upon decompression the spinal cord became pulsatile.

Within 24 h postoperatively motor function returned to the patient's lower extremities and his sensation improved dramatically. The patient has made a complete neurologic recovery.

#### DISCUSSION

Various complications are associated with epidural anesthesia, including spinal epidural hematomas,<sup>1-6</sup> spinal subdural hematomas,<sup>8,9</sup> intracranial subdural hematomas,<sup>10</sup> spinal headaches,<sup>2</sup> and toxic reactions.<sup>11</sup> What differentiated our cases from those previously reported is that they occurred with prolonged heparinization or urokinase administration, which may increase the risk of epidural anesthesia. The true incidence of the phenomenon is unknown. Forty-one cases of epidural hematomas were reported among 10,978 epidural blocks in a series from Beijing, China; however, the association with operative or perioperative anticoagulation was not described.<sup>12</sup>

A number of reports suggest that epidural anesthesia is safe even in patients requiring intraoperative anticoagulation.<sup>13-15</sup> Patients receiving minidose subcutaneous heparin for deep venous thrombosis prophylaxis also appear to have no additional risk of developing spinal epidural hematomas.<sup>16</sup>

A knowledge of the manifestations of spinal epidural hematomas, coupled with a high index of suspicion, may allow early recognition of this problem. The earliest symptom is localized back pain, which is then followed at a variable interval by motor and sensory deficits, often with bowel and bladder dysfunction. Rarely, spinal epidural hematoma may present as acute radiculopathies, chronic myelopathies,<sup>17</sup> or mimicking lumbar spinal stenosis.<sup>18</sup>

Most spinal epidural hematomas originate from bleeding from the extensive spinal epidural venous plexus. These hemorrhages are rarely due to an arterial source. The hemorrhage forms an epidural mass, restricted to the spinal canal, that may directly compress the cauda equina and spinal cord. This extradural mass may cause further neurologic dysfunction secondary to vascular insufficiency and ischemia.

Diagnostically, plain radiographs have little or no value. Computerized tomography (CT) without contrast is difficult to interpret due to bony artifact. CT with myelography is effective in demonstrating the cephalad and caudal extension of spinal epidural hematomas;<sup>19</sup> however, this method is invasive and may be complicated by contrast hypersensitivity reactions. Magnetic resonance (MR) imaging now appears to be the imaging modality of choice because it is noninvasive, sensitive, and specific.<sup>20</sup>

Since the first surgical decompression of a spinal epidural hematoma by Jonas in 1911,<sup>21</sup> emergency operative

intervention after restoration to normal of coagulation parameters has been advised. A few authors have advocated attempted aspiration of the blood percutaneously or through the existing epidural catheter. These maneuvers have never been reported as successful. The standard of care is urgent decompressive surgery. Considering the pathologic picture—the presence of a solid clot causing extensive neural compression—immediate surgery appears to be the most rational approach.

We wish to emphasize that recovery is related to how promptly the hematoma is recognized and treated and the degree of neurologic dysfunction.<sup>17,22,23</sup>

While intraoperative anticoagulation with heparin appears relatively safe if epidural catheters are inserted prior to anticoagulation,<sup>2,15</sup> prolonged postoperative anticoagulation or the use of thrombolytic agents (such as tissue plasminogen activator, urokinase, or streptokinase) may potentially increase the risk of epidural hematoma formation. In these instances, a high index of suspicion must be maintained to facilitate the early detection of complications.

#### REFERENCES

1. Butler AB, Green CD: Hematoma following epidural anaesthesia. *Can Anaesth Soc J* 17:635-639, 1970
2. DeAngelis J: Hazards of subdural and epidural anesthesia during anticoagulant therapy: A case report and review. *Anesth Analg* 51:676-679, 1972
3. Gingrich TF: Spinal epidural hematoma following continuous epidural anesthesia. *ANESTHESIOLOGY* 29:162-163, 1968
4. Helperin SW, Cohen DD: Hematoma following epidural anesthesia: Report of a case. *ANESTHESIOLOGY* 35:641-644, 1971
5. Janis KM: Epidural hematoma following postoperative epidural analgesia: A case report. *Anesth Analg* 51:689-692, 1972
6. Messer HD, Forshan VR, Brust JCM, Hughes JEO: Transient paraplegia from hematoma after lumbar puncture: A consequence of anticoagulant therapy. *JAMA* 235:529-530, 1976
7. Stephanov S, de Preux J: Lumbar epidural hematoma following epidural anesthesia. *Surg Neurol* 18:351-353, 1982
8. Greensite FS, Katz J: Spinal subdural hematoma associated with attempted epidural anesthesia and subsequent continuous spinal anesthesia. *Anesth Analg* 59:72-73, 1980
9. Jack TM: Subdural hematoma as a complication of spinal anesthetic (letter) *Br Med J* 285:972, 1982
10. Rudehill A, Gordon E, Rahn T: Subdural hematoma. A rare but life-threatening complication after spinal anesthesia. *Acta Anaesthesiol Scand* 27:376-377, 1983
11. Rosen MA, Baysinger CL, Shnider SM, Dailey PA, Norton M, Curtis JD, Collins M, Davis RL: Evaluation of neurotoxicity after subarachnoid injection of large volumes of local anesthetic solutions. *Anesth Analg* 62:802-808, 1983
12. Major complications in continuous epidural anesthesia. *Chin Med J* 93:194-200, 1980
13. Dripps RD, Vandam LD: Long-term follow-up of patients who received 10,098 spinal anesthetics: Failure to discover major neurological sequelae. *JAMA* 156:1486-1491, 1954
14. Rao TLK, El-Etr AA: Anticoagulation following placement of epidural and subarachnoid catheters: An evaluation of neurological sequelae. *ANESTHESIOLOGY* 55:618-620, 1981

15. Odom JA, Sih IL: Epidural analgesia and anticoagulant therapy. Experience with one thousand cases of continuous epidurals. *Anaesthesia* 38:254-259, 1983
16. Allemann BH, Gerber H, Gruber UF: Rückenmarksnahe anaesthetie und subkutan verabreichtes low-dose heparin-dihydroergot zur thromboembolieprophylaxe. *Anaesthesist* 32:80-83, 1983
17. Laursen J, Fode K, Dahlerup B: Spinal epidural hematomas. *Clin Neurol Neurosurg* 89:247-253, 1987
18. Nehls DG, Shetter AG, Hodak JA, Waggner JD: Chronic spinal epidural hematoma presenting as lumbar stenosis: Clinical, myelographic and computed tomographic features. *Neurosurgery* 14:230-233, 1984
19. Zilkha A, Irwin G, Fagelman D: Computed tomography of spinal epidural hematomas. *AJNR* 4:1073-1076, 1983
20. Pan G, Kulkarni M, MacDougall DJ, Miner ME: Traumatic epidural hematoma of the cervical spine: Diagnosis with magnetic resonance imaging. Case report. *J Neurosurg* 68:798-801, 1988
21. Jonas AF: Spinal fractures. Opinions based on observations of sixteen operations. *JAMA* 57:859-865, 1911
22. Foo D, Rossier AB: Preoperative neurological status in predicting surgical outcome of spinal epidural hematomas. *Surg Neurol* 15:389-401, 1981
23. Grollmuss J, Hoff J: Spontaneous spinal epidural haemorrhage: Good results after early treatment. *J Neurol Neurosurg Psychiatry* 38:89-90, 1975

Anesthesiology  
72:950-951, 1990

## Induction of Thiopental Anesthesia without Tracheal Intubation in a Patient with Hiatal Hernia: Use of Esophageal pH Monitoring

W. ANDREW KOFKE, M.D.,\* T. THAYER, C.R.N.A.†

Presence of hiatal hernia can be a vexing problem in patients in whom gradual induction of anesthesia without tracheal intubation is preferred.<sup>1</sup> At our institution the protocol for evaluation of patients with intractable epilepsy for surgical removal of epileptic foci includes a thiopental test with depth electrodes placed into suspect areas of the brain (*e.g.*, hippocampus). This test entails administration, to an otherwise unmedicated patient, of thiopental 25 mg every 30 s until a dose sufficient to abolish the corneal reflex or 1 g (whichever is less) is administered.<sup>2</sup> This protocol precludes the use of additional drugs needed for insertion of an endotracheal tube. We recently cared for a patient with a history of symptomatic hiatal hernia and intractable epilepsy who required a thiopental test.

### CASE REPORT

A 27-yr-old woman was admitted for evaluation of medically intractable epilepsy. She had complex partial seizures dating back to infancy following vaccination for diphtheria, pertussis, and tetanus. Seizures occurred as often as six to 12 times per day. Other medical

problems included obesity, hiatal hernia, and peptic ulcer disease. The diagnosis of hiatal hernia was based on the patient's description of symptomatic reflux and an endoscopic diagnosis made 11 yr earlier. She complained of epigastric discomfort while in the supine position that improved when the head of her bed was elevated 45 degrees. Medications included carbamazepine, levothyroxine, and Mylanta®. She underwent insertion of depth electrodes on the second hospital day. For this procedure rapid sequence induction of anesthesia was employed using 450 mg of thiopental, 140 mg of succinylcholine, preceded by 3 mg d-tubocurarine and cricoid pressure.<sup>3</sup> Subsequently, anesthesia was uneventfully maintained with isoflurane, nitrous oxide, and fentanyl.

Because of concerns regarding the severity of her gastric reflux, she underwent ambulatory esophageal pH monitoring for 24 h. This test disclosed mild esophageal reflux that was most pronounced at night while supine and postprandially. She thus seemed to be at risk of gastric reflux and acid aspiration with induction of thiopental anesthesia.

The night before and the morning of her thiopental test which was scheduled for 10 A.M., she received ranitidine 150 mg orally. On the morning of her test she also received metoclopramide 10 mg iv and had a Salem sump nasogastric tube inserted that was placed to low intermittent suction.<sup>4</sup> This nasogastric tube was one modified by Sensatronix Medical Systems Incorporated (Plainfield, NJ) which had an antimony pH probe on the tip that was electrically connected to a monitor that continuously displayed pH at the tip of the nasogastric tube.

Prior to induction of anesthesia the nasogastric tube was suctioned and the tip withdrawn to approximately midesophageal position. The thiopental test was performed with monitoring of the depth electrode electroencephalogram in the Epilepsy Center Monitoring Suite. Additional monitoring consisted of EKG, automatic indirect blood pressure, pulse oximetry, and precordial stethoscope auscultation in the suprasternal notch. The test was performed with the head of the bed elevated 30 degrees. While breathing spontaneously she received 25 mg of thiopental every 30 s, receiving a total of 1 g. Airway management was not problematic as she breathed spontaneously throughout the test and did not develop airway obstruction. Oxygen was administered *via* face mask at 10 l/min and cricoid pressure<sup>3</sup> was applied continuously throughout the 35-min procedure. Esophageal pH varied sub-

\* Associate Professor, Departments of Anesthesiology and Critical Care Medicine, and Neurological Surgery. Director, Neurologic Anesthesia and Supportive Care Program. Consultant, University of Pittsburgh Epilepsy Center, University of Pittsburgh School of Medicine.

† Nurse Anesthetist, Presbyterian University Hospital, University Health Center of Pittsburgh.

Received from the Departments of Anesthesiology and Critical Care Medicine, and Neurological Surgery, University of Pittsburgh School of Medicine, Pittsburgh, Pennsylvania. Accepted for publication January 16, 1990.

Key words: Airway. Anesthetics, intravenous: thiopental. Complications: aspiration. Epilepsy. Hiatal Hernia.