

Idiopathic Hypertrophic Subaortic Stenosis and Ischemic Mitral Regurgitation: The Value of Intraoperative Transesophageal Echocardiography and Doppler Color Flow Imaging in Guiding Operative Therapy

THOMAS E. STANLEY III, M.D.,* J. SCOTT RANKIN, M.D.†

Transesophageal echocardiography (TEE) is rapidly becoming an important tool for intraoperative monitoring of cardiac function. Recently, Doppler color flow imaging (DCFI) has been added as a feature of TEE instruments. Doppler technology provides the ability to visualize and subjectively assess intracardiac blood flow in terms of direction, velocity, and turbulence. This in turn assists in the intraoperative characterization of known cardiac lesions, the discovery of unsuspected abnormalities, as well as the evaluation of surgical interventions such as valve repair. As an example of the usefulness of this tool, we describe a patient with ischemic heart disease and symptomatic mitral regurgitation, who during the preoperative evaluation, was found to have asymmetric septal hypertrophy and idiopathic hypertrophic subaortic stenosis (IHSS). TEE and DCFI used during surgery correctly identified a worsened left ventricular outflow tract obstruction as a result of mitral valve repair and provided an accurate and timely impetus to perform mitral valve replacement, which was successfully completed with a favorable outcome.

CASE REPORT

The patient is a 67-yr-old woman with a long-standing history of stable angina after myocardial infarction who presented with symptoms of increasing angina and congestive heart failure. A murmur of mitral regurgitation was heard on examination. She underwent cardiac catheterization which revealed significant (3+) mitral regurgitation. Coronary angiograms demonstrated a 75% stenosis of the mid left anterior descending coronary artery (LAD), and a similar lesion in the first anterolateral branch of the LAD. In addition, there were two 50% lesions in the right coronary artery (RCA). A standard precordial echocardiogram was performed, which confirmed moderate mitral regurgitation by Doppler color flow imaging. Asymmetric septal hyper-

trophy was noted on this exam with possible obstruction of the left ventricular outflow tract (LVOT). Interestingly, the ventriculogram obtained at the time of cardiac catheterization had reported both the ventricular cavity size and systolic wall thickening to be normal. The patient also had a radionuclide angiogram which demonstrated a significant decrease in left ventricular ejection fraction with exercise, suggesting myocardial ischemia. Based on these data and the patient's clinical status, coronary artery bypass grafting and mitral valve repair or replacement was scheduled.

The patient received lorazepam 2 mg and methadone 10 mg orally 1 h prior to surgery. Intra-arterial and pulmonary artery (PA) catheters were inserted. Baseline arterial pressure was 140/70 and PA pressure was 42/20 with a pulmonary capillary wedge pressure of 17 mmHg. Cardiac output measured by thermodilution was 3.5 l/min. General anesthesia was induced using iv sufentanil and vecuronium with no significant hemodynamic perturbation noted. After tracheal intubation, a Hewlett-Packard 21362A 5 MHz transesophageal transducer (Hewlett-Packard Company, Palo Alto, CA) was introduced into the esophagus without difficulty, and images obtained using a Hewlett-Packard 77020A phased array sector and Doppler color flow scanner. Initial TEE examination confirmed an area of eccentric increased thickness of the basal portion of the interventricular septum extending into the LVOT consistent with asymmetric septal hypertrophy. There was moderate prolapse of the anterior leaflet of the mitral valve, which appeared thickened. Careful review of the recorded images, synchronized with a simultaneously recorded electrocardiogram, failed to demonstrate the classic systolic anterior motion (SAM) of the anterior mitral valve leaflet associated with IHSS. In addition, DCFI demonstrated a moderate jet of mitral regurgitation but no significant turbulence in the LVOT, suggesting that any outflow tract obstruction was of minimal significance (fig. 1 A).

As a test of the severity of the mitral regurgitation, after cannulating for but prior to initiating cardiopulmonary bypass (CPB), several hundred milliliters of priming solution were rapidly infused *via* the aortic cannula. DCFI demonstrated highly increased regurgitant flow across the mitral valve after only a small increase in left atrial pressure (LAP). Moreover, the LAP waveform demonstrated a significant V wave. Based on this information, a Kay mitral valve annuloplasty was performed after aortic crossclamping and cardioplegic arrest. Also, a saphenous vein bypass graft was placed to the distal RCA and the left internal mammary artery was anastomosed to the proximal LAD.

After removal of the aortic crossclamp and restoration of sinus rhythm, repeat TEE/DCFI examination was performed. The first TEE survey was done to insure adequate removal of intracavitary air. Then with increased volume loading, but before any attempt at separation from CPB, TEE imaging demonstrated that the procedure had successfully resolved the prolapse of the anterior mitral valve leaflet. However, it appeared that this correction had resulted in substantial narrowing of the LVOT. DCFI confirmed this finding by showing marked turbulence of systolic flow through the LVOT (fig. 1 B). In addition, there was diastolic turbulence through the repaired mitral valve, suggesting a degree of functional mitral valve stenosis. From these data it was suspected that IHSS pathophysiology, previously

* Assistant Professor of Anesthesiology, Division of Cardiac Anesthesia.

† Associate Professor of Surgery, Assistant Professor of Physiology. Received from The Heart Center of Duke Hospital, Duke University Medical Center, Durham, North Carolina 27710. Accepted for publication January 8, 1990.

Address reprint requests to Dr. Stanley: Department of Anesthesiology, P.O. Box 3094, Duke University Medical Center, Durham, North Carolina 27710.

Key words: Heart: idiopathic Hypertrophic Subaortic Stenosis; mitral regurgitation. Monitoring: transesophageal echocardiography; Doppler color flow imaging.

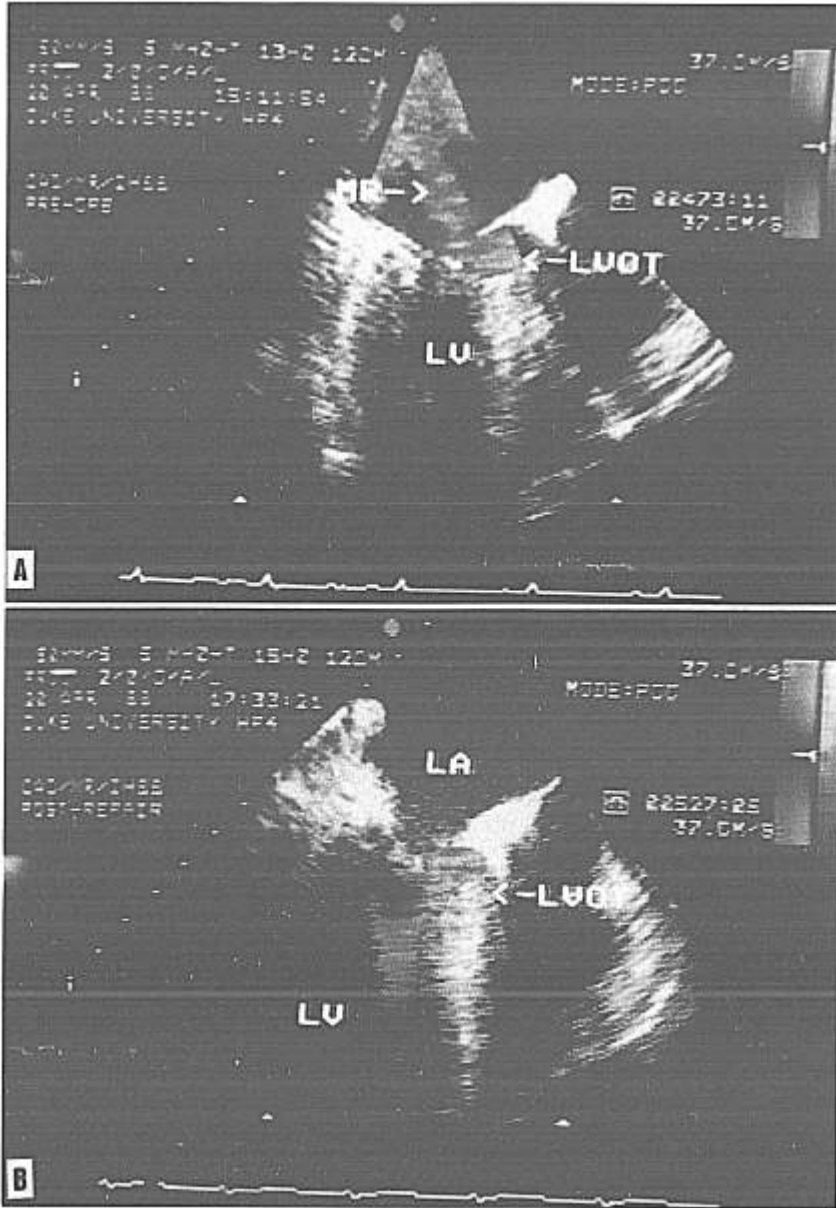


FIG. 1. *A* Transesophageal echocardiogram and Doppler color flow image of patient prior to CPB. A long axis view is shown during systole with left atrium (LA) and left ventricle (LV) identified. The left ventricular outflow tract (LVOT) is narrowed by the hypertrophied interventricular septum. A mosaic color jet representing mitral regurgitation (MR) is seen extending into the left atrium. *B* A similar TEE/DCF image in systole recorded following mitral valve repair. The mitral valve annulus has been narrowed, and the anterior mitral valve leaflet is impinging on the LVOT where there is now turbulent (mosaic color) flow suggesting outflow obstruction.

masked by prolapsing of the anterior mitral valve leaflet, was now uncovered by the restoration of normal mitral valve geometry. This abnormality would certainly be worsened by the mitral stenosis seen on DCFI exam. An attempt to discontinue CPB was made. However, left ventricular ejection was inadequate despite maximal diastolic filling pressures and what appeared to be acceptable left ventricular contractile function as evaluated using TEE. Because of a lack of unanimous confidence in the TEE/DCF diagnosis, a brief trial of inotropic therapy was given. This resulted in worsening of the hemodynamic compromise, offering further proof that the echocardiographic demonstration of dynamic LVOT obstruction was correct. Cardiopulmonary bypass was resumed immediately, and the decision was made to replace the mitral valve. Hypothermia and cardioplegic arrest were reinstated. The left atriotomy was reopened and a mitral valve replacement performed using a St. Jude prosthesis. The native anterior mitral valve leaflet was excised but the posterior leaflet was left intact. Later pathologic ex-

amination of the anterior mitral leaflet revealed fibrosis and myxoid degeneration.

Again, following crossclamp removal and return of an adequate cardiac rhythm, TEE/DCF was repeated which demonstrated resolution of the LVOT obstruction. Inotropic support was then established and the patient was separated from CPB without difficulty. Mean LAP was stable at 8–12 mmHg, and the cardiac output ranged from 3.5–4 l/min. The remainder of the surgical procedure was uneventful and the patient was transferred to the intensive care unit in stable condition.

DISCUSSION

This case demonstrates the significant advantages provided by transesophageal echocardiography and Doppler color flow imaging in the intraoperative setting and that

the information that this tool can provide is accurate and trustworthy. In this particular case, TEE/DCFI was the only cardiovascular monitor that correctly indicated the cardiac pathophysiology while the patient was still on cardiopulmonary bypass.

Doppler color flow imaging is a recent technological advance that has as its basis the well known principle of a change in perceived frequency of emitted or reflected sound waves caused by a moving target. Red blood cells act as such targets and their direction and velocity in vascular structures can be measured using the Doppler principle. Previously this information was available in only one small area (the sample volume) that was chosen by the echocardiographer using a pulsed Doppler probe that is restricted to interrogation in a single dimension. Now largely due to improvements in the speed and sophistication of electronic processing, modern phased array ultrasound transducers can simultaneously capture and display both the reflective image information (high frequency) and the flow direction and velocity information (low Doppler shift frequency) in two dimensions. As demonstrated in figures 1 A and B, this allows the examiner to identify cardiac structures as well as the blood flow within them in real time. In order to represent flow information over this area, each of the many sample volumes acquired are assigned a color to indicate the flow characteristics at that discrete location. By convention, flow toward the transducer appears red and flow away is colored blue. The intensity of the color describes the blood flow velocity. In areas of turbulence in which great variation in flow occurs in adjacent physical areas, a mosaic pattern of color emerges.¹ In a clinical exam, a mosaic jet is usually quite specific for high-velocity flow through a relatively small orifice such as exists in a regurgitant valvular lesion. In this case mitral regurgitation as well as LVOT obstruction were diagnosed in this way. Obviously, the ability to acquire and display this information as the surgical procedure progresses is the key advantage of TEE/DCFI.

The use of echocardiography in the diagnosis of IHSS is not new. Much of the early work describing the specific characteristics of IHSS, such as asymmetric septal hypertrophy and the more subtle systolic anterior motion of the anterior mitral valve leaflet, was done using M-mode echocardiograms.²

Likewise, echocardiography has already been used to assess the efficacy of the various methods of surgically treating IHSS. Krajcer *et al.*³ obtained pre- and postoperative M-mode echocardiograms in patients undergoing either myomectomy or mitral valve replacement for IHSS. These data, in combination with pressure gradient infor-

mation at cardiac catheterization led the authors to conclude that echocardiography could be of significant value in describing the anatomic and hemodynamic consequences of IHSS surgery. Our case thus provides an example of a further expanded usefulness of echocardiographic techniques in the surgical treatment of this disease.

Of course there are many other more commonly occurring instances in which TEE/DCFI can assist in the intraoperative management of cardiac surgical patients.⁴ Assessment of prosthetic valve dysfunction is easily implemented. In fact, the transesophageal approach is often the only view that can accurately diagnose the development of regurgitation through or around mitral valve prostheses because ultrasound shadowing by the prosthesis itself precludes viewing the left atrium from a transthoracic approach. Evaluation of septal defect repair can be done in the operating room prior to separation from CPB. The effects of vasoactive drugs or other interventions on the correction of ischemic valvular dysfunction following complex or prolonged cardiac surgical procedures can be followed using TEE/DCFI. Echocardiography is the most sensitive method for detecting air bubbles and provides instantaneous evaluation of surgical steps to remove air following open-chamber procedures. Finally, the ability of TEE to define regional cardiac wall motion abnormalities offers an important advantage in guiding therapy in patients with known or suspected ischemic heart disease.

In summary, we present a case of complex cardiac pathophysiology in which TEE/DCFI provided valuable information of the effects of operative intervention during the procedure itself. Decisions of surgical course were significantly influenced by data from this new monitoring modality. It appears certain that echocardiography will continue in its growth as an important addition in the intraoperative care of cardiac surgical patients.

REFERENCES

1. Kisslo J, Adams DB, Belkin RN: Doppler Color Flow Imaging. New York, Churchill Livingstone, 1988, pp 25-46
2. Shah PM, Gramiak R, Adelman AG: Role of echocardiography in diagnostic and hemodynamic assessment of hypertrophic subaortic stenosis. *Circulation* 44:891-898, 1971
3. Krajcer Z, Lufscanowski R, Angelini P, Leachman RD, Cooley DA: Septal myomectomy and mitral valve replacement for idiopathic hypertrophic subaortic stenosis. An echocardiographic subaortic stenosis. *Circulation* 62 (Suppl I):1158-1164, 1980
4. de Bruijn NP, Clements FM, Kisslo JA: Intraoperative transesophageal color flow mapping: Initial experience. *Anesth Analg* 66:386-390, 1987