

## Intraoperative Autotransfusion for a Patient with Homozygous Sickle Cell Disease

AARON COOK, M.D.,\* LELAND H. HANOWELL, M.D.†

To our knowledge intraoperative autotransfusion (IAT) for a patient with homozygous sickle cell disease has not been described. We report intraoperative autotransfusion of blood lost during hip arthroplasty in a patient with hemoglobin SS.

## CASE REPORT

A 19-yr-old man with homozygous sickle cell anemia underwent bilateral cementless hemiarthroplasties for femoral head avascular necrosis. Painful sickling crises required multiple prior blood transfusions. Because of resultant acquired red blood cell (RBC) antibodies, procurement of compatible banked blood was difficult and expensive. The blood type was O, Rh (D<sup>+</sup>); subtypes Js<sup>b-</sup>, Fy<sup>a-</sup>, K<sup>-</sup>, C<sup>-</sup>, E<sup>-</sup>, S<sup>-</sup>, Jk<sup>a-</sup>. Antibodies to anti-Sutter B (Js<sup>b</sup>), anti-big C (C), anti-big E (E), and anti-Duffy (Fy<sup>a</sup>) were identified. This blood type was estimated to occur in the black population with an incidence of 1/18,000. Surgery was delayed 2 months to obtain sufficient bank blood for anticipated perioperative transfusion.

Admission hemoglobin (Hb) and reticulocyte count were 7.7 g/dl and 2.2%, respectively. Preoperative exchange transfusions removed 1,800 ml of blood replaced with 9 units of homologous packed red blood cells (PRBC). Electrophoresis subsequently showed Hb S 25% and Hb A 71%. Preoperative Hb concentration was 11.5 g/dl.

General anesthesia was requested by the patient. An epidural catheter was inserted after which anesthesia was induced with thiopental. Tracheal intubation and controlled ventilation were employed. Anesthesia was maintained with isoflurane and with epidural injection of local anesthetic and preservative-free morphine during bilateral arthroplasties. Intraoperative monitoring included arterial catheterization for direct blood pressure monitoring, end-tidal gas monitoring by mass spectrometry, and hemoglobin saturation (Sp<sub>O<sub>2</sub></sub>) monitoring with a pulse oximeter.

An autotransfusion device (Autotrans BT 795, Dideco, Electromedics, Englewood, Colorado) was used intraoperatively (fig. 1). Continuous infusion of heparinized normal saline (40,000 units/l heparin) through a double-lumen suction catheter provided anticoagulation of blood from the surgical field. Each 700 ml of blood collected in the cardiomy reservoir was filtered, centrifuged, and washed with 1,000 ml of normal saline to produce 1 unit (225 ml) of PRBC for reinfusion. Autologous and banked blood were infused through separate 20- $\mu$ m Pall filters (Pall Biomedical Products Corporation, East Hills, New York). Estimated blood loss was 2,200 ml, 3 units (675 ml) of autologous blood was salvaged and reinfused. Normal saline was used for all op-

erative field irrigation. Intraoperative Sp<sub>O<sub>2</sub></sub> was maintained at 100%. Arterial pH intraoperatively ranged from 7.44 to 7.33. Peripheral venous blood smears obtained preoperatively and Wright stained preparations of red cells processed by the autotransfusion device were compared prior to reinfusion to assess the extent of sickling. Less sickling was noted in the processed blood. PaO<sub>2</sub>, O<sub>2</sub> saturation, pH, WBC, Hb, Hct, platelet count, serum potassium (K<sup>+</sup>), and sickling were quantitated in preoperative and postoperative peripheral venous samples, reservoir samples (A), reinfused autologous blood, and discarded cell-washing solution (B). Figure 1 shows sampling sites A and B, and table 1 summarizes the data.

One unit of homologous, banked PRBC was administered intraoperatively along with 9,000 ml of intravenous crystalloid fluids. Urine output during surgery was 1,650 ml without evidence for hemolysis. Double warming blankets, a heated humidifier in the anesthetic circuit, and warming of infused fluids maintained temperature between 36.8° C and 37.4° C. Supplemental oxygen was administered by nasal cannula postoperatively.

By the fourth day Hb had fallen to 6.3 g/dl and 2 units of banked PRBC was transfused. A delayed hemolytic reaction was confirmed by the detection of the anti-Kidd A (Jk<sup>a</sup>) antibody in the patient's blood. Hb and corrected reticulocyte count on day 16 were 6.1 g/dl and 15.2%, respectively, and the patient was discharged home.

## DISCUSSION

IAT has many potential advantages over banked blood for patients requiring intraoperative transfusion, especially those with sickle cell disease. IAT could lessen risks of isoimmunization to donor cells or HLA antigens.<sup>1</sup> A single compatible unit of PRBC of the rare blood type described cost approximately \$1,500, far above the average \$815 expense of IAT at our institution. Our patient's preoperative hematocrit was 35% and his estimated blood loss (EBL) was 2,200 ml; 675 ml was reinfused with an Hct of 46%. The overall salvage rate of EBL for our patient was 40%.

Preoperative donation of autologous blood by patients with sickle cell disease should be used for all elective surgery whenever feasible. Autologous blood collected preoperatively from patients with sickle cell disease and sickle cell trait can be stored in liquid and frozen forms and used safely with adequate RBC survival.<sup>2,3</sup> Chung *et al.*<sup>4</sup> and Pearson<sup>5</sup> proposed that decreasing the Hb S to below 30% by preoperative exchange transfusion decreased requirements for intraoperative transfusion. Black‡ used a cell saver to completely eliminate sickle cells during an exchange transfusion prior to cardiopulmonary bypass.

‡ Black HA, Dearing JP: Exchange transfusion prior to cardiopulmonary bypass in sickle cell anemia. *J Extracorporeal Technol* 12:82-85, 1980

\* Senior Resident.

† Assistant Professor.

Received from the Department of Orthopaedics and the Department of Anesthesiology, University of California, Davis School of Medicine, Sacramento, California. Accepted for publication February 12, 1990.

Address reprint requests to Dr. Hanowell: Department of Anesthesiology, University of California, Davis School of Medicine, 2315 Stockton Boulevard, Sacramento, California 95817.

Key words: Autotransfusion. Blood: sickle cell disease.

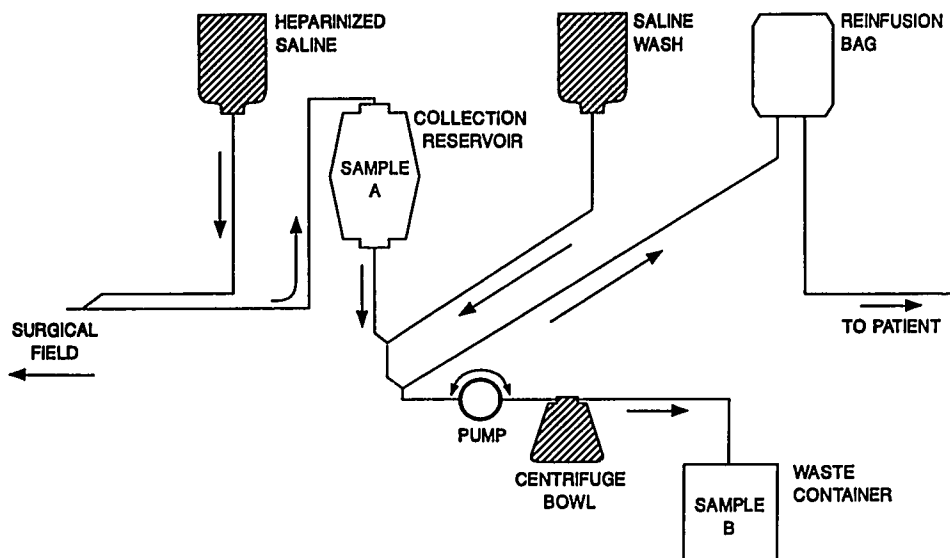


FIG. 1. The autoinfusion system is diagrammed to show the sampling sites. Sample A is blood from the reservoir, and sample B is serum and saline collected during cell washing. The reinfusion bag contains processed blood for reinfusion. Reprinted from Hanowell LH, Eisele JH, Erskine EV. Autotransfusor removal of fentanyl from blood. *Anesth Analg* 69:239-241, 1989, with permission.

Castro (Personal communication, December 1988) and Gilcher (Personal communication, December 1988) recommended preoperative exchange transfusion to decrease the percent of Hb S and the risk of irreversible sickling and crisis intraoperatively.

Tawes *et al.*<sup>6</sup> without further reference, stated anecdotally that IAT is "ill advised in patients with sickle cell anemia." We have not found any literature or previous experience to support this recommendation. Castro *et al.*<sup>7</sup> noted clumping of sickle cells in the centrifugation bowl of the Haemonetics 30S Blood Cell Processor during automated RBC exchange. They described a technique to avoid sickling during RBC processing by dilution of blood with normal saline prior to processing in the centrifuge bowl. They suggested that dilution of sickle cells and, possibly, ambient oxygen dissolved in normal saline diluent accounted for the lower incidence of sickling during their collections of blood from patients with Hb S. We did not encounter sickling in the centrifuge bowl of the autoinfusion device or in processed autologous blood. Explanations for this lack of sickling include a predomi-

nance of Hb A from preoperative exchange transfusion, oxygenation of Hb during blood processing, and alkaline pH due to depletion of carbon dioxide from blood during processing.

Partial pressure of carbon dioxide in our samples were 6 mmHg and 3 mmHg for the reservoir and transfused (processed) blood samples, respectively. Sickling of red cells is promoted by acid pH and oxygen saturation below 85%,<sup>8</sup> not apparent during autologous blood processing.

A recent letter to ANESTHESIOLOGY suggested that autoinfusion of blood was contraindicated in patients with sickle cell trait.<sup>9</sup> These authors described that processing of blood from a patient with sickle cell trait resulted in extensive sickling during their use of the Haemonetics Cell Saver III. There was no sickling apparent in samples they examined from either the patient or the reservoir bowl prior to blood processing. It was not until the cells were processed by centrifugation that sickling occurred. Furthermore, there was no dilution of cells with a potential to sickle by preoperative exchange transfusion, not used for patients with sickle cell trait. Because our patient

TABLE 1. Characteristics of Blood from Various Sites

|                                   | Preoperative Venous | Reservoir Sample | Reinfused Blood | Discarded Cell-Washing Solution | Postoperative Arterial |
|-----------------------------------|---------------------|------------------|-----------------|---------------------------------|------------------------|
| pH                                | —                   | 7.78             | 7.81            | 7.77                            | 7.34                   |
| P <sub>O<sub>2</sub></sub> (mmHg) | —                   | 173.4            | 217.3           | 191.3                           | 108.0                  |
| Sa <sub>O<sub>2</sub></sub> (%)   | —                   | 100.0            | 100.0           | 100.0                           | 96.0                   |
| WBC (10 <sup>3</sup> /ml)         | 9.0                 | 6.3              | 12.7            | —                               | 28.8                   |
| Hb (g/dl)                         | 11.6                | 6.8              | 15.5            | 1.5                             | 9.1                    |
| Hct (%)                           | 34.7                | 16.4             | 46.2            | —                               | 26.9                   |
| Platelets (10 <sup>3</sup> /ml)   | 282                 | —                | —               | —                               | 182.0                  |
| K <sup>+</sup> (mEq/l)            | 3.8                 | 10.23            | 2.13            | 5.67                            | 4.1                    |
| Sickle cells                      | Marked              | Occasional       | Slight          | —                               | Slight/moderate        |

TABLE 2. Suggested Guidelines for Intraoperative Autotransfusion Trials in Patients with Sickle Cell Disease

---

|  |
|--|
| Preoperative considerations  |
| Exchange transfuse to attain 60–70% Hb A and Hct 30–36%  |
| Bank autologous blood if feasible  |
| Intraoperative considerations  |
| Solutions with physiologic pH for wound lavage and cell washing                                    |
| Limit negative pressure at tip of large bore suction cannulae in surgical field to <100 mmHg       |
| Compare smears of venous and processed blood prior to reinfusion to quantitatively assess sickling |
| Monitor pH, P <sub>O<sub>2</sub></sub> , and Hct of processed blood                                |
| Anticoagulate harvested blood (heparin) until processing   |
| Wash RBC with 1–2 l of normal saline to remove waste products and filter before reinfusion         |

---

had no adverse sequelae from IAT, it appears that intraoperative salvage of blood is possible in the patient with homozygous sickle cell disease if exchange transfusion is given preoperatively. Table 2 suggests considerations for future trials of IAT in patients with sickle cell disease. If extensive sickling is apparent after processing of blood, as determined by microscopic examination, reinfusion should be aborted. The key feature for successful IAT may well be adequate preoperative exchange transfusion to provide dilution of sickle cells such that extensive sick-

ling does not occur in the centrifuge bowl of the autotransfusion device.

#### REFERENCES

1. Davies SC, McWilliam AC, Hewitt PE, Devenish A, Brozovic M: Red cell alloimmunization in sickle cell disease. *Br J Haematol* 63:241–245, 1986
2. Chaplin H, Mischeaux JR, Inkster MB, Sherman LA: Frozen storage of 11 units of sickle cell red cells for autologous transfusion of a single patient. *Transfusion* 26:341–345, 1986
3. Romanoff ME, Woodward DG, Bullard WG: Autologous blood transfusion in patients with sickle cell trait (letter). *ANESTHESIOLOGY* 68:820–821, 1988
4. Chung SMK, Alavi A, Russell MO: Management of osteonecrosis in sickle cell anemia and its genetic variants. *Clin Orthop* 130: 158–174, 1978
5. Pearson HA: Sickle cell diseases: Diagnosis and management in infancy and childhood. *Pediatr Rev* 9:121–130, 1987
6. Tawes RL, Scribner RG, Duval TB, Beare JP, Sydorak GR, Rosenman JE, Brown WH, Harris FJ: The cell-saver and autologous transfusion: An underutilized resource in vascular surgery. *Am J Surg* 152:105–109, 1986
7. Castro O, Finke-Castro H, Coats D: Improved method for automated red cell exchange in sickle cell disease. *J Clin Apheresis* 3:93–99, 1986
8. Eaton WA, Hofrichter J: Hemoglobin S gelation and sickle cell disease. *Blood* 70:1245–1266, 1989
9. Brajtbord D, Johnson D, Ramsay M: Use of the cell saver in patients with sickle cell trait. *ANESTHESIOLOGY* 70:878–879, 1989

Anesthesiology  
73:179–181, 1990

## Liquid Nitrogen Instillation Can Cause Venous Gas Embolism

DONNA M. DWYER, C.R.N.A.,\* ALISA C. THORNE, M.D.,†  
JOHN H. HEALEY, M.D.,‡ ROBERT F. BEDFORD, M.D.§

Cryosurgery utilizing instillation of liquid nitrogen is often employed to extend the surgical margin of excision in cancer operations. Liquid nitrogen boils at  $-195^{\circ}\text{C}$ , rapidly producing nitrogen bubbles at room temperature. Although intravascular embolization of gas bubbles is a recognized hazard whenever a gas is introduced into a body cavity under positive pressure,<sup>1–5</sup> we are unaware of any previous clinical reports describing the syndrome

of pulmonary gas embolism coincident with pouring liquid nitrogen into a surgical field. Recently, however, one of our patients developed signs suggestive of pulmonary gas embolism during such a procedure.

#### CASE REPORT

A 58-yr-old, 105-kg man with a 20 pack-yr history of tobacco use was scheduled to undergo curettage of a suspected intraosseous low-

---

\* Instructor, Columbia University School of Nursing.  
† Assistant Professor of Anesthesiology, Cornell University Medical College.  
‡ Assistant Professor of Orthopedic Surgery, Cornell University Medical College.  
§ Professor of Anesthesiology, Cornell University Medical College.  
Received from the Departments of Anesthesiology and Critical Care Medicine, the Orthopedic Service, Department of Surgery, Memorial Sloan-Kettering Cancer Center, New York, New York; the Columbia University School of Nursing, New York, New York; and Cornell Uni-

versity Medical College, New York, New York. Accepted for publication February 13, 1990.

Address reprint requests to Donna M. Dwyer, C.R.N.A.: Department of Anesthesiology and Critical Care Medicine, C-302, Memorial Sloan-Kettering Cancer Center, 1275 York Avenue, New York, New York 10021.

Key words: Anesthesia: orthopedic. Complications: embolism. Embolism: air. Measurement techniques: mass spectroscopy. Metabolism: nitrogen. Monitoring: carbon dioxide; tension. Surgery: cryotherapy; orthopedic.