

## Superior Hypogastric Plexus Block for Pelvic Cancer Pain

Ricardo Plancarte, M.D.,\* Cesar Amescua, M.D.,† Richard B. Patt, M.D.,‡ J. Antonio Aldrete, M.D.

Blockade of the superior hypogastric nerve plexus was performed for relief of chronic cancer related pelvic pain. The targeted sympathetic nerves lie anterior to the sacral promontory. Twenty-eight patients with neoplastic involvement of pelvic viscera secondary to cervical, prostate, and testicular cancer or radiation injury were treated with neurolytic superior hypogastric plexus block. Sympathetically mediated pain was significantly reduced or eliminated in all cases and no serious complications occurred. Superior hypogastric plexus block is recommended for diagnostic/prognostic and therapeutic purposes in patients with chronic pelvic pain, particularly when pain is of neoplastic origin. (Key words: Anesthetic techniques: hypogastric plexus block. Pain, intractable: pelvic neoplasms.)

INTERRUPTION of the sympathetic nervous system at the ganglionic level has long been employed to treat sympathetically mediated chronic pain of diverse etiologies.<sup>1,2</sup> Successful applications include management of pain of neoplastic and non-neoplastic etiology as well as pain of vascular and nonvascular origin.<sup>3</sup> Classically, the stellate ganglion (C6-T1), celiac plexus (T12-L1), and lumbar sympathetic chain (L2-L3) have been targeted to treat head, neck, and upper limb pain; upper abdominal and back pain; and lower extremity pain, respectively.<sup>1-3</sup> Various surgical techniques have been developed and used at each of these levels over the last 60 yr.<sup>4-7</sup> Over the last 35 yr percutaneous techniques for interrupting the sympathetic nervous system chemically with local anesthetics and neurolytic agents have been developed, again focusing at the above-mentioned levels of the sympathetic chain.<sup>1-3</sup> The advent of less-toxic and longer-acting anesthetic compounds, disposable needles, and fluoroscopic and, more recently, computerized tomographic guidance have enhanced the safety, precision, and efficacy of these techniques.

Little attention has been focused on interruption of the sympathetic nervous system at alternate sites to those described above. The superior hypogastric plexus is a retroperitoneal structure located bilaterally at the level of the lower third of the fifth lumbar vertebral body and upper third of the first sacral vertebral body at the sacral promontory and in proximity to the bifurcation of the common iliac vessels.<sup>8,9</sup> This plexus innervates the pelvic

viscera *via* the hypogastric nerves and surgical interruption of the hypogastric plexus (presacral neurectomy) relieves a variety of painful pelvic conditions.<sup>7,10</sup> The frequency of visceral pelvic pain in association with oncologic disease<sup>11,12</sup> served as a motivation for our group to devise a reliable percutaneous approach to blocking the nerves in this region.

### Methods

After informed consent was obtained, superior hypogastric plexus blocks were performed in 28 patients. There were twenty-two female patients and the mean age was 36. All patients had chronic lower abdominal pain with a prominent visceral component, secondary to advanced cancer (cervix = 20; prostate = 4; testicle = 1; postradiation cystitis = 1; postradiation enteritis and proctitis = 2). Pain had persisted in all patients despite appropriate, individualized standard interventions including radiotherapy, chemotherapy, nonopioid and opioid analgesics, and behavioral pain management.

Visual and oral analogue scales were used to measure pain immediately before and after the performance of hypogastric block, and from one-half hour, 1, 2, 4, 8, and 24 h postblock. Repeat measures of pain severity were performed monthly until each patient's death.

In two-thirds of patients, superior hypogastric block was preceded by a "single shot" L4-5 epidural injection of 8-10 ml 1% lidocaine to enhance patient cooperation. Epidural analgesia to a caudal level of L5 reduces reflex muscle spasm, ameliorates the discomfort associated with contact of needles with periosteum, and reduces patient movement. Alternatively, these goals can be achieved with local infiltration of the intervening muscle planes.

The patient assumes the prone position with padding placed beneath the pelvis to flatten lumbar lordosis. The lumbosacral region is cleansed aseptically. The location of the L4-L5 interspace is approximated by palpation of the iliac crests and spinous processes and is then verified by fluoroscopy. Skin wheals are raised 5-7 cm bilateral to the midline at the level of the L4-L5 interspace (fig. 1). A 7-inch, 22-G short-beveled needle with a depth marker placed 5-7 cm along the shaft is inserted through one of the skin wheals with the needle bevel directed toward the midline. From a position perpendicular in all planes to the skin, the needle is oriented about 30 degrees caudad and 45 degrees mesial so that its tip is directed toward the anterolateral aspect of the L5 vertebral body (fig. 2). The iliac crest and the transverse process of L5, which is sometimes enlarged, are potential barriers to

\* Chairman, Department of Anesthesia, Intensive Care and Pain Therapy, National Institute of Cancer. Professor of Anesthesiology, Universidad Nacional Autonoma de Mexico, Mexico City, Mexico.

† Assistant Professor, Universidad Nacional Autonoma de Mexico, Mexico City, Mexico.

‡ Medical Director, Pain Treatment Center. Associate Professor of Anesthesiology and Psychiatry, University of Rochester School of Medicine and Dentistry, Rochester, New York.

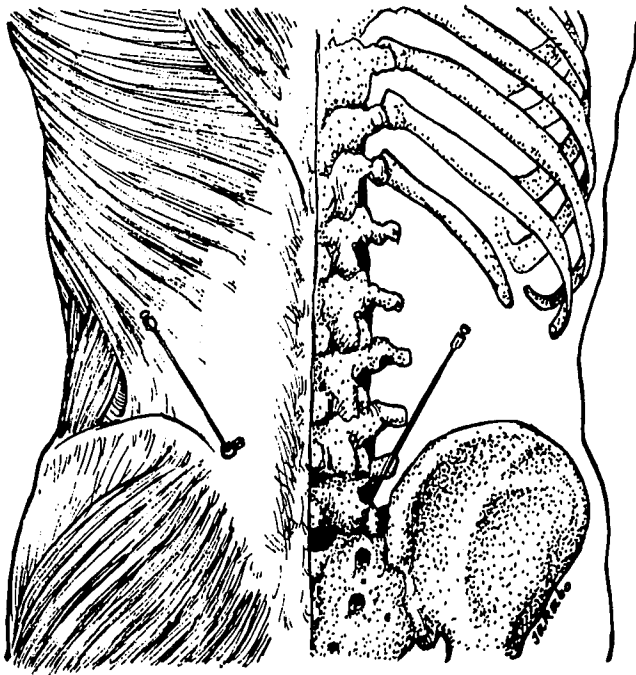


FIG. 1. Posterior view illustrating approximate placement of skin wheals, needle trajectory, and relationship among needle path, iliac crest, and fifth lumbar transverse process.

needle passage, and necessitate the use of the cephalolateral entrance site and oblique trajectory described. If the transverse process of L5 is encountered during advancement of the needle, the needle is withdrawn to the subcutaneous tissue and is redirected slightly caudad or cephalad. The needle is readvanced until the body of the L5 vertebra is encountered or until its tip is observed fluoroscopically to lie at its anterolateral aspect. If the vertebral body is encountered, cautious effort may be made to further advance the needle. If this is unsuccessful

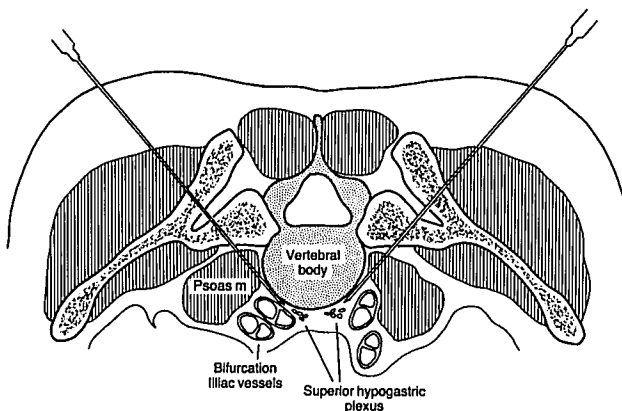


FIG. 2. Cross-sectional view of correct needle placement, illustrating needle's relationship to fifth lumbar vertebra, psoas muscle, and iliac vessels.

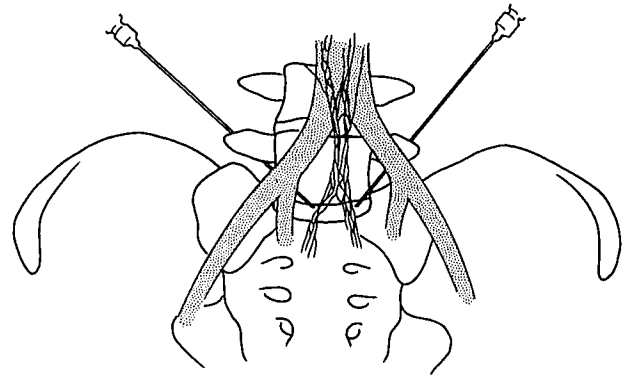


FIG. 3. Anterior view of pelvis illustrating location of hypogastric plexus and correct bilateral needle placement.

the needle is withdrawn and, without altering its cephalocaudal orientation, it is redirected in a slightly less mediad plane so that its tip is "walked off" the vertebral body. The needle tip is advanced about 1 cm past the vertebral body, at which point a loss of resistance or "pop" may be felt indicating that the needle tip has traversed the anterior fascial boundary of the ipsilateral psoas muscle and lies in the retroperitoneal space (figs. 2 and 3). At this point the depth marker should, depending on the patient's body habitus, lie close to the level of the skin. The con-

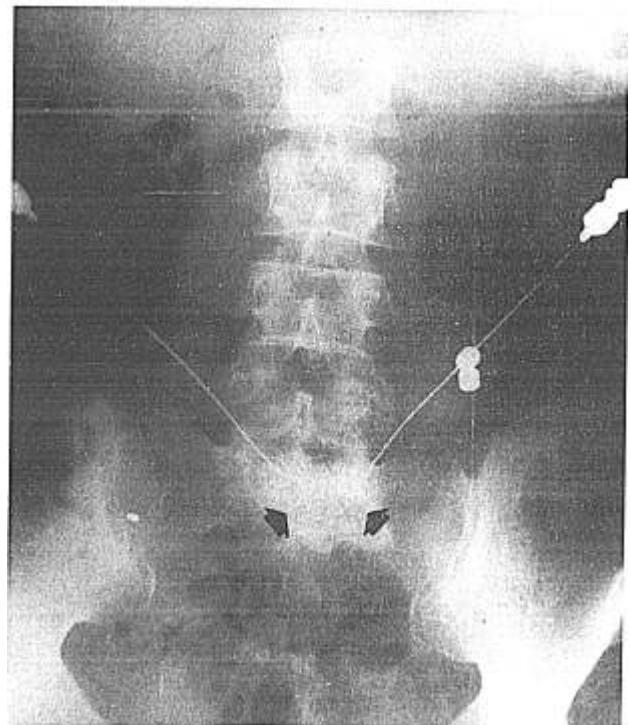


FIG. 4. PA radiograph demonstrating correct needle placement. Arrows indicate contrast medium (3-4 ml injected bilaterally) confined to midline.

tralateral needle is inserted in a similar manner, using the trajectory and depth of the first needle as a rough guide.

Biplanar fluoroscopy is used during needle passage and to verify accurate needle placement. Anterior-posterior (AP) views should demonstrate the needle tip's location at the level of the junction of the L5 and S1 vertebral bodies (fig. 4), and lateral views will confirm placement of the needle tip just beyond the vertebral body's anterolateral margin (fig. 5). The injection of 3–4 ml of water-soluble contrast medium further verifies the accuracy of needle placement. In the AP view, the spread of the contrast media should be confined to the midline region (fig. 4). In the lateral view, a smooth posterior contour corresponding to the anterior psoas fascia indicates that needle depth is appropriate (fig. 5). Alternatively, computerized axial tomography may be used, permitting visualization of vascular structures.

Additional precautions include careful aspiration prior to injection and the use of "test" doses of local anesthetic.

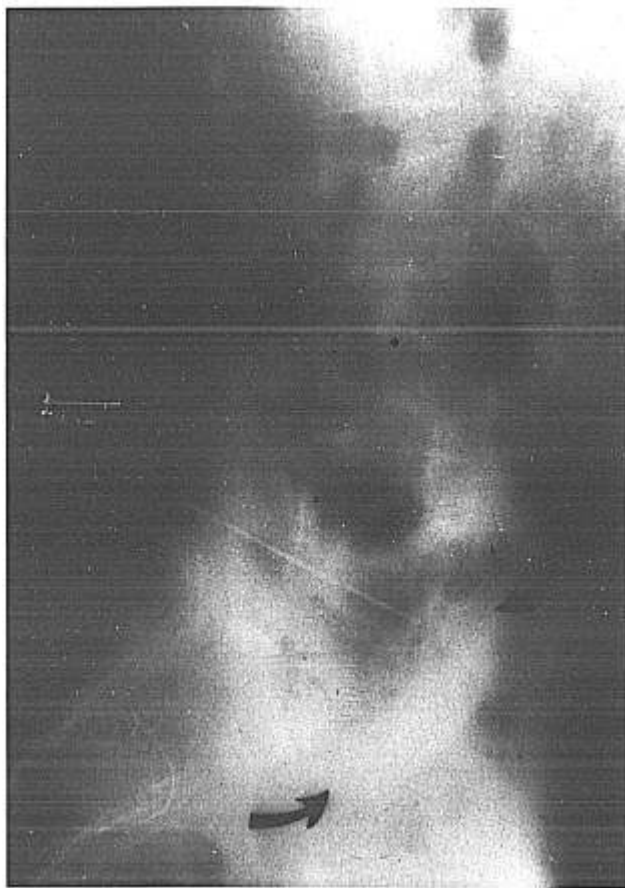

FIG. 5. Lateral radiograph demonstrating correct needle placement. Arrows indicates superior and anterior margins of opacity formed by contrast medium (3–4 ml). Note smooth anterior and posterior margins of spread of dye suggesting retroperitoneal placement anterior to the psoas muscle.

Vascular puncture carries the risk of subsequent hemorrhage and hematoma formation due to the close proximity of the bifurcation of the common iliac vessels. Intramuscular or intraperitoneal injection may result from an improper estimate of needle depth. These and less likely complications (subarachnoid and epidural injection, somatic nerve injury, renal or ureteral puncture) can usually be avoided by careful adherence to technique.

Hypogastric plexus blockade is used for either diagnostic/prognostic or therapeutic purposes. In the former case, a volume of 6–8 ml 0.25% bupivacaine through each needle is recommended. For therapeutic (neurolytic) blocks our group favors the use of a total of 6–8 ml 10% aqueous phenol through each needle. During manufacture, a small amount of glycerine is added to keep the phenol in solution.

### Results

Using visual and oral analogue scales, a mean reduction in pain of 70% was observed, and residual pain seemed generally to be of somatic origin. Injections of epidural steroids, serial injections of 2–3% epidural phenol and/or the oral administration of nonopioid analgesics were used to control the remaining somatic component of pain, resulting in a global reduction in pain scores of 90%. In all but two patients with pain due to neoplasm, there was no return of sympathetically mediated symptoms until their demise (3–12 months).

In two patients with pain of neoplastic origin sympathetically mediated symptoms recurred 2 weeks postblock. Significant retroperitoneal spread of tumor was present in both of these patients, and presumably interfered with the free spread of the neurolytic agent. In both cases, superior hypogastric plexus block was repeated under CT guidance resulting in relief of sympathetically mediated pain until their deaths 2 and 4 months later.

In the three patients with pain related to complications of radiotherapy, symptoms have not recurred at 2-yr follow up.

### Discussion

Cancer pain control and maintenance of an enhanced quality of life in preterminal patients remains a therapeutic challenge. Pain from pelvic cancer is particularly difficult to manage because it is often vague and poorly localized and tends to be bilateral or to cross the midline. Further, nerve blocks in this region are hazardous because sensory afferents from the pelvic viscera are in close proximity to nerves regulating bowel and bladder function as well as to those supplying motor strength to the lower extremities.

Comprehensive pharmacologic management is regarded as the mainstay of care for most patients with can-

cer pain. Investigators have reported significant relief from cancer pain in 75% of patients treated aggressively with oral pharmacologic agents alone, and the proportion of successful treatment would be expected to be increased with the addition of subcutaneous and iv opioid therapy.<sup>13-15</sup> Nevertheless, despite pharmacologic intervention, a variable proportion of patients either do not achieve adequate control of pain or experience intractable side effects associated with analgesics and are candidates for nonpharmacologic intervention. Intraspinal opioid therapy, a relatively new therapeutic option, may be beneficial in selected patients with pelvic pain that has been refractory to conventional pharmacologic management. The utility of chronic intraspinal opioid therapy is potentially limited by factors that include uneven availability of the technology required for its institution and maintenance, high cost, the inevitable development of tolerance, and ineffectiveness in a proportion of patients.

Of the various neurosurgical operations developed to control cancer pain, only percutaneous cordotomy is still used commonly.<sup>16</sup> Cordotomy produces analgesia that is strictly unilateral and on that basis represents a poor choice for the treatment of pelvic pain. Bilateral cordotomy has been almost universally abandoned because of the high associated risk of fatal sleep apnea.<sup>16</sup>

Nerve blocks have an important historic and contemporary role in cancer pain management, and several different techniques of neurolytic blockade have been used to manage neoplastic pelvic pain of visceral origin. Intrathecal injections of alcohol and phenol have been employed, but even with meticulous attention to technique are associated with the risk of bladder, bowel, and lower extremity paresis.<sup>1</sup> Bilateral lumbar sympathetic block has the potential to relieve pelvic pain with little risk of unwanted neurologic deficit.<sup>1</sup> The lumbar sympathetic chain does not directly innervate pelvic structures but due to its continuity with the superior hypogastric plexus, large volumes of injectate probably diffuse caudally resulting in relief of pelvic pain. Superior hypogastric block would therefore seem to be a superior alternative for the treatment of pelvic pain because of its greater specificity. Caudal spread may be inconsistent after lumbar sympathetic block, particularly if the retroperitoneum is invaded by tumor, and the temptation to use large volumes of drug to facilitate caudal spread is absent when superior hypogastric block is selected.

Anesthetic blockade of the superior hypogastric plexus is a viable therapeutic alternative for intractable chronic pelvic pain of neoplastic origin. Using fluoroscopic guidance, the technique described has produced reliable preliminary results in 28 patients with pain of neoplastic origin and was not associated with significant side effects or complications.

### References

1. Bonica JJ: The management of pain of malignant disease with nerve blocks. *ANESTHESIOLOGY* 15:134-145, 1954
2. Thompson GE, Moore DC, Bridenbaugh LD, Artin RY: *Anesth Analg* 56:1-5, 1977
3. Bonica JJ: Autonomic innervation of the viscera in relation to nerve block. *ANESTHESIOLOGY* 29:793-813, 1968
4. Takats DE, Walter LE, Lasner J: Splanchnic nerve section for pancreatic pain. Second report. *Ann Surg* 131:44-57, 1950
5. Smithwick RH: Lumbar sympathectomy in the treatment of obliterative vascular disease of the lower extremities. *Surgery* 42: 415-430, 1957
6. Mixer WJ, White JC: Pain pathways in the sympathetic nervous system, clinical evidence. *Arch Neurol Psychiatry* 25:986-997, 1931
7. Lee RB, Stone K, Magelssen, Belts RP, Benson WL: Presacral neurotomy for chronic pelvic pain. *Obstet Gynecol* 68:517-521, 1986
8. Pitkin G: The Autonomic Nervous System, in Pitkin's Conduction Anesthesia, second edition. Edited by Southworth JL, Hingson RA, Pitkin WM. Philadelphia, J.B. Lippincott Co., 1953, pp. 189-276
9. Snell RS, Katz J: *Clinical Anatomy for Anesthesiologists*. Norwalk, Appleton and Lange, 1988, p. 271
10. Frier A: Pelvic neurectomy in gynecology. *Obstet Gynecol* 25: 48-55, 1965
11. Wang JK: Intrathecal morphine for intractable pain secondary to pelvic cancer of pelvic organs. *Pain* 21: 99-102, 1985
12. Ischia S, Luzzani A: Subarachnoid neurolytic block (L5-S1) and unilateral percutaneous cervical cordotomy in the treatment of pain secondary to pelvic malignant disease. *Pain* 20:139-150, 1984
13. Warfield CA: Evaluation of dosing guidelines for the use of oral controlled-release morphine (MS Contin tablets). *Cancer* 63: 2360-2364, 1989
14. Bruera E, Brenneis C, Michaud M, Chadwick S, MacDonald RN: Continuous SC infusion of narcotics using a portable device in patients with advanced cancer. *Cancer Treatment Report* 71: 635-637, 1987
15. Kerr IG, Sone M, DeAngelis C, Iscoe N, MacKenzie R, Schueller T: Continuous narcotic infusion with patient-controlled analgesia for chronic cancer pain in outpatients. *Ann Int Med* 108: 554-557, 1988
16. Patt R, Jain S: Recent advances in the management of oncologic pain. *Curr Probl Cancer* 13:131-195, 1989