

Fatal Venous Air Embolism Following Sequential Unsheathed (Bare) and Sheathed Quartz Fiber Nd:YAG Laser Endometrial Ablation

ROBERT C. CHALLENGER, M.D.,* BENJAMIN KAUFMAN, M.D.†

Laser endometrial ablation, an outpatient procedure that permits resumption of routine activities in 2 or 3 days, is considered a low-risk alternative to hysterectomy for dysfunctional uterine bleeding.^{1‡} Complications attributable to ablation include pulmonary edema due to fluid overload and postoperative bleeding.²⁻⁴ The potential for venous air embolism has been recognized,^{1,5} and two cases of fatal venous air embolism associated with the use of synthetic sapphire tips have been reported.⁶ We report a case of fatal air embolism that occurred during laser endometrial ablation when a sheathed quartz fiber was used to complete the ablation after the unsheathed (bare) quartz fiber had become inoperative.

CASE REPORT

A 76-kg, 42-yr-old woman with an 8-yr history of menorrhagia and two previous endometrial curettages elected to undergo laser endometrial ablation. Her medical history included three cesarean sections, the last followed by bilateral subtotal salpingectomies. Current medications included iron, trifluoperazine, amoxapine, and benzotropine mesylate. Physical and laboratory examinations were unremarkable.

After insertion of an 18-G intravenous catheter and application of ECG electrodes, blood pressure cuff, and pulse oximetry probe, anesthesia was induced with 1 mg midazolam hydrochloride iv followed by 375 mg sodium thiopental and 50 mg atracurium besylate. The trachea was intubated atraumatically with a 7-mm endotracheal tube, and the cuff was inflated with 5 ml air. Breath sounds were present bilaterally, and mechanical ventilation was begun with a tidal volume of 800 ml at 8 respirations per min. Anesthesia was maintained with nitrous oxide (3 l/min), oxygen (2 l/min), and enflurane 2.5%. End-tidal CO₂ was monitored. To avoid the risk of accidental retinal damage by the laser beam, protective goggles with yellow-green-tinted lenses were worn by the patient and all operating room personnel.

Under satisfactory anesthesia, the patient was placed in lithotomy

position with her head slightly down. Bimanual examination revealed an anteverted, anteфлекed, normal-sized uterus and adnexa. The cervix was dilated to 25 mm, and the Storz hysteroscope with video display inserted. Intermittent, nonforceful injections of saline from a 50-ml syringe connected to the hysteroscope by tubing were used to distend and irrigate the uterus. The endometrium appeared hypertrophic. Using an unsheathed (bare) quartz fiber and the Heraeus Laser Sonics neodymium:yttrium-aluminum-garnet (Nd:YAG) laser model 8000 set at 50 W, blanching of the fundal endometrium was begun.

Approximately 1 h after induction of anesthesia and 50 min after beginning the procedure, the patient began to cough. When the anesthesiologist removed his laser-protective goggles, he observed deep cyanosis of the face and chest. The fingers and lower extremities did not appear cyanotic. The patient's blood pressure was 103/76, heart rate (on ECG) 48 bpm, hemoglobin oxygen saturation (SpO₂) 97%, and end-tidal CO₂ 39 mmHg. Anesthesia was immediately discontinued, surgery halted, 100% oxygen administered, and manually assisted ventilation begun. Breath sounds were audible bilaterally. Cyanosis persisted, and blood pressure and heart rate continued to decrease. Cardiopulmonary resuscitation was begun, but 18 min later, after vital signs did not respond to external cardiac massage and repeated intravenous administrations of sodium bicarbonate, epinephrine, ephedrine, atropine, and dopamine, the possibility of venous air embolism was considered. After insertion of a right subclavian central venous catheter, air was aspirated. However, vital signs remained unresponsive to resuscitation and efforts to revive the patient were discontinued after 35 min of resuscitation.

Eye donation was requested, and with the consent of the family and approval of the Coroner's Office, the eyes were enucleated. Percutaneous needle aspiration of cardiac blood was performed to obtain a sample for serologic testing before contemplated corneal transplantation.

Radiographs of the chest and abdomen were obtained prior to postmortem examination (*vide infra*). Significant anatomic findings at autopsy included subcutaneous emphysema, pneumopericardium, and air in the right atrium.

Preautopsy radiographs (figs. 1 and 2) demonstrated a central venous catheter in the superior vena cava extending into the right atrium. Subcutaneous air was visible in the right axillary region, right lateral chest wall, and pectoralis musculature. Air was present also in the pericardial sac, all four cardiac chambers, and aorta. An air-filled vascular structure (possibly the aorta or inferior vena cava, or both) was visualized overlying the first two lumbar vertebrae. The portal vein and intrahepatic vessels contained air, and there appeared to be free abdominal subhepatic air. The tracheal air shadow was midline, and pneumothorax and mediastinal shift were absent.

DISCUSSION

Despite its massive volume, the source of the air embolism was not immediately apparent. Subsequent discussions with surgical and anesthesia personnel disclosed that the original unsheathed (bare) fiber had become in-

* Cuyahoga County Coroner's Office and Assistant Professor, Department of Pathology, Case Western Reserve University School of Medicine, Cleveland, Ohio.

† Department of Radiology, University Hospitals of Cleveland; Consultant in Forensic Radiology, Cuyahoga County Coroner's Office; and Professor of Radiology, Case Western Reserve University School of Medicine, Cleveland, Ohio.

Received from the Cuyahoga County Coroner's Office, Cleveland, Ohio. Accepted for publication April 28, 1990.

Address for reprint requests to Dr. Challenger: Cuyahoga County Coroner's Office, 2121 Adelbert Rd., Cleveland, Ohio 44106.

Key words: Embolism, air. Surgery, endometrial ablation: Nd:YAG laser.

‡ Lomano JM: Laser hysteroscopy: New benefits, new risks. Contemporary OB/GYN 32: 71-82, 1988

FIG. 1. Recumbent anterior-posterior x-ray view of the chest and abdomen shows extensive air within the right atrium (RA), right ventricle (RV), main pulmonary artery (MPA), aorta (A), and pericardial space (PS). The left ventricular wall (LVW) is contrasted by air in the pericardial space and within the left ventricle. Left ventricular air is difficult to appreciate since it is behind the air-filled right ventricle. The left hepatic vein (LHV) and portal vein (PV) are seen as air-filled tubular vessels. Intrahepatic vessels, arterial or venous, contain air and are seen throughout the liver (arrowheads). The tip of a subclavian catheter is seen in the right atrium. Air is streaked throughout the right pectoralis muscle and is also in the subcutaneous tissue of the right chest wall.

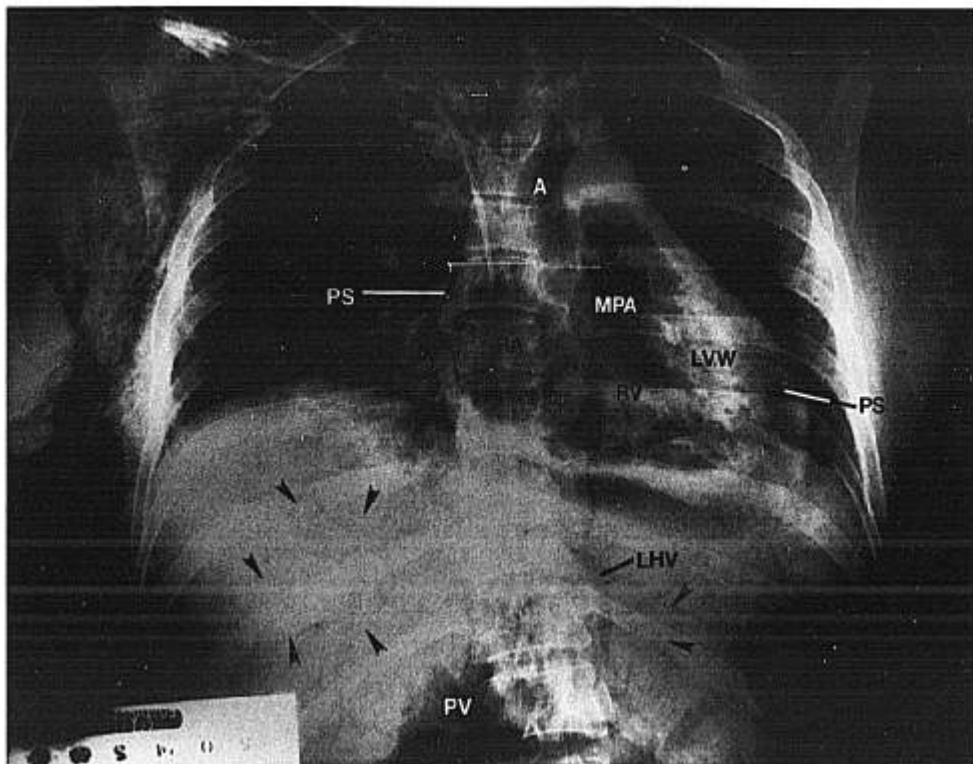
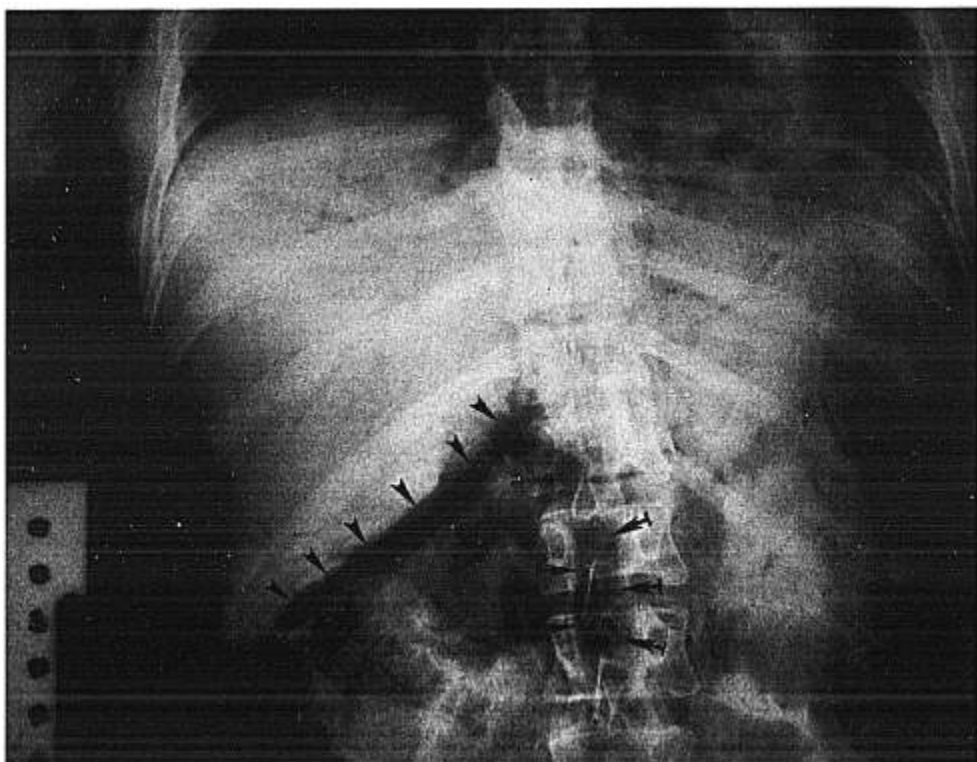


FIG. 2. Recumbent anterior-posterior x-ray view of the abdomen shows free air in the subhepatic region (arrowheads). An air-filled large vascular structure, indicated by the tufted arrows, represents the inferior vena cava or the aorta, which may be superimposed at this level.



operative, and in order to complete the ablation procedure, a sheathed fiber had been substituted. Moments later the patient coughed and was deeply cyanotic.

Quartz fiber, synthetic sapphire tip, and Nd:YAG laser design. Light emitted by the Nd:YAG laser is delivered to tissue through flexible fibers composed of a quartz core surrounded by silicone rubber cladding and a Teflon® cover.⁷ This fiber may be unsheathed (bare) or sheathed. The sheath is a larger diameter polyethylene catheter that serves as a coaxial conduit to deliver gas (air, carbon dioxide, nitrogen) or fluid to the fiber tip. The gas or fluid cleanses and cools the tip. Whereas the unsheathed fiber may be used in direct contact with tissue, the sheathed fiber is intended only for noncontact applications. Tissue contact by either fiber results in deposition of protein on the quartz fiber tip. Charring of protein causes overheating and melting of the quartz tip, rendering the fiber inoperative.

Sheathed quartz fibers equipped with synthetic sapphire tips allow contact irradiation. The tips attach to the fibers by universal metal connectors. Cooling gas or fluid, delivered through the fiber sheath, escapes from holes in the metal connector, preventing thermal damage to the synthetic sapphire tip. Contact probes prevent backscattering of laser light and reduce the depth of tissue damage, allowing much lower powers of laser energy to be used.⁷ However, because of reduced depth of tissue injury, synthetic sapphire contact probes have not proven satisfactory for endometrial ablation. §

Because of significant unit cost, Nd:YAG lasers are designed for applications with both unsheathed and sheathed fibers. The Heraeus Laser Sonics Nd:YAG laser model 8000 supplies a variable volume of compressed air (or gas) to sheathed fibers. Information concerning volume and pressure of air (or gas) delivered is available from the manufacturer. The volume of air (or gas) escaping at the fiber tip depends on the relative diameters of the quartz fiber and polyethylene sheath and the setting of the volume regulator.

Portal of entry and distribution of air (or gas). Complete or partial ablation of the endometrium injures large numbers of uterine vessels. Rapid absorption of irrigating fluid during endometrial ablation (average volume of absorbed fluid 894–2,122 ml, depending on technique³) indicates that uterine venous sinuses are not occluded by laser injury.

In our case, after subtotal ablation of the endometrium, the unsheathed fiber became inoperative and was replaced with a sheathed fiber attached to a compressed air source.

Reinsertion of the hysteroscope delivered compressed air to the endometrial cavity. Air entered the uterine venous sinuses, and moments later the patient coughed and was deeply cyanotic. The air volume and pressure at which it was delivered are unknown.

The air flowed directly into the inferior vena cava and thence to the right heart. Anastomoses of the uterine, vaginal, and rectal venous plexuses delivered the offending gas to the portal vein and its intrahepatic branches. Subcutaneous emphysema (right axillary region, lateral chest wall, and pectoralis musculature) developed when cardiopulmonary resuscitation caused air to track along the right subclavian central venous catheter. Postmortem percutaneous needle aspiration of heart blood, necessitated by eye donation, allowed air within the heart to enter the pericardial sac. The route by which air reached the left heart and aorta remains speculative. Foramen ovale patency was not observed.

We have no explanation for the normal readings of blood pressure, heart rate, SpO₂, and expired CO₂ when the patient coughed and central cyanosis was discovered. A sudden, steep decrease in end-tidal CO₂ together with circulatory collapse should be observed in the presence of a massive venous air embolism.

Comment. There are few references in the Nd:YAG laser endometrial ablation medical literature that specifically warn of gas embolism.^{1,5} The American National Standards for the Safe Use of Lasers in Health Care Facilities (ANSI Z136.3-1988) ¶ notes the danger of using gas to distend the bladder and urethra but does not mention the risk of venous air embolism during endometrial ablation.

To our knowledge, this is the third reported fatality during Nd:YAG laser endometrial ablation due to gas embolus. In each instance, a sheathed quartz fiber was used to deliver laser light to the endometrium. In two previously published cases,⁶ the sheathed fibers were equipped with synthetic sapphire tips cooled in one case by nitrogen and in the other by air. These gases were responsible for embolism. In our case, fatal embolism occurred when a sheathed fiber cooled with compressed air was substituted for an unsheathed fiber that had become inoperable after subtotal endometrial ablation. Clearly, gases of any sort should never be used when sheathed fibers are employed in conjunction with the Nd:YAG laser for intrauterine surgery.

For critical review of the clinical records and manuscript, the authors gratefully acknowledge the assistance of Helmut F. Cascorbi, M.D.,

§ Zumwalt T, Wesseler T, Joffe SN: A comparison of artificial sapphire tip with the quartz tip: In *In vitro* endometrial ablation. *Colposcopy & Gynecologic Laser Surgery* 2: 47–51, 1986

¶ American National Standards Institute: *Safe Use of Lasers in Health Care Facilities*, Z136.3, New York, American National Standards Institute, 1988, pp 29–31 and pp 36–38

Ph.D., Director, Department of Anesthesiology, University Hospitals of Cleveland and Professor and Chairman, Department of Anesthesiology, Case Western Reserve University School of Medicine. The authors also are indebted to Msrs. Joseph Collins and James Wentzel of the Cuyahoga County Coroner's Photography Department for preparation of figures 1 and 2.

REFERENCES

1. Zumwalt T: Endometrial ablation, *Advances in Nd:YAG Laser Surgery*. Edited by Joffe SN, Oguro Y. New York, Springer Verlag, 1988, pp 192-199
2. Goldrath MH: Hysteroscopic laser surgery, *Basic and Advanced Laser Surgery in Gynecology*. Edited by Baggish MS. Norwalk, Ct., Appleton-Century-Croft, 1985, pp 357-372
3. Lomano JM: Dragging technique *versus* blanching technique for endometrial ablation with the Nd:YAG laser in the treatment of chronic menorrhagia. *Am J Obstet Gynecol* 159:152-155, 1988
4. Loffer FD: Hysteroscopic endometrial ablation with the Nd:YAG laser using a nontouch technique. *Obstet Gynecol* 69:679-682, 1987
5. Baggish MS: New laser hysteroscope for Neodymium-YAG endometrial ablation. *Lasers Surg Med* 8:99-103, 1988
6. Baggish MS, Daniell JF: Death caused by air embolism associated with neodymium:yttrium-aluminum-garnet laser surgery and artificial sapphire tips. *Am J Obstet Gynecol* 161:877-888, 1989
7. Joffe SN, Applications in gastrointestinal bleeding, *Lasers in General Surgery*, Edited by Joffe SN. Williams and Wilkins, Baltimore, 1989, pp 173-183

Anesthesiology
73:551-553, 1990

Hypercapnia During Laser Arthroscopy of the Knee

JOHN G. GOODE, M.D.,* ROBERT Y. GUMNIT, M.D.,† WARREN D. CAREL, M.D.,‡
MICHAEL MCKENNA, B.S.N., R.N.§

Surgical arthroscopy of the knee is conventionally done with surgical instruments in a fluid medium. After testing in animal and human models, laser arthroscopy of the human knee in a gas medium was described as early as 1983.¹ To the best of our knowledge, hypercapnia associated with laser arthroscopy of the knee has not previously been reported.

CASE REPORTS

Case 1

An obese 35-yr-old, 82-kg woman with the diagnosis of internal derangement of the knee presented for surgical arthroscopy. Anesthesia

* Staff Anesthesiologist, Mt. Sinai Hospital, Philadelphia, Pennsylvania, and Clinical Assistant Professor of Anesthesia, University of Pennsylvania School of Medicine, Philadelphia, Pennsylvania.

† Staff Anesthesiologist, Mt. Sinai Hospital, Philadelphia, Pennsylvania, and Clinical Assistant Professor of Anesthesia, University of Pennsylvania School of Medicine, Philadelphia, Pennsylvania.

‡ Chairman, Department of Anesthesia, Mt. Sinai Hospital, Philadelphia, Pennsylvania, and Clinical Assistant Professor of Anesthesia, University of Pennsylvania School of Medicine, Philadelphia, Pennsylvania.

§ Operating Staff Nurse and Laser Safety Officer, Mt. Sinai Hospital, Philadelphia, Pennsylvania.

Received from Mt. Sinai Hospital, Philadelphia, Pennsylvania. Accepted for publication March 28, 1990.

Address reprint requests to Dr. Goode: Department of Anesthesia, The Graduate Hospital, One Graduate Plaza, Philadelphia, Pennsylvania 19146.

Key words: Carbon dioxide; hypercapnia. Complications: pneumoperitoneum, subcutaneous emphysema.

was induced with a combination of fentanyl, thiopental, and succinylcholine. Isoflurane and vecuronium were used in conjunction with nitrous oxide for maintenance of anesthesia. Thirty minutes after the initiation of CO₂ insufflation and during arthroscopy tachycardia, hypertension and increased end-tidal carbon dioxide tension (ET_{CO₂}) from 29 to 76 mmHg (measured with a Nellcor Multi-Function Monitor) developed over 3-4 min. The patient's lungs initially were being ventilated mechanically *via* an endotracheal tube at a minute ventilation of 6.4 l/min (tidal volume = 800 ml, respiratory rate = 8). Increased minute ventilation first mechanically and then manually to 20 l/min (tidal volume = 1000 ml, respiratory rate = 20) only decreased the ET_{CO₂} to 58 mmHg.

The abdomen was noted to be acutely distended and the peak inspiratory pressure increased to greater than 60 cm H₂O. Delivery of 100% O₂ increased the O₂ saturation from 95 to 99%. A nasogastric tube did not relieve the abdominal distention. The ET_{CO₂} remained increased until CO₂ insufflation ceased at which time the ET_{CO₂} tension returned to normal over approximately 15 min. The abdominal distention resolved over the same time period and retrospectively was probably secondary to a pneumoperitoneum. The trachea was extubated and the patient had an uneventful postoperative course.

Case 2

A 41-yr-old, 55-kg woman presented for surgical arthroscopy of the knee. She had been healthy previously except for a history of mitral valve prolapse. Anesthetic management was similar to that of case 1. Twenty minutes after initiation of CO₂ insufflation and during arthroscopy, hypertension and tachycardia developed, associated with marked generalized subcutaneous emphysema and increase of the ET_{CO₂} from 30 to 90 mmHg over 3-4 min. This patient's lungs were similarly being ventilated mechanically *via* an endotracheal tube at a minute ventilation of 5.6 l/min (tidal volume = 700 ml, respiratory rate = 8, peak inflating pressure = 20 cm H₂O). Increasing the minute ventilation first mechanically and then manually to 15 l/min (tidal volume = 600 ml, respiratory rate = 25) only minimally decreased the