

The drug may be of particular benefit in children when autologous donation and subsequent transfusion is not possible, and when heterologous transfusion is to be avoided. The optimal dose of the drug will need to be defined in this population where anemia is not the reason for its use.

REFERENCES

1. Benson, KT: The Jehovah's Witness patient: Considerations for the anesthesiologist. *Anesth Analg* 69:647-656, 1989
2. Egrie, JC, Strickland TW, Lane J, Aoki K, Cohen AM, Smalling R, Trail G, Kin FK, Browne JK, Hines DK: Characterization and biological effects of recombinant human erythropoietin. *Immunobiology* 172:213-224, 1986
3. Eschbach JW, Egrie JC, Downing MR, Browne JK, Adamson JW: Correction of the anemia of end stage renal disease with recombinant human erythropoietin. *N Engl J Med* 316:73-78, 1987
4. Graber SE, Krantz SB: Erythropoietin and the control of red cell production. *Ann Rev Med* 29:51-66, 1978
5. Christensen RD: Recombinant erythropoietic growth factors as an alternative to erythrocyte transfusion for patients with "anemia of prematurity". *Pediatrics* 83:793-796, 1989
6. Zanjani ED: Liver to kidney switch of erythropoietin production. *Exp Hematol* 8:29-40, 1980
7. Goodnough LT, Rudnick S, Price TH, Ballas SK, Collins ML, Crowley JP, Kosmin M, Kruskall MS, Lenos BA, Menitove JE, Silberstein LE, Smith KJ, Wallas CH, Abels R, Tress MV: Increased preoperative collection of autologous blood with recombinant human erythropoietin therapy. *N Engl J Med* 321:1163-1168, 1989
8. Rhondeau SM, Christensen RD, Ross MP, Rothstein G, Simmons MA: Responsiveness to recombinant human erythropoietin of marrow erythroid progenitors from infants with the "anemia of prematurity". *J Pediatr* 112:935-940, 1988
9. DePalma L, Luban NLC: Autologous blood transfusion in pediatrics. *Pediatrics* 85:125-128, 1990

Anesthesiology
73:570-572, 1990

Anesthetic Implications of Relapsing Polychondritis: A Case Report

FREDERICK W. BURGESS, PH.D., M.D.,* WARREN WHITLOCK, M.D.,†
M. JEFF DAVIS, M.D.,* PAUL S. PATANE, M.D.*

Relapsing polychondritis is a rare inflammatory disorder of uncertain etiology. It is characterized by progressive destruction of cartilaginous structures.^{1,2} Presenting symptoms are variable, but frequently involve inflammation and destruction of the ears, nasal cartilage, and ocular and tracheobronchial support structures. Symptomatic tracheobronchial involvement is a poor prognostic indicator and frequently represents significant intra- and extrathoracic tracheal obstruction. In this report, we present the details surrounding the anesthetic management of a patient with relapsing polychondritis and provide a review of the current literature.

Received from the *Anesthesiology and Operative Service, Department of Surgery, and the †Pulmonary Disease Service, Department of Medicine, Letterman Army Medical Center, Presidio of San Francisco, California 94129-6700.

Accepted for publication April 28, 1990.

The opinions or assertions contained herein are the private views of the authors and are not to be construed as official or as reflecting the views of the Department of the Army, the Department of Defense, or the U. S. Government.

Address reprint requests to Dr. Burgess: Anesthesiology Service, Department of Surgery, Madigan Army Medical Center, Tacoma, Washington 98431-5055.

Key words: Relapsing Polychondritis; Anesthesia; Tracheomalacia.

CASE REPORT

A 34-yr-old white man, who weighed 74 kg and was 175 cm tall, had a history of relapsing polychondritis and was referred to our service for preoperative consultation before elective reconstructive surgery of his saddle-nose deformity. Relapsing polychondritis was diagnosed at age 23 yr and had been well controlled with intermittent steroid and azathioprine therapy. His disease remained in remission during treatment with oral prednisone, 17.5 mg once daily. His medical history was significant for severe dyspnea on strenuous exertion (running), tolerance of lower levels of activity (swimming), and bilateral hearing loss. One year earlier, he was hospitalized with stridorous respirations and wheezing associated with an upper respiratory tract infection.

Previous evaluation (February 1988) of his pulmonary function revealed a pattern consistent with severe obstruction. His vital capacity was 4.25 l, 82% of predicted, and forced volume in 1 s 1.58 l, 49% of predicted. The flow-volume loop (fig. 1) was consistent with a fixed airflow obstruction (tracheal stenosis), with limitation of air flow during both phases of the ventilatory cycle. Maximal voluntary ventilation was severely reduced, measuring 34% of predicted. Computerized tomography of the cervical and thoracic regions showed normal airway caliber without evidence of an obstructing mass or stenosis. Fiberoptic bronchoscopy revealed severe tracheomalacia with dynamic extrathoracic tracheal collapse on inspiration, and dynamic intrathoracic tracheal and left mainstem bronchial collapse on forced expiration. There was no evidence of a fixed tracheal stenosis.

Physical examination revealed a healthy-appearing man in no apparent distress. Notable physical findings included an obvious saddle-nose deformity and thickened and deformed ears. There was a mild pectus excavatum deformity. He had no stridor, wheezing, or other evidence of ventilatory compromise. The remainder of the physical

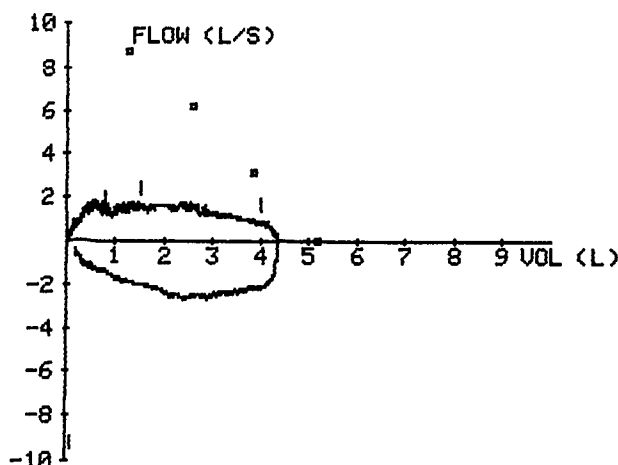


FIG. 1. Flow volume loop shows severe inspiratory and expiratory airflow obstruction, consistent with a fixed tracheal lesion. The squares mark predicted expiratory flows.

the upright and supine positions to evaluate his trachea. There was neither evidence of subglottic tracheal stenosis nor any significant change in dynamic airway closure in the upright or supine positions while awake, compared to his previous bronchoscopy 1 yr earlier.

DISCUSSION

Relapsing polychondritis is a rare inflammatory disorder, often presenting with multi-organ system involvement. The disorder classically presents as episodic erythema, pain, and swelling of the ears, nasal cartilage, and joints.¹ The relapsing course commonly results in progressive destruction and remodeling of the supporting collagen matrix, leading to the characteristic saddle-nose and cauliflower-ear deformities seen in our patient.

Cardiovascular system abnormalities, including cardiac valvular disorders, aneurysmal dilatation of the great vessels, and a systemic vasculitis, all have been described with relapsing polychondritis.^{1,2,3-5} Aortic and mitral valve regurgitation have been attributed to dilatation of the aortic root and mitral valve annulus.³⁻⁵ Unfortunately, valve replacements do not fare well.^{4,5} This may be related to progression of the underlying connective tissue degeneration, predisposing the implanted valve to failure. Polychondritis, although rarely encountered by the anesthesiologist, is a disease with great potential for life-threatening complications in the operating room.

Respiratory compromise resulting in patient demise from laryngotracheal collapse appears as a recurring theme in the numerous case reports scattered throughout the medical and surgical literature.⁶⁻⁸ Studies on the impact of relapsing polychondritis on pulmonary function show that approximately 50% of patients with this disease have ventilatory impairment.^{2,8-10} Patients who have dyspnea on exertion also may have substantial airway compromise and should be carefully evaluated. The dyspnea may be caused by subglottic or regional fixed narrowing of the trachea, dynamic obstruction, intra- or extrathoracic obstruction, or any combination of these.⁸⁻¹⁰ Krell *et al.* found roentgenographic and bronchoscopic examinations to be misleading in determining the degree of tracheal obstruction.¹⁰ However, inspiratory and expiratory flow-volume loops were useful in predicting the degree of functional intra and extrathoracic obstruction.

McAdam *et al.*¹ and more recently Michet *et al.*² have published data on predictive indices and survival in two large prospective studies of 23 and 112 patients, respectively. Overall, the 5- and 10-yr probabilities for survival are 74 and 55%. According to a multivariate analysis model, early age of onset, anemia, and laryngotracheal stricture were the best predictors of mortality.² Saddle-nose deformity and subglottic strictures are most common among younger patients.² Unfortunately, for patients less

examination was unremarkable. Preoperative chest radiographs, electrocardiogram, electrolyte concentrations, and results of coagulation studies were within normal limits. The preoperative blood count was notable for a mild normocytic anemia and hemoglobin concentration of 12.7 g/dl.

On arrival in the operating room, standard monitors were applied including electrocardiogram, pulse oximeter, automated blood pressure cuff, and a precordial stethoscope. Intravenous access was obtained and anesthesia was induced by allowing the patient to breathe, *via* mask, a gradually increasing concentration of halothane in nitrous oxide and oxygen through a semiclosed circle system. Ventilation was monitored by continuous capnography, and the anesthetic gas mixture was monitored by mass spectrometry. The induction of anesthesia proceeded uneventfully and anesthesia was maintained with 3% halothane in oxygen ($F_{I_{O_2}} = 1.0$) with spontaneous ventilation by mask.

Upper-airway obstruction was encountered and relieved with insertion of an oral airway and use of the jaw-thrust maneuver. Intubation was attempted by means of direct laryngoscopy. The glottic structures were visualized; however, a styleted 8.0-mm cuffed endotracheal tube could not be passed because of subglottic resistance. A pediatric (3.5-mm) fiberoptic bronchoscope was inserted, *via* a diaphragm elbow connector, through the mask and into the patient's oropharynx, and was guided into the trachea. Tracheal rings were not identified, and the tracheal lumen underwent near total collapse with each inspiratory cycle. Upon completion of the bronchoscopic examination, cautious attempts were made to insert a styleted cuffed 7.0-mm and 6.0-mm endotracheal tubes into the trachea under direct vision. These attempts were made with the patient in the supine position and were met with considerable subglottic resistance.

Because of concerns over the potential subglottic edema and progressive narrowing of the stenotic subglottic region with repeated instrumentation, no further attempts at intubation were made. Given the elective nature of the surgery and the potential for severe airway compromise, anesthesia was discontinued and the patient awakened. Before the induction of general anesthesia, the patient had been counseled for this possibility and informed consent obtained for the procedure to be performed under local anesthesia with sedation. The remainder of the case proceeded uneventfully. Subsequent to his surgery (2 months) the patient underwent bronchoscopy while in both

than 50 yr of age, saddle-nose deformity and the presence of vasculitis are significant predictors of mortality.²

The most common causes of death among patients with relapsing polychondritis are infection, airway compromise, manifestations of vasculitis, and cardiac complications.^{1,2} Deaths from infection frequently are related to pneumonia and laryngotracheal disease as well as to the use of corticosteroids. McAdam *et al.* found airway involvement to be contributory in 28% of deaths.¹ Michet *et al.* found a smaller association between airway compromise and death (10%).² Deaths attributable to airway compromise have involved inflammation and edema of the affected trachea, and these deaths are not strictly related to the loss of laryngotracheal support.¹⁰

As indicated by our case presentation, we elected to terminate further attempts at intubation because of concern that subglottic irritation and any resulting edema might lead to further airway compromise. A clear understanding of the degree of airway involvement is essential to proper intraoperative management of the patient with relapsing polychondritis. Computerized tomography of the upper airway, taken in isolation, proved misleading in our patient by showing a normal airway caliber. In the absence of severe tracheal stenosis, roentgenographic studies do not reliably predict the degree of airflow obstruction.¹⁰ The flow-volume loop (fig. 1) consistently demonstrated classic findings of a fixed intra- and extra-thoracic airway obstruction. However, preoperative and intraoperative bronchoscopy proved useful in demonstrating the absence of a severe fixed stenosis, as predicted by the flow-volume loop, and served to illustrate the severe degree of dynamic airway closure on inspiration and expiration. There may be a predictive role for bronchoscopy, if performed with the patient in both the upright and supine positions and with inspection for dynamic airway closure and positional changes in the flow-volume loops.

Recognizing the high incidence of subglottic stenosis in the relapsing polycondritis patient, we speculate that an inhalation induction with spontaneous ventilation may

provide a degree of safety; however, in the absence of extrinsic compression of the trachea, controlled ventilation with positive end-expiratory pressure may prove equally effective. The trachea may be prevented from collapsing if continuous positive airway pressure is applied *via* a mask in selected cases. Awake intubation with the patient in the upright position may prevent passive tracheal collapse; intubation over a bronchoscope also may provide security to minimize traumatic instrumentation of the already compromised tracheal lumen. Also, a non-styleted endotracheal tube may traverse the trachea more easily than a rigid endotracheal tube when tracheomalacia is present. Finally, local or regional anesthesia should be considered carefully as the anesthetic of choice for patients with relapsing polychondritis who undergo elective surgical procedures. If general endotracheal anesthesia is necessary, the patient should be counseled, and tracheostomy if required should be considered as a last resort.

REFERENCES

1. McAdam LP, O'Hanlan MA, Bluestone R, Pearson CM: Relapsing polychondritis: Prospective study of 23 patients and a review of the literature. *Medicine* 55:193-215, 1976
2. Michet CJ Jr, McKenna CH, Luthra HS, O'Fallon WM: Relapsing polychondritis. Survival and predictive role of early disease manifestations. *Ann Int Med* 104:74-78, 1986
3. Hainer JW, Hamilton GW: Aortic abnormalities in relapsing polychondritis. *N Engl J Med* 280:1166-1168, 1969
4. VanDecker W, Panidis IP: Relapsing polychondritis and cardiac valvular involvement. *Ann Int Med* 190:340-341, 1988
5. Balsa-Criado A, Garcia-Fernandez F, Roldan I: Cardiac involvement in relapsing polychondritis. *Int J Cardiol* 14:381-383, 1987
6. West PDB: Relapsing polychondritis: An unusual presentation. *J Laryngol Otol* 102:254-255, 1988
7. Neilly JB, Winter JH, Stevenson RD: Progressive tracheobronchial polychondritis: need for early diagnosis. *Thorax* 40:78-79, 1985
8. Gibson GJ, Davis P: Respiratory complications of relapsing polychondritis. *Thorax* 29:726-731, 1974
9. Mohsenifar Z, Tashkin DP, Carson SA, Bellamy PE: Pulmonary function in patients with relapsing polychondritis. *Chest* 81: 711-717, 1982
10. Krell WS, Staats BA, Hyatt RE: Pulmonary function in relapsing polychondritis. *Am Rev Respir Dis* 133:1120-1123, 1986