

TITLE: SUCRALFATE DOES NOT REDUCE THE RISK OF ASPIRATION PNEUMONIA

AUTHORS: T.J.K. Toung, M.D., Y. Aizawa, M.D., R. Grayson, M.D. P. Reilly, M.D., T. Dorman, M.D., and R.J. Traystman, Ph.D.

AFFILIATION: Department of Anesthesiology and Critical Care Medicine, The Johns Hopkins University School of Medicine, Baltimore, MD 21205

H₂-receptor blockers and antacids are frequently administered to alter gastric pH and volume to prevent against aspiration pneumonia and stress ulcer bleeding. Alkalinization of the gastric juice is, however, associated with increased bacteria growth in the stomach and this has been implicated to the increased incidence of nosocomial pneumonia in the critically ill patient. Many are now being treated with sucralfate (S) instead. The present study examines the pulmonary effects of aspiration of S alone and its mixture with Hydrochloric acid (HCl) in the pig lung.

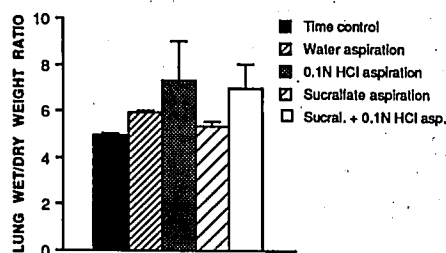
Thirty in-situ, isolated, blood perfused porcine lung preparations were studied. Lungs in each group (except control group 1) aspirated 1.5 mL/kg of its respective aspirant. 1) Time control, n=4; 2) H₂O, pH =5.5, n=4; 3) 1/10 N HCl, pH = 1, n=7; 4) S suspension (1 gm/30ml H₂O), pH = 4.9 n=8; 5) A mixture of S and HCl (equal volume), pH = 1.5,

n=7. Airway, pulmonary arterial pressures, and lung weight change were followed for 4 hrs after aspiration. Lung wet/dry weight ratio (W/D) was used as index of edema formation.

Aspiration of S alone caused only mild lung edema, whereas aspiration of its mixture with HCl caused severe lung edema which was similar to aspiration of 1/10 N HCl. Aspiration of H₂O, the carrier for S, caused moderate lung edema (Fig.1).

S is an aluminum salt of sucrose octasulfate. It protects the gastric mucosa against injury of H⁺ ions and pepsin without raising gastric pH. The present study shows that aspiration of a S + HCl mixture, a condition likely to occur clinically, causes lung injury as severe as aspiration of 1/10 N HCl. Therefore, the use of S to prevent stress gastric ulceration and bleeding does not reduce the risk of aspiration pneumonia.

Fig. 1.



TITLE: HEMATOLOGIC AND MORPHOLOGIC ALTERATIONS AFTER PROTECTIVE DEEP HYPOTHERMIC CIRCULATORY ARREST OF 1-2h IN DOGS.

AUTHORS: A. Radovsky, DVM, PhD, S.A. Tisherman, M.D., P. Safar, M.D., F. Sterz, M.D., K. Kuboyama, M.D.

AFFILIATION: International Resuscitation Research Center and Depts. Anes., Surg., Pathol, Univ. Pittsburgh, PA 15260

Uncontrollable hemorrhage might be repaired under deep hypothermic elective cardiac arrest. In 15 splenectomized dogs, after hemorrhagic shock (MAP=40 mmHg) of 30 min, deep hypothermia (15°C) was rapidly (13-37 min) induced by cardiopulmonary bypass (CPB) with hemodilution (1). Then, circulation was stopped for 60, 90 or 120 min (n=3x5) (to enable resuscitative surgery without bleeding). Resuscitation was with reperfusion, blood replacement, and rewarming by CPB. Clinically, 2 sham dogs, all 10 dogs arrested for 60 or 90 min, and 2 of 5 arrested for 120 min regained alertness and could sit and eat without assistance by 72 hours post-arrest.

Blood. After resuscitation, mean hct was 32% but decreased to 22% for the 72-168 hrs until termination. Erythrophagocytosis of RBCs by lymph node macrophages at 72 hrs suggested that RBCs damaged during the procedure were removed, but not rapidly replaced. Rapid onset severe

thrombocytopenia normalized by 1 wk. Megakaryocytes were in pulmonary vasculature (extramedullary thrombopoiesis) at 72 hrs. A transient marked leukocytosis (elevated neutrophils) and severely decreased lymphocytes were consistent with a marked stress response and transient sepsis.

Brain. Ischemic neuronal changes in the brain were determined as histopathologic damage (HD) scores by light microscopy: Total HD scores were 35+6 after 60 min arrest; 54+32 after 90 min; and 94+15 after 120 min. Some unilateral microinfarcts in all groups were probably embolic. Exceptions were bilateral symmetric infarcts in the amygdalae of 3 of 5 dogs arrested for 120 min were probably postischemic.

Viscera. Gross right ventricular myocardial necrosis was in both sham dogs as well as in arrested dogs. There were acute pneumonia (4 of 15); renal infarcts (6 of 15 plus 1 of 2 shams); hepatic degenerations (10 of 15); damage to the gall bladder (8 of 15) and thromboemboli in renal, hepatic, and cholangial vasculature.

Conclusion. In uncontrolled hemorrhage, deep hypothermic circulatory arrest of 60 or 90 min is feasible with protection against incapacitating brain damage and only relatively mild alterations in blood and viscera.

References:

1) Safar, et al: Amer J Emerg Med 8:55-67, 1990. (Supported by A. Laerdal Found. and NIH NS24446.)