

TITLE : INFLUENCE OF HEPARIN AND CITRATE(ACD) ON THE QUALITY OF PEROP WASHED AUTOTRANSFUSAL PLATELETS AND RED BLOOD CELLS

AUTHORS : Y. MORTELMANS, M.D., G. VERMAUT, M.D., H. VAN AKEN, M.D., M. GOOSSENS, Ph.D.

AFFILIATION: Dept. Anest., K.U. Leuven 3000, BELGIUM

There is an ongoing controversy about which anti-coagulant to prefer in the cell washing machine during non-cardiac intraoperative autotransfusion. In this randomised prospective study, after approval by the local ethical committee, the quality of washed autologous platelets and erythrocytes was investigated in two groups of 5 ASA-I-II patients undergoing total hip replacement: in group I heparin (heparin novo 30 IU/ml) was used in the Dideco BT 795P Autotrans machine while a classical 3% ACD solution (Travenol R) was used in group II. The volume ratio anticoagulant/cardiotomy blood loss was kept close to 1/7. Samples were taken from the patient (P) after induction of anesthesia and from the autotransfusion unit (A) immediately after its preparation. Platelet tests: electronic count, thromboxane secretion reserve capacity (TSRC)(1) and formation of reversible aggregates (2). Red cell tests: mean corpuscular volume (MCV), red distribution width (RDW), total hemolysis, osmotic fragility (OSM), filtrability (FIL), glutathione stability (GSH stab) and glutathione reductase (GSSG red)(3). Total hemolysis (in %) is evaluated by comparing total free hemoglobin(Hb) mass in waste bag to total "fixed" Hb autotransfused. FIL measures deformability of red cells with the aid of a 5µm filter (Nucleopore Corp., Pleassaton, California)

Both GSH stab and GSSG red are indicators of anti-oxidative reserve capacity of the red cell which is important for survival. Statistics: (un)paired Student's t test within (between) each group; p < 0.05\* (p < 0.005\*\*) significant; values are means (±SD).

Results of platelet tests were very bad in both groups: count < 50,000/ml; TSRC + 0%; no aggregates. In group II ACD autologous red cells (sample A) showed a significant increase from control (sample P) of MCV, RDW and OSM(\*\*). GSH stab and GSSG red were decreased(\*). Heparin red cells in group I didn't differ from control for all these tests; the same proved through for other enzymes as well: hexokinase, pyruvate kinase, glucose-6-phosphate dehydrogenase. FIL was bad in both groups. Total hemolysis was 50% higher in the ACD group(\*).

Washed platelets and their secretion products should be eliminated completely. Poor FIL is due to the kind of surgery. The bad quality of ACD red cells is most likely due to the acidity of the ACD solution and the fact that proper mixing (and thus inadvertent clotting) is more important using ACD. In our technical setup (= immediate retransfusion), heparin is preferable to ACD.

References: 1. Thrombosis Research 66:389-400, 1982  
2. Lancet 2:924-926, 1974  
3. Red cell metabolism. Grune and Stratton, New York, 1984(p.72)

GROUP (sample A)	Heparin(n=5)	ACD(n=5)
MCV (10 <sup>-12</sup> ml)	94.7 (+ 5.3)	* 109.5 (+8.3)
RDW (SD/meanx100)	12.6 (+0.5)	** 17.3 (+0.3)
OSM (H50 in gNaCl/L)	4.29(+1.23)	** 5.39(+0.2)
GSSG red (U/gHb)	4.64(+1.23)	** 1.91(+0.6)
Total hemolysis (%)	10.9 (+1.8)	* 14.9 (+3.1)

Downloaded from http://esa2.silverchair.com/anesthesiology/article-pdf/73/3A/NA/66577/10000542-199009001-00497.pdf by guest on 05 December 2022

PHONOCARDIOGRAPHIC MONITORING USING A SPECIAL ENDOTRACHEAL TUBE

D. John Doyle MD PhD, Leonides Y. Teves MD

\*Department of Anaesthesia, Toronto General Hospital, Toronto, Ont.

INTRODUCTION Although heart sound auscultation using esophageal and precordial stethoscopes is routine in anesthesia, these methods suffer from disadvantages, the precordial units being difficult to reliably attach to the anterior chest wall, and the esophageal units suffering from potential problems such as placement into the trachea or into an esophageal diverticulum, entanglement with the endotracheal tube and trauma to the oropharynx and varices. Both methods may also yield signals of low audio intensity. We describe an endotracheal tube (ETT) designed to eliminate the need for a separate stethoscope for cardiac auscultation.

DESIGN The ETT is specially constructed unit with a wide-bore cuff inflation line acoustically connected to a leak-free microphone by a three-way valve following cuff inflation. Inflation pressures are kept to about 25 cm H<sub>2</sub>O. An audio preamplifier (gain=100) amplifies the microphone signal to an amplitude suitable for recording using a professional cassette recorder. A set of earphones allows the phonocardiogram (PCG) to be monitored intraoperatively.

EVALUATION The system was evaluated at two centers (Toronto General Hospital, Toronto, Ontario and Manatee Memorial Hospital, Bradenton, Florida) in 20 surgical patients undergoing general anaesthesia with positive pressure ventilation. No special problems were met in placement of the tube. In all cases the PCG was heard with remarkable clarity. Simultaneous recordings were taken from an esophageal stethoscope in two cases, but they were barely audible at the gain settings used for the ETT system. Similarly, two recordings taken using a conventional ETT with a small-bore cuff inflation line were inaudible. The Figure shows the PCG recorded by computer in one patient between excursions of the ventilator bellows.

DISCUSSION This method of PCG recording eliminates the need for precordial and esophageal stethoscopes in intubated patients. The clarity of the signals obtained is likely related to the proximity of the endotracheal tube cuff to the heart. This system may facilitate the use of the surgical PCG as an indicator of myocardial function, especially if used in conjunction with recent PCG digital signal processing techniques.

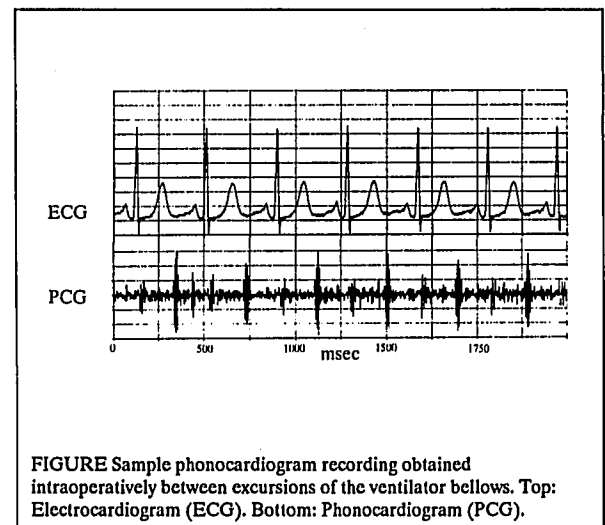


FIGURE Sample phonocardiogram recording obtained intraoperatively between excursions of the ventilator bellows. Top: Electrocardiogram (ECG). Bottom: Phonocardiogram (PCG).