

Title: ASSESSMENT OF REGIONAL MYOCARDIAL CARDIOPLEGIA DISTRIBUTION WITH CONTRAST ECHOCARDIOGRAPHY IN DOGS: RETROGRADE VS. ANTEGRADE DELIVERY METHODS

Authors: S. Aronson, M.D., B.K. Lee, M.D., J. Leddicat, B.S., J. Wiencek, B.S., J. Zaroff, B.S., J.E. Ellis, M.D., S.B. Feinstein, M.D., M.F. Roizen, M.D.

Affiliation: Depts. of Anes. and Critical Care and Cardiac Surgery, University of Chicago, Chicago, Illinois 60637

Cardioplegic protection is limited by nonhomogeneous distribution distal to coronary artery obstructions. Retrograde cardioplegia delivery via the coronary sinus offers an effective means for delivering cardioplegia distal to obstructions and, in combination with antegrade delivery, has been shown to provide superior conditions for myocardial preservation compared with antegrade delivery alone.¹ Antegrade delivery of cardioplegia into the myocardium is difficult to predict since it varies according to intrinsic disease and collateral circulation. Retrograde delivery of cardioplegia requires an atriotomy for catheter placement, as flow into the coronary sinus is dependent on anatomic variability and surgical technique.¹ A method to easily monitor the adequacy of antegrade delivery of cardioplegia and enable one to decide if retrograde catheter insertion is warranted and then allow monitoring of retrograde cardioplegia distribution might be beneficial. We tested the hypothesis that contrast echocardiography² could be used to compare the differences in the regional myocardial distribution between antegrade and retrograde delivery of cardioplegia.

Institutional approval was obtained to study six anesthetized dogs. Aortic root and coronary sinus cardioplegia catheters were inserted after cardiopulmonary bypass (CPB) was instituted. The left circumflex (LCX) and left anterior descending (LAD) coronary arteries were identified and isolated. Sonicated albumin

microspheres (Albunex®)³ were injected into the antegrade and retrograde catheters during the following situations with cardioplegia flow used as the carrier solution: 1) Antegrade control, 2) Retrograde control, 3) Antegrade with LCX occlusion, 4) Retrograde with LCX occlusion, 5) Antegrade with LCX and LAD occlusion, 6) Retrograde with LCX and LAD occlusion. Before, during, and after contrast injections, 2D echo images of the left ventricle were obtained and recorded on videotape. Ultrasound reflectance was then analyzed off-line by 3 separate blinded investigators. Recorded images were traced onto vellum paper directly from the monitor. The presence or absence of contrast enhancement of regional myocardial cardioplegia distribution was determined by each observer and pooled for each injection by planimetry (Table). Regions of filling defects after antegrade and retrograde injections were compared using Student's t-test to determine statistical significance ($p < 0.01$).

Mean filling defect expressed as percentage of left ventricular myocardium (\pm SD). *Significant when compared to antegrade control.

	Antegrade	Retrograde
Control	0.0 \pm 0.0	10.3* \pm 5.0
LCX	57.1* \pm 10.6	13.1* \pm 1.6
LCX & LAD occlusion	68.0* \pm 19.5	11.2* \pm 5.7

Visualization of contrast enhancement of regional cardioplegia distribution was easily obtained in all dogs with both antegrade and retrograde delivery. No filling defects were observed with control antegrade injections; however, hypoperfusion of the septal region was noted with control retrograde injections, ($p < 0.01$). During occlusion of either the LCX or LAD coronary arteries, significant filling defects were noted in myocardial regions subserved by those coronary arteries (i.e., anterior and lateral walls) during antegrade injections. Retrograde injection always delivered cardioplegia to all regions of the myocardium except the septal region ($p < 0.01$).

1. J Thorac Cardiovasc Surg 98:956-60, 1989.
2. Anesthesiology 2:295-301, 1990.
3. Circulation, 78 II:565, 1988.

A568

TITLE: DIFFERENT CARDIOVASCULAR RESPONSES TO VOLUME EXPANSION DURING HALOTHANE AND ISOFLURANE ANESTHESIA

AUTHORS: N Mayer, MD and M Zimpfer, MD
AFFILIATION: Dept. of Anesthesia and General Intensive Care, Univ. of Vienna, A-1090 Vienna, Austria

Volume expansion (VE) is often employed to mitigate cardiovascular side effects of volatile anesthetics. The present study was designed to determine the impact of halothane (H) and isoflurane (I) on responses to VE in chronically instrumented dogs.

Methods: LV-pressure gauges, ultrasonic crystals, placed on opposing endocardial surfaces of the LV, and aortic flow probes were implanted in 9 mongrel dogs. 1000-2500 ml of Ringer were infused in the animals conscious and anesthetized with 1-2% H and 1-3% I, respectively on separate experimental days. Data were evaluated at every 200 ml of infused volume and statistics were calculated by analysis of variance.

Results: With all concentrations of both anesthetics VE resulted in lesser increases of cardiac output (CO) than in the conscious state and 1% I was more depressant than 1% H (Fig 1). The mechanism for increased CO was different: with H heart rate increased, with I the increase was from

stroke volume. With 2% H and 3% I, VE resulted in no increase in CO and sometimes even a decrease.

Discussion: H and I interfere with the cardiovascular responses to VE. VE increased CO and arterial pressure in the conscious animals and in the dogs anesthetized with the low concentrations of H and I. Changes in arterial pressure reflect the increase of CO during light anesthesia. However, during deep anesthesia VE cannot overcome the cardiac depressant effect of either agent and might elicit deleterious increases of end-diastolic pressure.

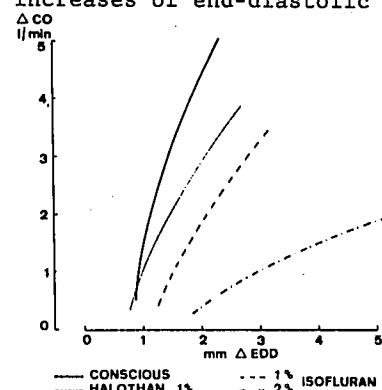


FIG. 1