

Title: SPINAL ANESTHESIA WITH HYPERBARIC BUPIVACAINE AND LIDOCAINE FOR CESAREAN SECTION: A PILOT STUDY

Authors: LJ Jassy, M.D.; DJ Tom, M.D.

Affiliation: Department of Anesthesiology Mercy Hospital and Medical Center, San Diego, CA 92103

Introduction: We evaluated a combination of hyperbaric bupivacaine and lidocaine in spinal anesthesia for Cesarean section. This combination has not been reported for spinal anesthesia. Lidocaine provides a rapid onset of dense anesthesia but relatively short duration.(1) A 12 mg dose of bupivacaine provides anesthesia for a wide range of patients(2) and has a longer duration with motor function recovering before sensation(3) . However, the onset of bupivacaine can be up to 15 minutes.(4) This study was designed to determine whether combining bupivacaine with lidocaine might provide a spinal anesthetic with the advantages of both drugs.

Methods: After obtaining IRB approval and written informed consent, 16 patients, ASA II, for Cesarean section under spinal anesthesia were given a single injection containing: 1) 12mg 0.75% bupivacaine in 8.25% dextrose (1.6cc); 2) 40mg 5% lidocaine in 7.5% dextrose (0.8cc); 3) 0.2-0.3 mg preservative-free morphine (0.2-0.3cc); and 4) 20mcg fentanyl (0.4cc) for a total volume of 3.0-3.1cc. The specific gravity of this mixture is 1.033 at 25°C versus 1.030-1.035 for the two hyperbaric anesthetics alone. All spinal injections were performed in the sitting position at the L2-3 or L3-4 interspace. The patient was immediately placed supine with left uterine displacement. Table positioning was adjusted by the anesthesiologist as he/she felt was necessary. Sensory levels to pin prick and motor block according to the Bromage scale(5) were assessed every two minutes from the time the spinal injection was completed until surgery started. During surgery, patients were evaluated for hypotension, nausea/emesis, pain, difficulty breathing or swallowing secondary to a high block. Once the skin incision was closed, sensory and motor levels were assessed every fifteen minutes until complete regression of motor blockade. Data were also collected regarding exteriorization of the uterus,

degree of Trendelenberg employed, vertical skin incision, PACU analgesic requirement, spinal headache or neurologic complications.

Results: Patient age was 28.6±3.7 years (mean±S.D.), height was 166.5cm (range 155-178), and weight was 86.4 kg (range 58-140). The time to onset of T4 block was 4.3 ± 1.5 minutes(mean±S.D.); complete motor block (Bromage scale score =3) was achieved by 5.0 ± 2.1 minutes (mean±S.D.). No patient required more than 0-10° Trendelenberg to achieve adequate anesthesia.No patient complained of intraoperative pain ; the uterus was exteriorized in all cases and two patients had vertical incisions. Nausea occurred in 50%; hypotension, defined as a decrease in BPsys > 25% from baseline or < 100 torr,occurred in 38%. The average time from injection of spinal anesthetic to skin incision was 9.0 ± 2.7 minutes (mean±S.D.). No patient complained of difficulty swallowing or breathing; despite average intraoperative sensory levels of T2 to T4. Average surgical time was 39 minutes. Complete regression of motor block was 204.6 ± 28.2 minutes (mean±S.D.); two segment regression from T2 or T4 was 98.5 ± 34.3 minutes(mean±S.D.). Thirty-eight percent of patients required no analgesics in the PACU.

Discussion: The combination of hyperbaric bupivacaine and lidocaine appears to offer the advantages of both drugs: rapid onset, intermediate duration, and excellent surgical anesthesia using a uniform dose over a wide range of patient heights and weights. No patient had to be tilted head down to achieve adequate anesthesia. Despite high dermatome levels in our patients, none complained of difficulty swallowing or breathing contrary to our experience with lidocaine alone. No patient complained of intraoperative pain; no patient requested intraop analgesia or sedation. We are currently comparing this combination with other local anesthetics in a controlled, randomized study.

References: 1) Cousins MJ : Neural Blockade in Clinical Anesthesia and Management of Pain. Philadelphia: JB Lippincott,1980. p149. 2) Norris MC: Anesth Analg 67: 555-8, 1988. 3) Abouleish EI: Anesth Analg 66: 395-400, 1987. 4) Russell IF: Br J Anaesth 59: 347-53, 1987. 5) Bromage PR: Br J Anaesth 36: 342-52, 1964.

A983

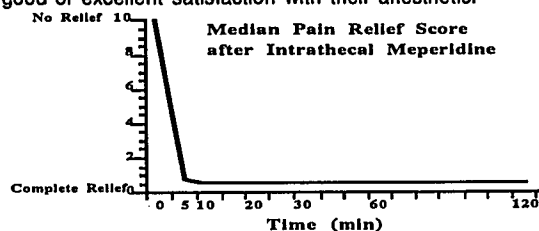
TITLE: Intrathecal Meperidine for Labor Analgesia
AUTHORS: M.C. Norris, M.D., S. Boreen, M.D., B.L. Leighton, M.D., D. Mingey, M.D., H. Kent, M.D.
AFFILIATION: Department of Anesthesiology, Thomas Jefferson University, Philadelphia, PA. 19107

Intrathecal fentanyl/morphine for labor analgesia offers advantages over lumbar epidural analgesia, but frequent side effects and finite duration of action limit its use. Recently small gauge spinal catheters have become available. This development led us to study intrathecal meperidine, a rapidly acting narcotic of intermediate duration, as a labor analgesic.

Twelve healthy term parturients with no history of drug abuse gave written informed consent to participate in this IRB approved protocol. When the patient requested pain relief, we inserted a 32 g spinal catheter and injected 10 mg preservative-free meperidine in 1 ml normal saline. Before and 5, 10, 20, 30, 60, and 120 minutes after injection, we measured blood pressure and motor block. At the same times, the patients rated their pain, pain relief, itching and nausea on 10 cm unmarked visual analogue scales. At delivery we recorded neonatal APGAR scores and all drugs administered. Postpartum, an obstetrician assessed the fetal heart rate (FHR) recordings and the patients rated their satisfaction with their anesthetic.

We obtained CSF in all 12 patients, however in two women we were unable to insert the 32 g catheter. Intrathecal meperidine, 10 mg, provided prompt pain relief in 8 of the remaining 10 patients; pain intensity decreased dramatically by 5 minutes (Figure). Two women required a second 10 mg dose at 10 minutes to obtain adequate pain relief. Median itching and nausea scores did not change significantly. One patient had clinically significant itching and 2 had single episodes of

vomiting. Two women required ephedrine for transient hypotension. In 3 women, intrathecal meperidine provided adequate analgesia until delivery 58, 66 and 244 min later. The other patients requested additional analgesia 136±58 (mean±SD) min after initial injection. Four patients delivered by cesarean section for failure to progress, 6 delivered vaginally. FHR pattern changes occurred in 5 cases. In one, late decelerations occurred which lasted 20 min and resolved after discontinuation of oxytocin infusion. FHR variability diminished for 10-15 minutes in 3 instances, and in one case deep variable decelerations developed coincident with rapid progression of cervical dilatation. Nine of 10 infants were vigorous at birth with APGAR scores above 7. One infant had APGAR scores of 4 and 8 at 1 and 5 min. No woman suffered immediate or delayed respiratory depression and all expressed good or excellent satisfaction with their anesthetic.



Meperidine, a lipid soluble narcotic with an intermediate duration of action, has a long history of safe use in obstetrics. It also has weak local anesthetic properties which may enhance its analgesic effects. This preliminary study has shown that intrathecal meperidine effectively relieves the pain of labor. We feel that this promising agent deserves further study.