

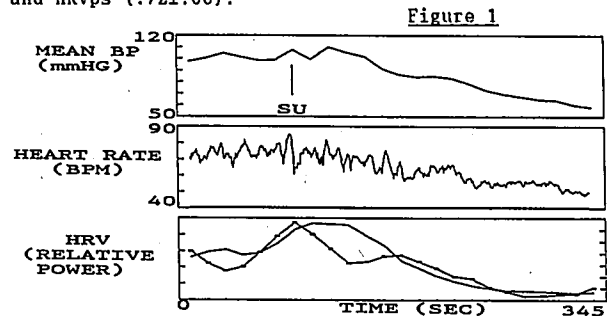
**TITLE:** CHANGES IN HEART RATE VARIABILITY CORRELATE WITH DECREASES IN BLOOD PRESSURE  
**AUTHORS:** TW Latson, MD, DC Martin, MD, CW Whitten, MD, VA Hyndman, J Elmore, MD  
**AFFILIATION:** UT Southwestern Medical School, Dept. of Anesthesiology, Dallas, Texas 75235

**INTRODUCTION:** The hemodynamic effects of potent narcotics are mediated by central actions on both sympathetic (SY) and parasympathetic (PS) reflexes.<sup>1</sup> The activity of these reflexes may be assessed by analysis of the amplitude of small oscillations in heart rate (HR), known as "heart rate variability" (HRV).<sup>2</sup> The purpose of this study was to use analysis of HRV to closely examine the temporal relationships between changes in SY reflexes, PS reflexes, and mean blood pressure (BP) during induction of anesthesia with sufentanil (SU).

**METHODS:** After institutional approval and informed consent, we obtained digital recordings of both the EKG and radial artery pressure (250 Hz and 25 Hz respectively) in 8 patients anesthetized with SU for elective cardiac surgery. Anesthesia was induced with a loading dose of 0.5 µg/kg SU, followed by an infusion at 0.5 µg/kg/min (total dose 3.0±0.8 µg/kg). After loss of consciousness, patients were given vecuronium 10 mg IV, ventilated by mask with 100% O<sub>2</sub>, and then intubated approximately 3 min later.

An HR signal was derived from the recorded EKG, beginning 2 min prior to SU administration and extending up to 30 sec prior to intubation. HRV measurements were then derived every 15 sec from overlapping 64 sec data epochs of this HR signal.<sup>3</sup> SY activity (HRVsy) was assessed by measuring the spectral power of the HR oscillations at frequencies below 0.125 Hz, and PS activity (HRVps) by the power of oscillations between 0.126 and 0.4 Hz. These trended HRV measurements were correlated with corresponding mean BP measurements (sampled every 15 sec) using least-squares regression. **RESULTS:** Highly significant correlations were found between the trended changes in BP and HRVsy (p<.001 for 7; p<.01 for 1), and between the trended changes in BP

and HRVps (p<.001 for 6, p<.01 for 1, p<.05 for 1) for all patients. Results from one patient are shown in Fig 1. The close temporal relationships between decreases in mean BP, visible HR oscillations, HRVsy (dotted line), and HRVps (solid line) following SU administration ("SU") are readily apparent. There were significant correlations even in patients with minimal change in mean HR (<4bpm). The r values for the correlation between BP and HRVsy (.76±.05 mean±SEM) were not significantly different from the r values between BP and HRVps (.72±.06).



**DISCUSSION:** These results demonstrate highly significant correlations between trended changes in mean BP and HRV during induction of anesthesia with SU. These correlations document a very close temporal relationship between SU's effect on autonomic reflexes and the resulting change in BP. The similar correlations of HRVsy and HRVps with BP precludes any conclusions about a dominant role of either the SY or PS systems on the change in BP, but do suggest a similar time course of effect by SU on both systems.  
**REFERENCES:** 1) Eur J Pharm 28:66-75, 1974. 2) Circ Res 59:178-93, 1986. 3) Anesth Analg 70:S226, 1990.

A1208

**Title:** CONTRAST ECHOCARDIOGRAPHY: THE DIRECT, ON-LINE, INTRAOPERATIVE ASSESSMENT OF REGIONAL MYOCARDIAL PERFUSION DURING CABG SURGERY

**Authors:** S. Aronson, M.D., B.K. Lee, M.D., J. Wiencek, B.S., S.B. Feinstein, M.D., M.F. Roizen, M.D., R.B. Karp, M.D., J.E. Ellis, M.D.

**Affiliation:** Depts. of Anesthesia and Critical Care and Cardiac Surgery, University of Chicago, Chicago, IL 60637

Traditional techniques used to assess ischemic heart disease during cardiac surgery include monitoring electrocardiographic, echocardiographic, and hemodynamic changes. These changes, however, provide only indirect evidence of the adequacy of regional myocardial perfusion. A practical, safe, and reliable method that would enable the direct evaluation of regional myocardial perfusion following coronary artery bypass graft (CABG) surgery would be beneficial. Contrast echocardiography has recently been used to define myocardial perfusion during angiography<sup>1</sup> and during CABG surgery.<sup>2</sup>

We evaluated ten patients during CABG surgery using contrast echocardiographic techniques<sup>3</sup> that enabled direct evaluation of regional myocardial perfusion before, during, and after saphenous vein graft bypass surgery. To the best of our knowledge, this is the first clinical report of direct, on-line pre- and postbypass assessment of regional myocardial perfusion using transesophageal echocardiography with contrast during CABG surgery.

Institutional approval from the clinical investigation committee and individual informed consent was obtained. Throughout the procedure, continuous 2D transesophageal echocardiographic images were recorded. Immediately after the institution of cardiopulmonary bypass and application of the aortic occlusive clamp, sonicated Renograffin-76

microbubbles were injected into the aortic root through the cardioplegia catheter with cardioplegia as the carrier solution. In half the patients studied, the distal veins were anastomosed to the coronary arteries before the proximal aorto-veins were (the usual procedure for that surgeon). This procedure allowed selective saphenous vein bypass injections. At the completion of surgery, all of the patients, including those in whom the proximal veins were anastomosed to the aortic root first, had contrast injected into the aortic root again during reperfusion of the heart with warm blood. The predicted myocardial magnitude and geometry of regional perfusion patterns following coronary artery-vein bypass, and the actual perfusion pattern assessed by contrast ultrasound, were compared off-line by a surgeon and a cardiologist who were blinded to contrast enhancement patterns.

Contrast enhancement of regional myocardial perfusion was easily visualized by the anesthesiologist and surgeon at the time of each injection. Prebypass contrast injections allowed the identification of myocardial regions with little or no flow. Direct saphenous vein injections provided useful information about the magnitude and geometric distribution of coronary artery-vein bypass run-off into the myocardium. Postbypass aortic root injections during reperfusion allowed the identification of poorly perfused myocardial regions before separation from cardiopulmonary bypass.

Preliminary analysis of our data on the prediction of perfusion patterns indicates that these predictions are not often actualized. We conclude that assessment of graft function following coronary artery bypass surgery can be made intraoperatively on-line with contrast echocardiography.

**References:**

1. J Am Coll Cardiol 11:59-65, 1988
2. J Thorac Cardiovasc Surg 99:536-542, 1990
3. Anesthesiology 72:295-301, 1990