

Anesthesiology  
73:775-776, 1990

## Airway Compromise from Prevertebral Soft Tissue Swelling during Placement of Halo-Traction for Cervical Spine Injury

TIMOTHY D. MEAKEM, M.D.,\* THOMAS J. MEAKEM, M.D.,† WILLIAM RAPPAPORT, M.D.‡

Prevertebral soft tissue swelling (PSTS) is frequently associated with cervical spine (c-spine) injury.<sup>1,2</sup> Its presence radiographically may indicate occult fracture of the adjacent vertebrae.<sup>1-3</sup> We are unaware of any previous report of traumatic PSTS actually resulting in the loss of airway patency during neck manipulation. We report a case of a patient who had massive PSTS associated with halo-traction placement.

### CASE REPORT

A 37-yr-old man was involved in an alcohol-related motorcycle accident. On evaluation, he was found to have a widened C2 disc space, anterior subluxation of C2 on C3, and 36 mm of PSTS anterior to C2 (fig. 1). Computed tomography of the neck revealed complete C2 dislocation, which was consistent with complete disruption of the interosseous ligaments and the C2-C3 intervertebral disc. The patient was transferred to the intensive care unit (ICU) for placement of a halo-traction device before going to the operating room for debridement of his open tibial fracture. Throughout this time, the patient's neurologic examination results were normal, and neither stridor nor dyspnea was present. The patient was intoxicated but conversant and reasonably cooperative. Pulse oximetry breathing room air revealed oxygen saturation ( $Sp_{O_2}$ ) consistently ranging from 95-99%.

During halo placement (approximately 10 h after the accident), the patient made a few sounds in a higher pitch voice than he had used previously, and despite inspiratory efforts, he developed complete airway obstruction. He remained awake and attempted to follow commands until he was given thiopental (250 mg) and succinylcholine (100 mg) iv. Direct laryngoscopy (DL) revealed a markedly swollen epiglottis, but no perivocal cord structures were visible despite moderate anterior pressure. The tip of the endotracheal tube (which had a stylette inside) was used to laterally retract some of the swollen subepiglottic tissue, exposing arytenoid cartilage, and the tube was advanced gently just anterior to that structure. The vocal cords were never seen. The patient's lungs were ventilated with 100% oxygen, and bilateral breath sounds confirmed proper endotracheal tube placement. Total time from airway obstruction to successful intubation was approximately 2 or 3 min. The  $Sp_{O_2}$  again ranged from 95-99% within 1 min of

intubation. A neurologic examination revealed no deficits. A lateral neck radiograph done 7 days later showed diminished PSTS (fig. 2), and the trachea was extubated on the eighth day without incident.

### DISCUSSION

Prevertebral soft tissue swelling is frequently present in c-spine fractures and is usually due to edema or hematoma.<sup>1,2,4</sup> Attention to the size of this swelling has fallen out of favor because of the large variation in normal measurements that limit its diagnostic usefulness in alerting the viewer to the presence of an occult fracture.<sup>3</sup> Additionally, this finding usually does not generate the same concern for imminent airway compromise in adults as it does in children.

Our patient compensated for this swelling by slight extension of the head, much as a child with epiglottitis does.<sup>5</sup> We believe that ongoing PSTS coupled with slight flexion

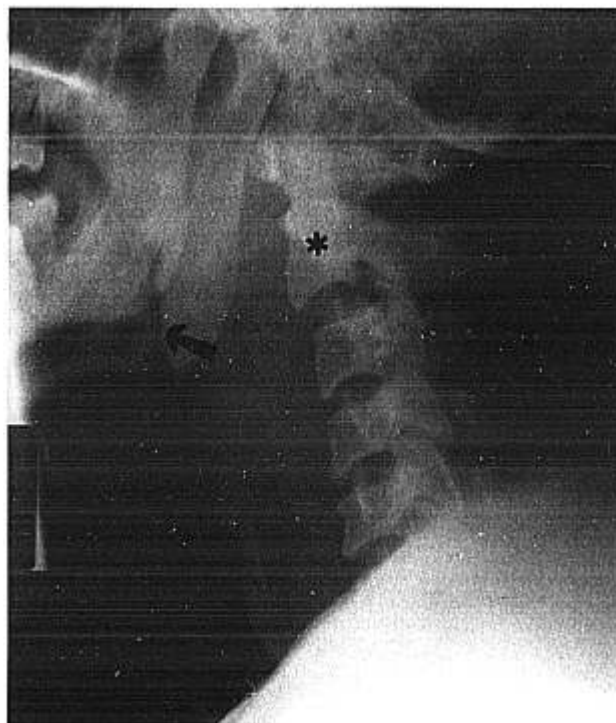

FIG. 1. Admission lateral cervical spine radiograph shows marked PSTS (arrow), resulting in partial compromise of the airway. Note also the anterior subluxation of C2 (asterisk) in relation to C3.

\* Resident in Anesthesiology.

† Resident in Radiology.

‡ Associate Professor of Surgery.

Received from the University of Arizona, Tucson, Arizona. Accepted for publication April 30, 1990. The above case occurred at the University of Arizona Health Sciences Center, Tucson, Arizona.

Address reprint requests to Dr. Meakem: % The University of Virginia, Department of Anesthesiology, Charlottesville, Virginia 22908.

Key words: Airway, obstruction; prevertebral soft tissue swelling. Cervical spine injury; airway obstruction; prevertebral soft tissue swelling. Halo-traction; complications. Intubation; prevertebral soft tissue swelling. Spine; cervical injury. Trachea; intubation.

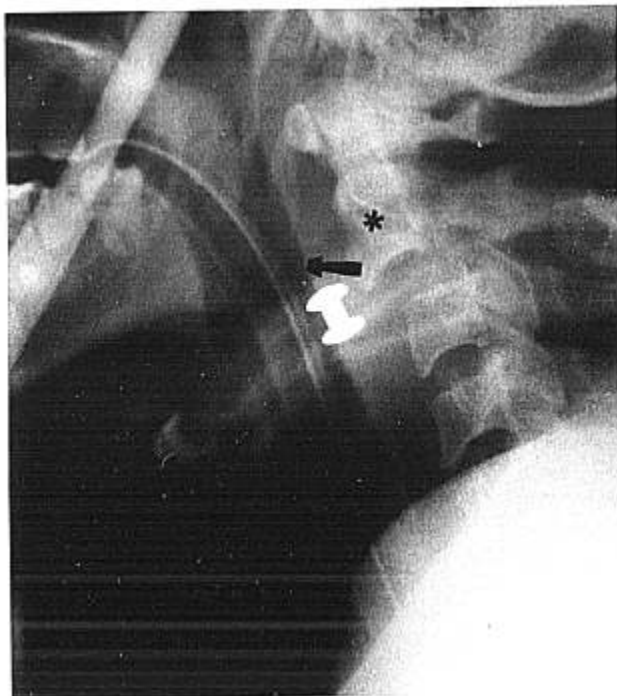


FIG. 2. Lateral neck radiograph 7 days after admission shows reduction in PSTS (arrow) to 12 mm anterior to C2 (asterisk), and patent airway between the anterior edge of the PSTS and the posterior edge of the endotracheal tube. Subluxation of C2 on C3 is again seen.

of the head during attachment of the halo were responsible for the sudden loss of airway patency in this patient. No fiberoptic bronchoscope, light wand, or transtracheal jet ventilator was readily available, and ventilation *via* mask was not possible. The patient was rather obese, and had a short neck. Additionally, the halo vest and hardware made access to the cricothyroid area very awkward without first removing the halo. Because of these factors, it was elected to proceed with DL with the halo in place. If this had not have been successful, a cricothyroidotomy would have been performed. In retrospect, an attempt at relieving the obstruction by jaw thrust, anterior tongue displacement, or nasal airway placement may have been

warranted. No such maneuver was attempted in this patient.

Airway compromise as a result of c-spine injury and PSTS suggests the need for prophylactic early intubation in this situation. Obviously, if this is the first reported case of this type, the risk of airway compromise probably does not justify routine prophylactic intubation of all patients with c-spine injuries and PSTS. Our experience, however, does support at least careful observation of these patients in an ICU setting, with the personnel and supplies required to secure the airway readily available. Additionally, the timing of our patient's airway obstruction suggests that they should remain in the ICU for a considerable period of time after the injury and during placement of halo-traction. Patients who are symptomatic or deemed likely to have airway problems should probably have their trachea intubated in an operating room (preferably one equipped with a transtracheal jet ventilator). Surgeons who are proficient in performing tracheostomy or cricothyroidotomy should be present.

A reliable method of distinguishing the patients who can safely be observed from those who should have prophylactic intubation remains elusive. Similarly, the size of PSTS seems unlikely to be a good predictor because of tremendous variations among normal people.<sup>3</sup> Until more reliable predictors are identified, we must depend on a high index of suspicion, close observation, and perhaps, serial radiographs of the area in question.

#### REFERENCES

1. Rogers LF: Radiology of Skeletal Trauma. New York, Churchill-Livingstone, 1982, p 280
2. Harris JH Jr: Radiology of Acute Cervical Spine Trauma. Baltimore, Williams and Wilkins, 1978, pp 31-34
3. Templeton PA, Young JW, Mirvis SE, Buddemeyer EU: The value of retropharyngeal soft tissue measurements in trauma of the adult cervical spine. *Skeletal Radiol* 16:98-104, 1987
4. Coleman JA Jr., Johnson JT: Retropharyngeal hematoma: Complication of cervical fracture. *Otolaryngol Head Neck Surg* 94: 387-390, 1986
5. Roberts KB: Upper airway obstruction, *Manual of Clinical Problems in Pediatrics*. Edited by Roberts KB. Boston. Little, Brown and Co., 1979, pp 13-15