

izing drug in this edentulous patient at risk for aspiration and with possible phenytoin-induced resistance to a non-depolarizing muscle relaxant.<sup>13</sup> Isoflurane seemed a good choice for an ill-nourished epileptic.<sup>14</sup>

It is unclear why this patient was slow to awaken despite mass spectrometer indication of little or no residual anesthetic. Temperature, urinary output, electrolytes, and arterial blood gases were normal in the immediate post-operative period, and there was no sign of central nervous system changes once the patient awakened. Prolonged sedation from the preoperative medications is a possibility, although it seems doubtful in consideration of phenytoin-induced liver enzyme stimulation.<sup>15</sup> However, valproic acid has the opposite effect.<sup>15</sup> The patient's preoperative liver function tests were normal.

Although one cannot generalize from a single case, this patient's anesthesia, except for a slow emergence, was uneventful and may provide useful guidelines for those responsible for providing anesthesia to a patient with Kufs' disease.

The author thanks A. J. Wright, M.L.S., clinical librarian at the University of Alabama, Birmingham Department of Anesthesiology, for his diligent search of the literature.

#### REFERENCES

- Swick HM: Diseases of gray matter, *Pediatric Neurology: Principles and Practice*. Edited by Swaiman KF. St. Louis, C.V. Mosby, 1989, pp 777-794
- Gospe, Jr SM, Jankovic J: Drug-induced dystonia in neuronal ceroid-lipofuscinosis. *Pediatr Neurol* 2:236-237, 1986
- Ngai SH: Parkinsonism, levodopa and anesthesia. *ANESTHESIOLOGY* 37:344-351, 1972
- Peringer E, Jenner IM, Donaldson IM, Marsden CB, Miller R: Metoclopramide and dopamine receptor blockade. *Neuropharmacology* 15:463-469, 1976
- Patton, Jr CM: Rapid induction of dyskinesia by droperidol. *ANESTHESIOLOGY* 43:126-127, 1975
- Hoiem AO: Another case of grand mal seizure after fentanyl administration (letter). *ANESTHESIOLOGY* 60:387-388, 1984
- Molbeggott LP, Flashburg MH, Karasic HL, Karlin BL: Probable seizures after sufentanil. *Anesth Analg* 66:91-93, 1987
- Ferrer-Allado T, Brechner VL, Dymond A, Cozen H, Crandall P: Electroconvulsive phenomenon in human limbic and thalamic regions induced by ketamine. *ANESTHESIOLOGY* 38:333-344, 1973
- Hetherington A, Rosenblatt RM: Ketamine and paralysis agitans (letter). *ANESTHESIOLOGY* 52:527, 1980
- Johnson BD: Psychosis and ketamine. *Br Med J* 4:428-429, 1971
- Khorrarnzadeh E, Lofty AO: Personality predisposition and emergence phenomena with ketamine. *Psychosomatics* 17:94-95, 1976
- Gravlee GP: Succinylcholine-induced hyperkalemia in a patient with Parkinson's disease. *Anesth Analg* 59:444-446, 1980
- Azar I: The response of patients with neuromuscular diseases to muscle relaxants: A review. *ANESTHESIOLOGY* 61:173-187, 1984
- Lebowitz MH, Blitt CD, Dillon JB: Enflurane-induced central nervous system excitation and its relation to carbon dioxide tension. *Anesth Analg* 51:355-363, 1972
- Park BK, Breckenridge AM: Clinical implications of enzyme induction and enzyme inhibition. *Clin Pharmacokinet* 6:1-24, 1981

Anesthesiology  
73:1042-1046, 1990

## Intramyocardial Air Causes Right Ventricular Dysfunction after Repair of a Congenital Heart Defect

WILLIAM J. GREELEY, M.D.,\* FRANK H. KERN, M.D.,† ROSS M. UNGERLEIDER, M.D.,‡  
JOSEPH A. KISSLO, M.D.§

The intraoperative occurrence of right ventricular dysfunction can complicate the repair of congenital heart

\* Associate Professor of Anesthesiology and Pediatrics; Associate, Pediatric Cardiology.

† Assistant Professor of Anesthesiology; Associate in Pediatrics.

‡ Assistant Professor of Surgery.

§ Professor of Medicine.

Received from the Departments of Anesthesiology, Pediatrics, Medicine and Surgery, Duke University Medical Center, Durham, North Carolina. Accepted for publication May 25, 1990.

Address reprint requests to Dr. Greeley: Box 3046, Duke University Medical Center, Durham, North Carolina 27710.

Key words: Anesthesia; pediatric cardiovascular. Heart; intramyocardial air. Monitoring; echocardiography, intraoperative. Surgery; congenital heart disease.

defects in children and thereby cause low-output syndrome and difficulty separating from cardiopulmonary bypass. Suggested etiologies for right ventricular dysfunction after surgical repair include: myocardial ischemia due to inadequate protection during bypass; exacerbation of preexisting right ventricular hypertrophy and dilation due to chronic congenital heart defects; right ventriculotomy; pulmonary artery hypertension; and direct damage during surgical repair to the right ventricle or tricuspid valve apparatus.<sup>1</sup> We report a case of intramyocardial air identified intraoperatively by epicardial Doppler echocardiography (echo-Doppler) contributing to right ventricular dysfunction during congenital heart surgery in a child and suggest a management plan.

### CASE REPORT

A 6-yr-old, 19-kg child presented with a history of bacterial endocarditis and a large mitral valve vegetation associated with moderate to severe mitral regurgitation. She underwent left atrial exploration and excision of a left atrial thrombus because of the possibility of embolization and further deterioration of the valve. The patient had a history of *Staphylococcus aureus* osteomyelitis complicated by bacterial endocarditis that resulted in the mitral vegetation. Anesthetic management consisted of fentanyl 75 µg/kg, intermittent doses of pancuronium for neuromuscular blockade, and controlled ventilation. Monitoring consisted of seven-lead ECG, pulse oximetry, end-tidal CO<sub>2</sub>, esophageal and rectal temperatures, peripheral arterial catheter for continuous monitoring of blood pressure, and a right internal jugular venous catheter for central venous pressure measurement. Prebypass management was uneventful, and routine prebypass epicardial echocardiography showed normal right and left ventricular wall motion with systolic thickening in a short-axis view of the ventricles. A long-axis view demonstrated the presence of a left atrial thrombus attached to the mitral valve (fig. 1).

Cardiopulmonary bypass was instituted, and the patient was cooled to a nasopharyngeal temperature of 32° C. After hypothermic conditions were achieved, the aorta was cross-clamped; crystalloid cardioplegia was given; and the left atrium was opened. A large thrombus attached to the posterior leaflet of the mitral valve was visualized, as described by the epicardial echo-Doppler. The thrombus was surgically removed and the mitral valve carefully inspected. After the mitral valve was assessed by inspection to be normal, the left atrium was allowed to fill and the atriotomy closed. Venting procedures of the left atrium and ventricle were performed and consisted of chamber ballooning and placement of a needle vent hole in the ascending aorta. The aortic cross-clamp then was removed; total cross-clamp time was 8 min. The heart spontaneously resumed normal sinus rhythm and the patient was rewarmed to 36° C.

After the patient was rewarmed, separation from cardiopulmonary bypass was attempted. Aortic inflow was reduced and filling of the heart was accomplished by reduction of venous outflow from the right atrial cannula. During separation from cardiopulmonary bypass, right atrial pressure was noted to be high (12–15 mmHg) and mean systemic arterial pressure to be low (30–40 mmHg). Visual inspection of the

heart revealed a hypocontractile right ventricle. Four-millimeter ST-segment depression (leads II and AVF) was noted. Epicardial Doppler echocardiography was performed immediately in order to assess whether a residual structural defect, *i.e.*, a residual problem with the mitral valve, or an abnormality of ventricular function could account for the low-output syndrome. Epicardial echo-Doppler in the long-axis view showed that the entire vegetation was removed, and color flow mapping demonstrated no mitral regurgitation. In the short-axis view, however, a dense, echogenic area in the right ventricular free wall and intraventricular septum, and flattening of the septum toward the left ventricle, was noted (fig. 2). In addition, the right ventricle was noted to be dilated and poorly contractile, and the left ventricle underfilled when compared to the prebypass echo-Doppler study. No microbubbles were seen in the left ventricular cavity. Based on the echocardiogram, a diagnosis of intramyocardial air in the distribution of the right coronary artery was made. Subsequent visual examination of the coronary arteries by the surgeon revealed several very small air bubbles traversing the epicardial portion of the right coronary artery.

Cardiopulmonary bypass was reinstated, and the patient was reperfused for 10 min to allow ventricular ejection to occur. In addition, systemic blood pressure was increased with phenylephrine 50 µg. ST-segment depression was observed to resolve. On bypass after reperfusion, repeat epicardial echo-Doppler revealed decreased chamber size of the right ventricle, normal position of the interventricular septum, normal wall motion of the right ventricle, and disappearance of the echo-dense area in the right coronary artery distribution (fig. 3). The patient was subsequently separated from cardiopulmonary bypass without difficulty and without the use of inotropic support. Repeat epicardial echo-Doppler after bypass confirmed resolution of the problem. The remainder of the postoperative bypass period was unremarkable. The patient was taken to the postoperative intensive care unit in satisfactory condition and with no inotropic support. Postoperative follow-up revealed no neurologic sequelae.

### DISCUSSION

Right ventricular dysfunction and occasionally right ventricular failure have been reported after repair of congenital heart defects in children.<sup>2</sup> The occurrence of

FIG. 1. A prebypass epicardial echocardiogram in the long axis view, demonstrating the presence of a left atrial thrombus (arrow) attached to the mitral valve (MV). LV = left ventricle; RV = right ventricle.

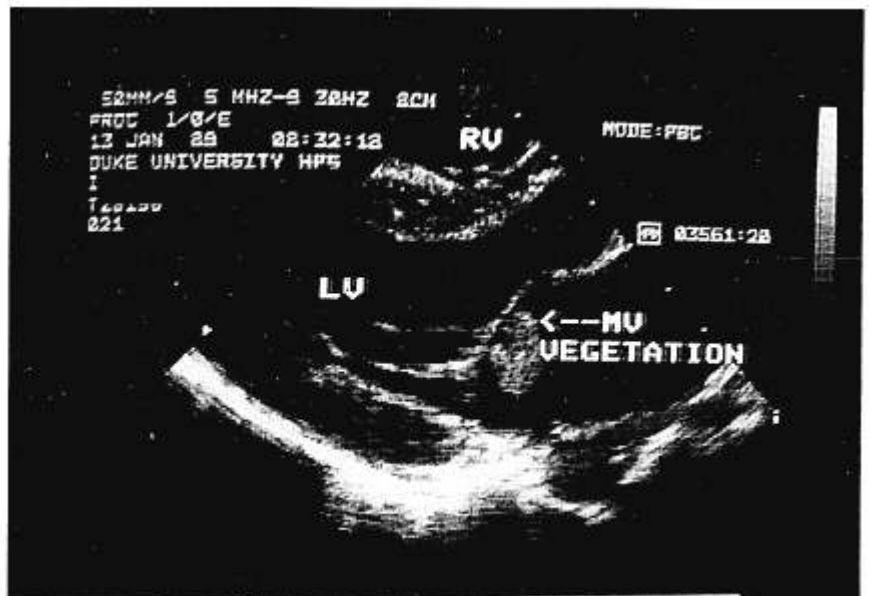

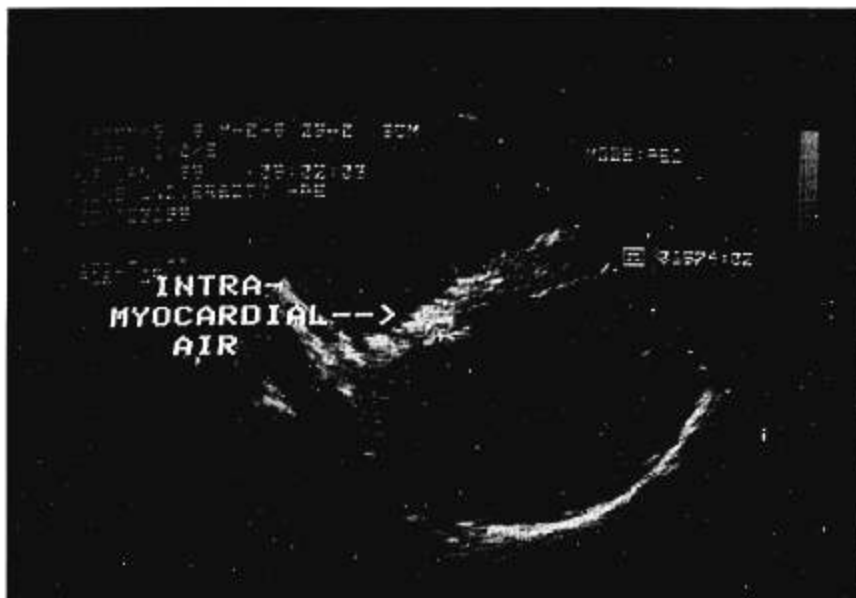


FIG. 2. A two-dimensional echocardiogram in the short axis view across the ventricles (left ventricle, lower cavity; right ventricle, upper cavity) demonstrating the presence of intramyocardial air (arrow) in the interventricular septum and right ventricular wall. The intramyocardial air appears as a dense "snowy" echogenic area. Note the associated wall-motion abnormality, appearing as a flattening of the interventricular septum.

right ventricular dysfunction and failure after cardiac surgery is more common in children than in adults.<sup>3</sup> Presumably, the higher incidence of right ventricular abnormalities and the preponderance of operations on the right ventricle associated with congenital heart defects account for the greater frequency in children. The manifestation of right ventricular dysfunction usually occurs during the process of separation from cardiopulmonary bypass and is noted clinically by high right atrial filling pressures, tachycardia, and low cardiac output syndrome. When it occurs, the presence of right ventricular dysfunction complicates separation from cardiopulmonary bypass.

In the current case report, we have identified intra-

myocardial air as another cause of right ventricular dysfunction during the process of separation from cardiopulmonary bypass. The echo-dense area on the echocardiogram in our patient was similar in appearance to the contrast intensity associated with microbubbles from the use of sonicated contrast to assess the effectiveness of myocardial revascularization after coronary bypass grafting.<sup>4,5</sup> Since sonicated contrast was not used, it could not account for the echo-dense area on echo-Doppler in our patient. Air bubbles visualized in the right epicardial coronary artery and ST segment changes on ECG provided collateral evidence that it was very likely intramyocardial air that was responsible for the echo-dense areas. On the

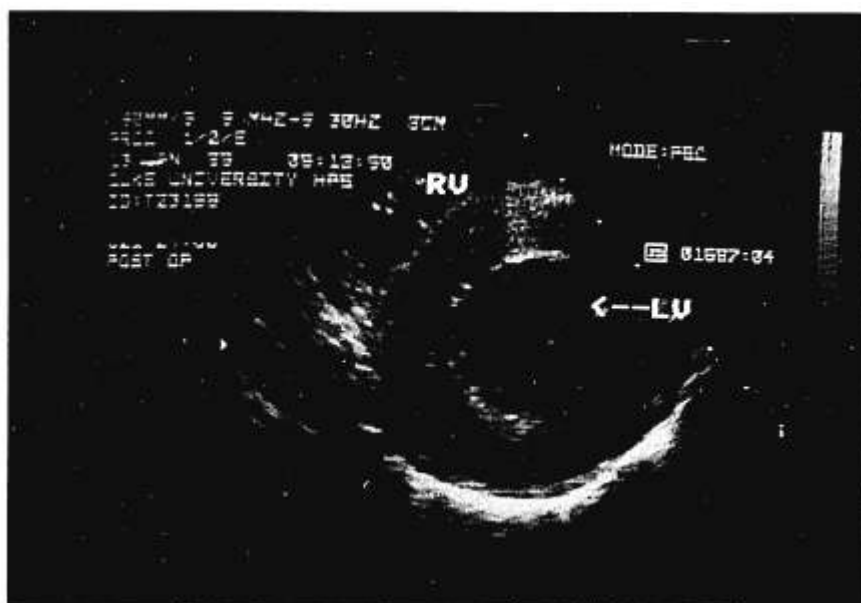


FIG. 3. A repeat epicardial echocardiogram after treatment with phenylephrine and reperfusion on bypass demonstrates decreased chamber size of the right ventricle, normal position of the interventricular septum, normal left ventricular configuration, and disappearance of the echo-dense area in the right coronary artery distribution. LV = left ventricle; RV = right ventricle.

echocardiogram, the intramyocardial air was located in the right ventricular free wall and along the inferior portion of the intraventricular septum. This location is the area supplied by the right coronary artery and suggests air embolization of this vessel. Because the ostium of the right coronary artery is located on the anterior aspect of the aorta, any air emerging from the left heart, where it may have accumulated during opening of the left side of the heart, is more likely to embolize to this artery. In this patient, the left heart was directly entered during repair. It is important to note that intramyocardial air occurred despite the usual de-airing procedures prior to ventricular ejection.

The incidence of coronary air embolus and intramyocardial air after cardiac surgery is not known. Justice *et al.*<sup>6</sup> was the first to report the occurrence of coronary air embolism after coronary artery bypass grafting. In a more recent study examining the complications of cardiopulmonary bypass, Thomas<sup>7</sup> reported air embolism to be a common problem, but did not mention the specific occurrence of coronary artery embolism and intramyocardial air as a complication. A recent study examining the fate of retained intracavitary air after cardiopulmonary bypass as determined by transesophageal echo-Doppler demonstrated the high occurrence of intraventricular air in patients having valve operations.<sup>8</sup> Of relevance in this study was the detection of intraaortic air in a small number of patients and the detection of a right coronary air embolism in one patient. Another report examining the same problem demonstrated the high incidence of retained intracavitary air, but did not address the question of whether air embolized to the coronary arteries.<sup>9</sup> None of these studies reports the occurrence of intramyocardial air after congenital heart surgery.

In our previously reported intraoperative echo-Doppler series,<sup>10</sup> pre- and postbypass echo-Doppler examinations were performed in 350 consecutive patients undergoing repair of congenital heart defects through a median sternotomy. A review of this series, prompted specifically by this current case report, revealed that there were 14 patients (4%) with intramyocardial air after separation from cardiopulmonary bypass. Eleven of these cases were associated with either right ventricular or septal wall motion abnormalities consisting of dyskinesia or absence of systolic thickening, and occasionally were associated with increased right ventricular chamber size with interventricular septal bulging into the left ventricle as determined by echo-Doppler. Five of these patients had associated hemodynamic instability clinically noted during the separation from bypass. The location of the echogenic areas was consistently in the right ventricular free wall and along the inferior portion of the interventricular septum, similar to the findings in the current case report.

Right ventricular wall motion abnormality and dysfunction were observed in our patient and presumably

were due to ischemia. The importance of the right coronary artery as a source of right ventricular ischemia and dysfunction has been reported by several groups.<sup>11,¶</sup> Rhodes and McIntosh\*\* demonstrated experimentally that coronary air emboli cause redistribution of blood flow away from the subendocardium, thereby causing decreased ventricular function. Stegman *et al.*<sup>12</sup> also examined the pathophysiology of intracoronary air emboli experimentally and showed the time course leading to myocardial ischemia to include ST-segment abnormalities, arrhythmias, wall motion abnormalities, and cardiac failure. In our echo-Doppler series,<sup>10</sup> only 5 of 14 patients (36%) with intramyocardial air had hemodynamic instability after separation from cardiopulmonary bypass, as identified by clinical observation and routine operative monitoring. This finding suggests that when echo-Doppler is not routinely performed, the occurrence of intramyocardial air usually goes clinically undetected because it does not cause hemodynamic instability in the majority of cases. Thus, most cases of intramyocardial air produce transient effects and more importantly, have no clinical significance.

Recently, Bell *et al.*<sup>13</sup> reported ST-segment changes as a complication of repair of congenital heart disease. In this report the authors attribute the ST-segment changes to myocardial ischemia. Our case report identifies intracoronary artery air as a potential cause of myocardial ischemia and of the ST-segment changes observed by other groups. Furthermore, the transient findings associated with intramyocardial air suggest that the acute deterioration occasionally seen in the immediate postoperative period may in some cases be secondary to residual intracavitary or intraaortic air embolizing to the right coronary bed.

In our patient, hemodynamic instability was associated with intramyocardial air, and management was directed at reperfusing the coronary arteries. Cardiopulmonary bypass was reinstated at high flow rates (100–150 ml · kg<sup>-1</sup> · min<sup>-1</sup>), and phenylephrine was administered to increase mean arterial pressure and to enhance right ventricular perfusion pressure. The efficacy of this treatment approach has previously been suggested experimentally.<sup>14</sup> Reperfusion for 10 min at increased perfusion pressures was performed. Thereafter, the repeat echo-Doppler evaluation revealed resolution of the air and return to normal of right ventricular function and septal wall motion. The patient was then successfully separated from cardiopulmonary bypass. We believe that without the use of echo-Doppler, this patient would have been treated nonspecifically, with inotropic support and volume load-

¶ Hines R, Biondi J, Barash P: The right ventricle: Master or servant? ANESTHESIOLOGY 61:A8, 1984

\*\* Rhodes GR, McIntosh CL: An experimental evolution of coronary air embolism. Surgical Forum 17:275–278, 1976.

ing, and would have experienced a more gradual return to normal of right ventricular function.

Echo-Doppler has been demonstrated to be helpful in assessing problems associated with difficulty in separating from cardiopulmonary bypass.<sup>15-17</sup> The routine use of echo-Doppler allows the anesthesiologist and surgeon to identify structural problems requiring immediate rerepair and to identify myocardial dysfunction requiring specific therapeutic support. The current report provides additional evidence for the diagnostic and therapeutic usefulness of this monitoring technique in the management of congenital heart disease.

In conclusion, we have identified intramyocardial air as another cause of right ventricular dysfunction occurring after surgical repair of congenital heart defects and as an event that may be associated with difficulty separating from CPB. The occurrence of intramyocardial air and right ventricular dysfunction are transient and produce no long-term impairment when efficiently recognized and appropriately treated. The role of echo-Doppler is helpful in identifying the problem and in guiding therapy in patients with hemodynamic instability. Further, we demonstrate in this report a successful management plan for intramyocardial air.

#### REFERENCES

- Hines R, Barash PG: Right ventricular failure, *Cardiac Anesthesia*. Edited by Kaplan JA. New York, Grune & Stratton, 1987, pp 995-1020
- Graham TP: Ventricular performance in adults after operation for congenital heart disease. *Am J Cardiol* 50:612-620, 1982
- Serra J, McNicholas KW, Moore R, Lemole GM: High-frequency, high-volume ventilation for right ventricular assist. *Chest* 93:1035-1037, 1988
- Kabas JS, Kisslo J, Flick CL, Johnson SH, Craig DM, Stanley TE, Smith PK: Intraoperative perfusion contrast echocardiography: A method to evaluate the effectiveness of coronary artery bypass grafting. *J Thorac Cardiovasc Surg* 1990, in press
- Aronson S, Bender E, Feinstein SB, Heidenreich PH, Ellis J, Dick C, Roizen MF, Karp RB: Contrast echocardiography: A method to visualize changes in regional myocardial perfusion in the dog model of CABG surgery. *ANESTHESIOLOGY* 72:295-301, 1990
- Justice C, Leach J, Edwards WS: The harmful effects and treatment of coronary air embolism during open-heart surgery. *Ann Thorac Surg* 14:47-53, 1972
- Thomas CS: Air embolism and other accidents using pump oxygenators. *Ann Thorac Surg* 29:336-340, 1980
- Oka Y, Inoue T, Hong Y, Sisto DA, Strom JA, Frater RW: Retained intracardiac air: Transesophageal echocardiography for definition of incidence and monitoring removal by improved techniques. *J Thorac Cardiovasc Surg* 91:329-338, 1986
- Rodigas PC, Meyer FJ, Haasler GB, Dubroff JM, Sponitz HM: Intraoperative two-dimensional echocardiography: Ejection of microbubbles from the left ventricle after cardiac surgery. *Am J Cardiol* 50:1130-1132, 1982
- Ungerleider RM, Greeley WJ, Sheikh KH, Philips JL, Pearce FB, Kern FH, Sabiston DC, Kisslo JA: Routine use of intraoperative, epicardial echo and Doppler color flow imaging to guide and evaluate repair of congenital heart lesions: A prospective study. *J Thorac Cardiovasc Surg* 1990, accepted for publication
- Crosby TW, Shaffer P, Baslioni TW: Non-dominant right coronary artery disease: A source of right ventricular infarction, anginal pain and a positive exercise electrocardiogram. *Chest* 84:101-104, 1983
- Stegman T, Daniel W, Bellman L, Trenkler G, Oeler TH, Borst HG: Experimental coronary air embolism: Assessment of time course of myocardial ischemia and the protective effect of cardiopulmonary bypass. *J Thorac Cardiovasc Surg* 28:141-148, 1980
- Bell C, Rimar S, Barash P: Intraoperative ST-segment changes consistent with myocardial ischemia in the neonate: A report of three cases. *ANESTHESIOLOGY* 71:601-604, 1989
- Vlahakes GJ, Turley K, Hoffman JIE: The pathophysiology of failure in acute right ventricular hypertension: Hemodynamic and biochemical correlations. *Circulation* 63:87, 1980
- Ungerleider RM, Kisslo JA, Greeley WJ, Van Tright P, Sabiston DC, Jr.: Intraoperative pre- and postbypass epicardial color flow imaging in the repair of atrioventricular septal defects. *J Thorac Cardiovasc Surg* 98:90-100, 1989
- Gusshoven EJ, van Herwerden LA, Roelandt J, Ligtvoet KM, Bos E, Witsenburg I: Intraoperative two-dimensional echocardiography in congenital heart disease. *J Am Cardiol* 9:565-572, 1987
- Ungerleider RM, Greeley WJ, Sheikh KH, Kern FH, Kisslo JA, Sabiston DC, Jr.: The use of intraoperative echo with Doppler color flow imaging to predict outcomes following repair of congenital cardiac defects. *Ann Surg* 210:526-534, 1989