

Anesthesiology  
73:1053, 1990

### Making Oral Midazolam Palatable for Children

*To the Editor:*—The elusive goal of finding the perfect preanesthetic medication for young children continues. Recently we have been administering midazolam orally as recommended by others.<sup>1\*</sup> Our initial problems with its bad taste have finally been overcome. After testing serpalta syrup, apple juice, and various carbonated beverages, our day surgery nurses finally came up with a palatable solution: a 2-quart package of grape Koolaid® soft drink mix (Nutrasweet® variety) is mixed in only 2 cups of water. The concentrated midazolam (5 mg/ml) at 0.5 mg/kg is then mixed with 5–10 ml of the concentrated grape drink, which we keep prepared in the refrigerator. This formulation takes the bitterness out of the parenteral preparation and has been accepted easily by the fasted child. We have enjoyed success with this preparation when given 10–15 min prior to the start of induction. The effect of the drug will wear off within 1 h if there is a delay in the surgery schedule.

The number of inductions with crying children has been almost eliminated with this preparation.

\* Berry FA: Challenges in pediatric anesthesia, Review Course Lectures, volume 4. International Anesthesia Research Society, 1990, pp 1–5

Anesthesiology  
73:1053, 1990

### Proper Technique for Insertion of the Laryngeal Mask

*To the Editor:*—While I am grateful to Grebenik *et al.*<sup>1</sup> for introducing American anesthesiologists to the laryngeal mask,\* which is not yet available in the United States, some of their statements and illustrations are misleading and need correction to avoid confusing your readers.

The correct insertion technique involves deflation of the mask to a greater degree than is shown in their figure 1; lubricant must be applied only to the dorsal surface of the mask in order to avoid accidental aspiration of lubricant; and although insertion is performed without a laryngoscope, the anesthesiologist should look into the oral cavity to ensure correct positioning of the mask tip, which must be flattened against the hard palate before it is slid downward into position. If this is not done, the mask tip may roll over as it is advanced, causing obstruction, uvular or pharyngeal trauma,<sup>2</sup> or incorrect positioning of the device.

In addition, figure 3 is misleading, because the mask is being inserted in the inflated state and the hand position is incorrect. Smooth insertion requires the index finger to be positioned at the junction of the tube and the mask. This finger propels the device into place, avoiding collision with the epiglottis by pressing backward against the posterior pharyngeal wall as well as downward (fig. 1).

Lastly, the size of the laryngeal mask as shown by Grebenik *et al.* is too small relative to the size of the pharynx, and the epiglottis normally sits within and not above the mask, as shown in their figure 3.

In fairness to the authors, the Instruction Manual and video that I have prepared for users of the laryngeal mask were not available at the time their study was performed.

ARCHIE BRAIN, M.A., L.M.S.S.A., F.F.A.R.C.S.I.  
Honorary Consultant Anaesthesiologist  
Northwick Park Hospital  
Harrow, Middlesex

\* Alexander C, Leach D: The laryngeal mask: Experience of its use in a District General Hospital. *Today's Anaesthetist* 4,5:200–205, 1989

MARY D. PETERSON, M.D.

Director

Anesthesiology Associates

Driscoll Foundation Children's Hospital

3533 South Alameda

Corpus Christi, Texas

Assistant Professor

Department of Anesthesiology

The University of Texas

Medical Branch at Galveston

Galveston, Texas

#### REFERENCE

1. Feld LH, Negus JB, White PF: Oral midazolam preanesthetic medication in pediatric outpatients. *ANESTHESIOLOGY* 73:831–834, 1990

(Accepted for publication July 10, 1990.)

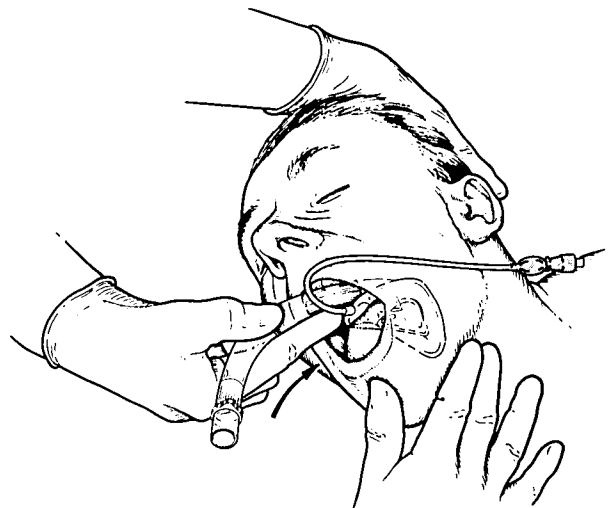


FIG. 1. Method of insertion of laryngeal mask.

Honorary Research Fellow in Anaesthesiology  
Royal National Throat, Nose, and Ear Hospital  
330/332 Gray's Inn Road  
London WC1X 8EE  
United Kingdom

#### REFERENCES

1. Grebenik CR, Ferguson, C, White A: The laryngeal mask airway in pediatric radiotherapy. *ANESTHESIOLOGY* 72:474–477, 1990
2. Lee JJ, Brain AJ: Laryngeal mask and trauma to the uvula (letter). *Anaesthesia* 44:1014–1015, 1989

(Accepted for publication August 1, 1990.)