

not iv sedation. Furthermore, the data provided do not warrant the conclusion that this technique is more efficacious or safe when used in an infant whose lungs are already being ventilated preoperatively.

ALAN S. KLEIN, M.D.
Assistant Professor
Anesthesiology and Pediatrics

ERIC KUNICHKA, M.D.
Assistant Professor
Anesthesiology and Pediatrics

Anesthesiology
73:1056, 1990

In Reply:—Although we cannot absolutely contend that the doses of ketamine and midazolam that our patient¹ received produced "sedation" rather than "anesthesia," our major objective in managing this particular anesthetic was not to lay the groundwork for an argument in semantics, but to produce as little physiologic trespass as possible in a fragile patient with an urgent underlying surgical condition. Although studies have shown that younger children require more ketamine on a per-kilogram basis than do older children or adults to prevent movement in response to surgical stimulation,² we are not sure that anyone has determined what constitutes an "anesthetizing" dose of ketamine in a 1,500-g infant. Preoperatively, this patient had been receiving intravenous diazepam 0.3 mg · kg⁻¹ every 4 h supplemented with intravenous fentanyl 2 μg · kg⁻¹ for control of episodes of intense agitation.

In selecting the doses of ketamine and midazolam used in this case, our underlying concern was to prevent this patient from experiencing intraoperative hypoxemia and hypercarbia secondary to agitation in response to both surgical and nonsurgical stimuli. This patient never ceased breathing spontaneously during the surgical procedure. Separation from mechanical ventilation, which had begun preoperatively, continued rapidly in the postoperative period.

In conclusion, we believe that in this particular case, we met our goals of providing excellent surgical anesthesia without worsening the course of our patient's underlying pulmonary disease. However, com-

Anesthesiology
73:1056-1057, 1990

Collecting Blood for Autologous Transfusion

To the Editor:—Isovolemic hemodilution—the exchange of whole blood with colloid or crystalloid to obtain autologous whole blood for retransfusion while maintaining normovolemia—has recently regained favor as a technique to minimize exposure to homologous blood products.*† Unfamiliarity with the technique may be a barrier to its use.

Inserting a 14- or 16-G venous catheter, connected to a collecting bag, and waiting for the blood to collect can be a frustrating experience. Collecting blood from a 20-G arterial or central venous catheter is an

University of Florida College of Medicine
Box J-254
J. Hillis Miller Health Center
Gainesville, Florida 32610-0254

REFERENCES

1. Furman JR, Smith MD: Caudal anesthesia and intravenous sedation for repair of giant bilateral inguinal hernias in a ventilator-dependent premature infant. *ANESTHESIOLOGY* 72:573-575, 1990
2. Reich DL, Silvey G: Ketamine: an update on the first twenty-five years of clinical experience. *Can J Anaesth* 36:186-197, 1989

(Accepted for publication September 5, 1990.)

parisons of safety and efficacy of different anesthetic techniques require more than one case report to demonstrate the universal superiority of any particular anesthetic technique.

JOSEPH R. FURMAN, M.D.
Clinical Assistant Professor of Anesthesiology

MELVIN D. SMITH, M.D.
Clinical Associate Professor of Surgery

The University of Texas Health Science Center
San Antonio, Texas 78284-7834

REFERENCES

1. Furman JR, Smith MD: Caudal anesthesia and intravenous sedation for repair of giant bilateral inguinal hernias in a ventilator-dependent premature infant. *ANESTHESIOLOGY* 72:573-575, 1990
2. Lockhart CH, Nelson WL: The relationship of ketamine requirement to age in pediatric patients. *ANESTHESIOLOGY* 40:507-508, 1974

(Accepted for publication September 5, 1990.)

alternate method but requires invasive cannulation. All of these methods can lead to a costly error, since slowly collected blood can clot in the collecting tubing and bag.

We use the Fenwall autologous blood collection kit (two 500-ml bags with 63 ml anticoagulant, citrate-phosphate-dextrose) and place an automatic blood pressure cuff on the same arm in which a venous catheter has been inserted into a vein in the forearm or antecubital area. By cycling the cuff at 3-min intervals, pressure is generated in the vein, and blood collection is facilitated. This technique may be analogous to the squeezing and releasing of the hand around a sponge ball that is used in awake blood donation. It is necessary to frequently shake the collection bag to ensure adequate mixing with the citrate-phosphate-dextrose. This further prevents clotting.

We use the method described by Bourke and Smith¹ to estimate allowable hemodilution. This volume is replaced with a crystalloid or

* Orr M: Autologous transfusion. *Journal of Cardiothoracic Anesthesia*. 11:7-12, 1988

† Kaplan JK: Summary. *Journal of Cardiothoracic Anesthesia*. 11: 50-51, 1988

colloid, and the autologous whole blood is reinfused within 4–6 h of its collection.

We encourage the use of this technique as well as autologous pre-donation of blood to decrease the surgical patient's exposure to the risk of homologous blood products.

DON HAN, M.D.
Liver Transplant Fellow

MEG ROSENBLATT, M.D.
Assistant Professor

Anesthesiology
73:1057, 1990

Bloodless Turbinectomy Following Blind Nasal Intubation: Faulty Technique?

To the Editor:—Cooper¹ reported "middle turbinectomy" following nasal intubation. Anesthesiologists should be aware that this is a rare but unacceptable complication of nasal intubation.

With correct technique of nasal intubation, the middle turbinate should never be contacted by an endotracheal tube. It should pass between the inferior turbinate and the floor of the nasal cavity, where there is maximum area to accommodate it.

When an endotracheal tube is being inserted through the nostril's opening, its bevel should be directed laterally so as to direct its leading edge away from the superior, middle, and inferior turbinates. Then before it is advanced, it should be pulled cephalad (fig. 1). Doing so directs its bevel so that it is advanced along the floor of the nasal cavity and below the inferior turbinate. When it is judged that the tip of the tube has passed the uvula, the exposed part of the endotracheal tube, which has not passed the nostril, is returned to its normal curvature. Then the tube is advanced toward the larynx.

DANIEL C. MOORE, M.D.
*Department of Anesthesiology
The Mason Clinic
1100 Ninth Avenue
P.O. Box 900
Seattle, Washington 98111*

Anesthesiology
73:1057, 1990

In Reply:—I wish to thank Dr. Moore for his comments concerning my Letter to the Editor.¹ His description of nasal intubation, in particular the pulling of the endotracheal tube cephalad before it is advanced along the floor of the nasal cavity, when correctly followed should avoid trauma to the turbinates in the majority of cases.

When an endotracheal tube has been softened by prewarming, the advantage gained by a cephalad pull can be reduced, since this pull depends on the fulcrum effect of the nostril against a relatively firm endotracheal tube.

I must emphasize that the main point of my letter was to urge vigilance after cocaine paste has been applied to the nasal mucosa as described by Pearman,² since absence of bleeding even with a proper technique of nasal intubation does not preclude severe nasopharyngeal trauma and the entry of foreign material into the airway.

*Department of Anesthesiology
Box 1010
The Mount Sinai Medical Center
1 Gustave L. Levy Place
New York, New York 10029-6574*

REFERENCE

1. Bourke DL, Smith TC: Estimating allowable hemodilution. *ANESTHESIOLOGY* 41:609–612, 1974

(Accepted for publication September 5, 1990.)

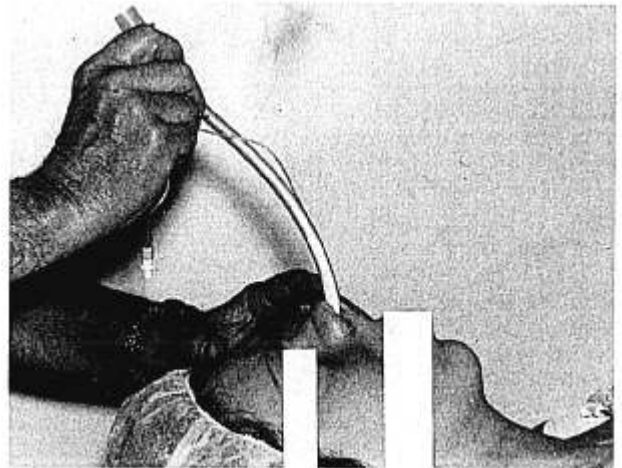


FIG. 1. Nasal tracheal intubation showing cephalad traction being placed upon the tube as the tip is advanced along the floor of the nasal cavity.

REFERENCE

1. Cooper R: Bloodless turbinectomy following blind nasal intubation (letter). *ANESTHESIOLOGY* 71:469, 1989

(Accepted for publication September 5, 1990.)

RON COOPER, M.B., F.F.A.R.C.S.I.
*23 William Street
Donaghadee, Co. Down
Northern Ireland BT21 OHL*

REFERENCES

1. Cooper R: Bloodless turbinectomy following blind nasal intubation. *ANESTHESIOLOGY* 71:469, 1989
2. Pearman K: Cocaine: A review. *J Laryngol Otol* 93:1191–1199, 1979

(Accepted for publication September 5, 1990.)